

# Integration of a Maxillary all Ceramic Fixed Partial Denture with Zirconia Framework: A Clinical Report

Mohamed Chebil<sup>2\*</sup>, Saida Ziada<sup>3\*\*</sup>, Amani Adli<sup>1\*</sup>, Moncef Omezine<sup>4\*</sup>, Mounir Cherif<sup>5\*</sup>

<sup>1</sup>Associate Professor, Department of Fixed Prosthodontics, Dental Clinic of Monastir, Tunisia

<sup>2</sup>Assistant Professor, Department of Conservative Dentistry and Endodontics, Dental Clinic of Monastir, Tunisia

<sup>3</sup>DDS, Department of Fixed Prosthodontics, Dental Clinic of Monastir, Tunisia

<sup>4</sup>Professor, Department of Fixed Prosthodontics, Dental Clinic of Monastir, Tunisia

<sup>5</sup>Professor Head of Department; Department of Fixed Prosthodontics, Dental Clinic of Monastir, Tunisia

**Abstract:** *The integration of a maxillary all-ceramic fixed partial denture (FPD) is esthetically, functionally and periodontally demanding. It requires careful study, correct diagnosis, appropriate decision and impeccable implementation. We report the case of a patient claiming the replacement of a defective metal-ceramic FPD replacing the maxillary first premolar (24) and supported by the canine (23) and second premolar (25). The problems found were a reduced prosthetic occlusal height (POH) due to hypertrophy of the edentulous ridge, a reduced coronal height and a poorly aligned free gingival margins. The decision was to make a new all-ceramic FPD with zirconia framework. Corrective surgery of the edentulous ridge was performed in the preprosthetic phase. Tissue healing was guided by a transitional prosthesis. A period of 6 months was required for the final maturation. The choice of the material as well as the prosthetic design made it possible to make a compromise between the biological, aesthetic and mechanical requirements.*

**Keywords:** integration, all ceramic, zirconia, preprosthetic surgery, edentulous ridge

## 1. Introduction

In the maxillary canine and premolar sector, integration of an all-ceramic FPD is essentially an aesthetic and functional challenge, but also a periodontal one.

In fact, this area is always visible when smiling. Functionally, it plays an important role in guiding the mandible. Indeed, in the concept of canine function, this area supports the mandible during its lateral movements and is solicited by oblique forces much less tolerated by the tooth periodontium unit than the axial one [1]. On another side, we have a heterogeneous tooth periodontium environment due to the differences between the coronal height, the free gingival margin and the periodontium. This requires special attention to achieve the periodontal and aesthetic integration. All these data imply the delicacy of prosthetic integration in the maxillary canine and premolar sector. The role of the dentist is to use all means for an optimal prosthetic integration into the oral cavity, a truly complicated biological environment.

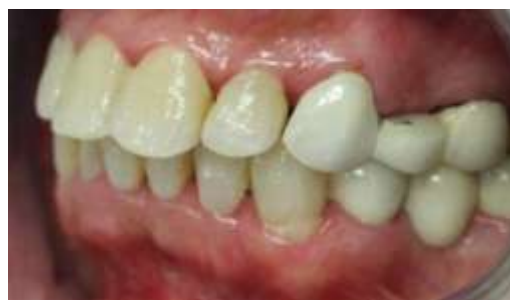In this article, we report the case of a patient for whom we decided to make a new all-ceramic FPD to replace an old defective metal-ceramic restoration. The main goal was to explain the approach taken to succeed the aesthetic, periodontal and functional integration of the new all-ceramic restoration.

## 2. Case Report

A 55-year-old female patient consulted the department of prosthodontics complaining of a defective metal-ceramic

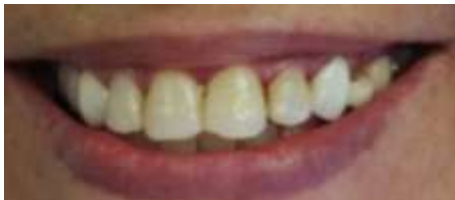FPD, replacing the maxillary first premolar (24) and supported by the canine (23) and second premolar (25). The questioning revealed the patient's dissatisfaction because of the unsightly appearance of the restoration. The clinical examination revealed an adequate oral hygiene, a favorable periodontal condition except a gingival inflammation around the old restoration. The latter had several defects. First, it had a fracture of the pontic at the level of its vestibular surface revealing a small metallic area. Then, the gingival embrasures around the pontic were insufficient. The pontic was unhygienic because of a wide contact area with the edentulous ridge.

The retainer on the 25 had a short coronal height and a poor marginal fit. A mal-aligned free gingival margin, an unsatisfactory morphology and a sharp color contrast were notably recorded (Fig.1).



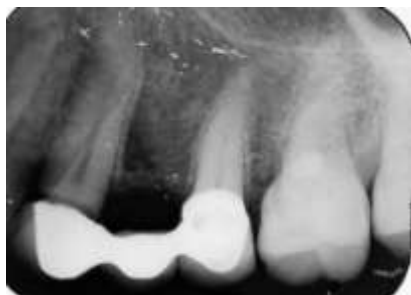**Figure 1:** Vestibular view of the old bridge. Note the cervical grayish brown colour at the mesial side of the tooth 25

Examination of the occlusion showed normal functions with an efficient anterior guide. The antagonist teeth were rehabilitated by a satisfactory metal-ceramic restoration. Natural teeth were of low translucency. The smile examination showed a broad smile revealing the maxillary teeth to the mesial faces of the first molars. The patient had a medium smile line (Fig.2).



**Figure 2:** Examination of forced smile

Periapical radiograph showed a crown to root ratio less than 1 at the level of the abutment teeth and a bone trabeculae rarefaction in edentulous ridge zone was noted (Fig.3).



**Figure 3:** Periapical radiograph in the area of the bridge. Note the poor adaptation of the dento-prosthetic joint and the absence of the interproximal contacts.

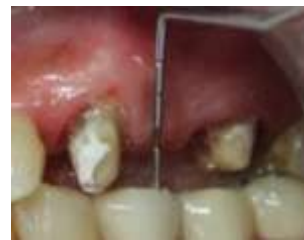The space between the gingival surface of the pontic and the residual ridge crest was measured. This space, occupied by the soft tissues, was exaggerated (about 5 mm). A provisional diagnosis of a gingival hypertrophy was retained. Moreover, a small height of the pontic metallic core was noted (Fig.3). This could be at the origin of the fracture of the fragile cosmetic ceramics by the lack of support [2]. After getting informed consent from the patient, the fixed partial denture was removed successfully without destruction. A well opened prosthetic embrasures on either side of the pontic (Fig.4) and a reduced cross sectional area of the connectors were observed.



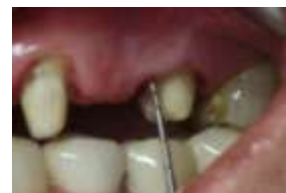**Figure 4:** Removed defective restoration: Note the irregularity of the cervical margins as well as the excess cement adhering to the gingival face of the pontic

This was explained by the insufficient prosthetic occlusal height. Indeed, its clinical measurement showed an unfavorable situation (Fig. 5). Teeth abutment examination showed a short coronal height of tooth 25 with a free

gingival margin more occlusal than that of the adjacent molar (Fig.6).

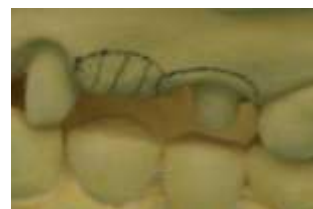

**Figure 5:** The prosthetic occlusal height quantified by a periodontal probe was less than 5 mm.

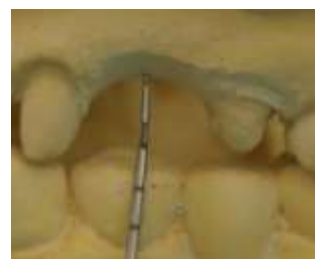

**Figure 6:** Tooth 25 had a short coronal height. Its free gingival margin was more occlusal than tooth 26.

A cleaning and gingival curettage of the abutment teeth were accomplished. Then, a diagnostic impression was performed. The mounted diagnostic cast was used to simulate our prosthetic project. Simulation began with tracing of new tissue limits presumed after the surgery (Figure 7). This simulation aimed to ameliorate the POH, to elongate the crown of tooth 25 and to align the buccal free gingival margin with that of tooth 26. Subsequently, a diagnostic cast scraping was performed, which made it possible to appreciate the quantity of the tissues to be resected during the surgery (Fig.8).

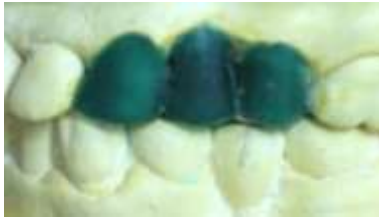

**Figure 7:** Initial situation on mounted diagnostic models and tracing of new limits expected after the surgery.



**Figure 8:** After scraping on plaster, the new POH was measured to 7 mm.

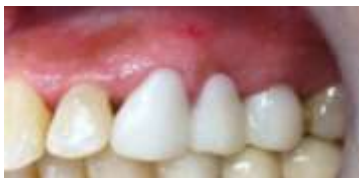A diagnostic waxing was made to simulate the prosthetic project (Fig.9).



**Figure 9:** Diagnostic waxing of a three-unit fixed prosthesis to replace the maxillary first premolar.

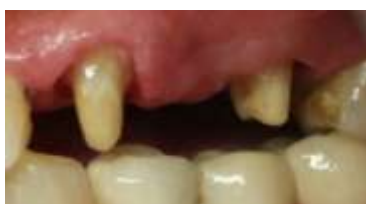A custom external surface form was performed with silicone polymer and used to transfer our prosthetic project into the mouth by means of a provisional restoration.

The temporary prosthesis was achieved with a compromise between the esthetic, biological and mechanical requirements (Fig.10). Indeed, the modified ridge lap pontic allowed restoring esthetics by its adaptation to the facial aspect of the residual ridge. However, this vestibular part was thin due to a reduced POH. This means a low resistance to fracture. Another compromise was sought for the connectors in order to improve mechanical strength and at the same time to have easy hygiene. In addition, a well-polished surface was the rule.



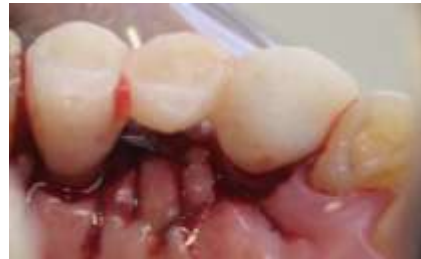**Figure 10:** Vestibular view of the transitional prosthesis: a compromise was sought between the various imperatives.

After provisional luting, the excess cement is removed from around the margins. Then, oral hygiene instructions were given to the patient, especially in relation with the provisional restoration area. At an appointment, a few days later, the periodontium status was reevaluated. We noted a considerable regression of inflammation (Fig.11).

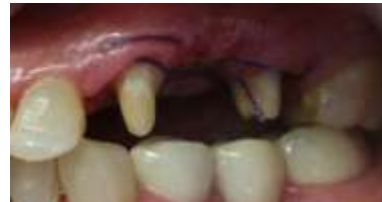

**Figure 11:** Note the regression of clinical inflammation with, however, the persistence of gingival hyperplasia of the edentulous ridge as well as a pseudopocket around the tooth 25

In a subsequent session, the surgical phase was initiated. The edentulous ridge was reshaped by oral mucosa thinning. In addition, a surgical crown lengthening was performed at the level of the maxillary second premolar (25) (Fig. 12, 13).

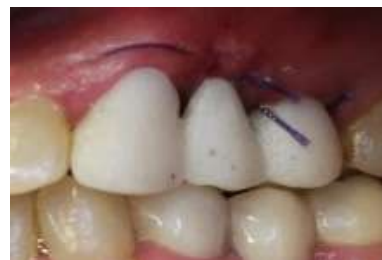

**Figure 12:** Note the new supra mucosal situation of the pontic after remodeling of the edentulous ridge



**Figure 13:** Buccal view: note the increase in the POH and a lengthened clinical crown of tooth 25

Hermetic stitches were performed and instructions were given to the patient to avoid all factors disturbing hemostasis. Afterwards, the cervical margins of the retainers and the gingival surface of the pontic were lined with autopolymerizing resin. Careful polishing was the rule and then the provisional restoration was cemented. Special care should be given to eliminate cement excess to avoid gingival irritation (Fig. 14).

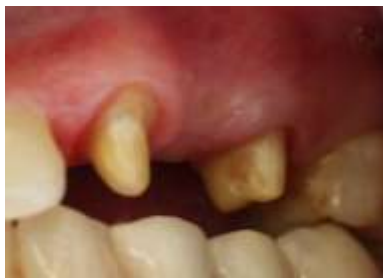

**Figure 14:** Vestibular view of the lined transitional prosthesis. Note its adaptation to the new situation of the soft tissues with open embrasures.

During a follow-up visit, 4 days later, we examined both the periodontal tissues and the provisional FPD that will guide the tissue healing. We insisted on the well-opened embrasures, made possible by the increase of the POH resulting from the surgery (Fig.14). The sutures were removed on the 10th day of surgery. After about 3 weeks, the preparations were rectified, and then a non-compressive global impression was achieved and sent to the laboratory to produce a transitional prosthesis made in thermoplastic resin. This resulted in tissue maturation under the best conditions.

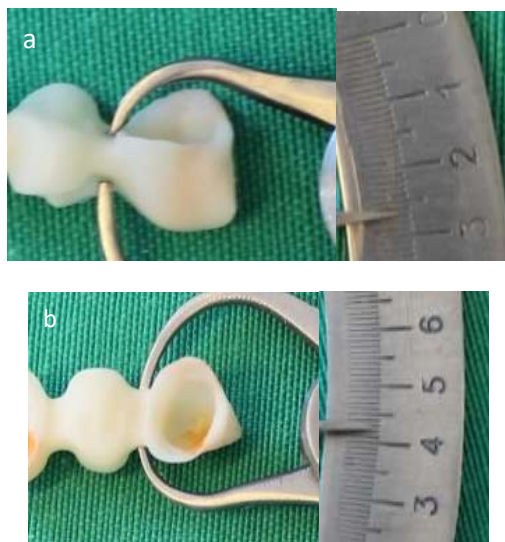
Six months were considered sufficient to achieve final tissue maturation [3](Fig.15).





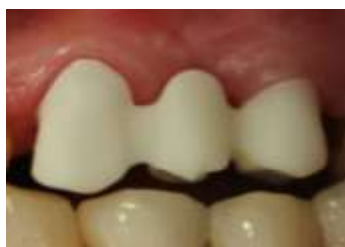**Figure 15:** Buccal view: Note the soft tissue maturation

Consequently, a non-compressive global impression was performed by double mix impression technique. Then, the color of the ceramic framework was chosen. A 3-unit zirconia framework (Y-TZP) was fabricated by Indirect CAD-CAM technology (Computer Aided Design-Computer Aided Manufacturing). Then, we checked the design of the framework. We particularly examined, the connectors. We found them sufficiently high, with a cross-sectional area calculated at the mesial connector equal to 8.73 mm<sup>2</sup> and slightly higher at the distal one (Fig.16).



**Figure 16:** Dimensions of the mesial connector: height = 2.7 mm (a) and width = 4.2 mm (b)

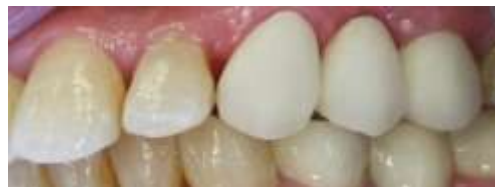In addition, the radius of the gingival side of the connectors was found to be largely sufficient to resist to tension forces. The problem of bonding between the zirconia framework and the ceramic veneer, fragile by nature, led us to recommend a framework design ensuring, by its volume, the maximum support for ceramic veneer, especially at the level of the canine-retainer which is the most exposed to lateral forces (Fig.17).



**Figure 17:** Buccal view of the framework .Note, sufficiently high connectors and space devoted to cosmetic ceramics

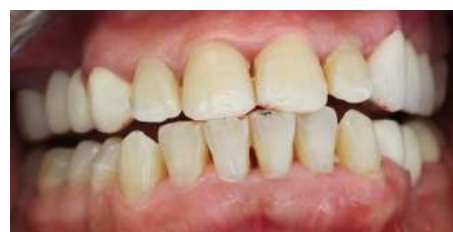In the mouth, we checked the non frictional fit of the zirconia framework with low viscosity silicone. In addition, marginal adaptation was assessed and proved satisfactory. Finally, we chose the ceramic veneer color.

After ceramic application, a try-in appointment in the biscuit bakewas achieved. We particularly checked the opening of the embrasures, as well as the pontic/tissue relationship. Imperfections in morphology and color were detected (Fig.18) and required corrections in the laboratory.

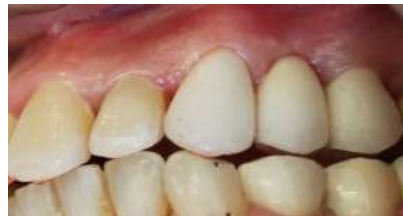

**Figure 18:** Note the difference in color and the overhangs

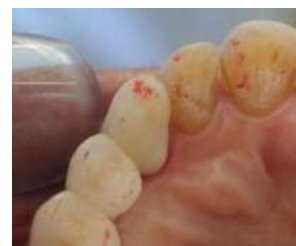During the next visit, special attention was paid to the static and dynamic occlusal equilibration. In right lateral movement, the contacts were distributed harmoniously according to the canine function concept<sup>1</sup> (Fig. 19 to 21).



**Figure 19:** Functional anterior guidance



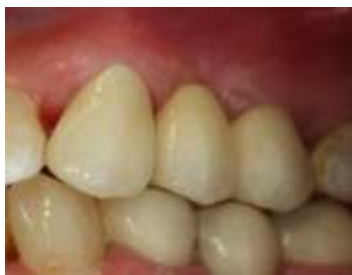**Figure 20:** Right laterality showing canine guidance with incisive involvement



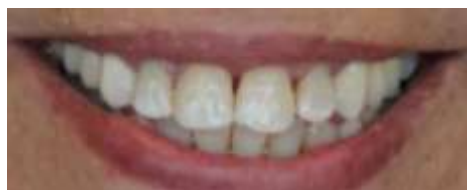**Figure 21:** Contacts found at lateral movement

Obtaining a color and a surface state similar to natural teeth is an essential element for a perfect prosthetic integration. To reach this, staining and glazing bakewas carried out in the dental laboratory in the patient's presence. That made it possible to add more saturated color shades to the cervical zone and to characterize the surface condition.

Finally, the FPD was cemented with resin-modified glass ionomer cement (Fig.22). The patient was satisfied with the result. (Fig. 23)



**Figure 22:** Intraoral view



**Figure 23:** A pleasing appearance of the smile

### 3. Discussion

The analysis of the initial situation made it possible to detect the problems presented and the potential risks during the therapy.

In our case, the problems were an insufficient prosthetic occlusal height, a hyperplastic edentulous ridge and a short coronal height of the terminal tooth. The risk was mainly a poor periodontal and esthetic integration of the future FPD, whatever the design and the prosthetic material chosen.

The contribution of periodontal surgery was proved in this case by the edentulous ridge modification and the crown lengthening of the distal supporting tooth. This treatment procedure has improved the adverse conditions of the initial clinical situation.

Besides, the choice of the material and the prosthetic design were essential keys for a perfect integration. Yttrium stabilized zirconia (Y-TZP) was chosen for its qualities and its contribution to the present clinical situation. It has very interesting mechanical properties for the construction of a resistant bridge framework [4],[5],[6],[7]. The framework undergoes the maximum stress on the pontic and the connectors are the most solicited [2],[8].

They must be mechanically resistant, which implies two aspects:

- A maximum cross area-section depending on the prosthodontic material. Increasing the height of the connector more than its width can be expected to better resist bending.
- The design and contour shape.

The metal frameworks allow the lowest heights at the connector areas.

The cross-sectional area of all-ceramic frameworks must be increased, depending on the type of ceramic, by 50% to 150% compared to the recommended areas for metal frameworks (Table I).

**Table 1:** Recommended cross-sectional area according to framework material [2], [6], [7], [9], [10], [11]

Framework material	Recommended cross-sectional area (mm <sup>2</sup> )
Metal alloy	4 - 6
Zirconia Y-TZP (partially sintered)	7 - 9
Inceram-Zirconia	12-20
lithium Disilicate	16-20

In our case the cross-sectional area was 8 to 9 mm<sup>2</sup>, which is in line with the scientific data<sup>(2, 9, 6, 7, 10)</sup>. However, the large increase of the cross-sectional area could be in contradiction with periodontal integration requiring sufficient opening of the gingival embrasures and /or aesthetic integration requiring proper embrasures [7].

Clinically, a reduced connector size is esthetically more acceptable if there is no black triangle, and it involves easy cleaning of the interproximal areas [3], [6],[7].

Y-TZP zirconia, unlike glass-ceramics, does not require a large size of connectors [2]. Thus, the values recommended for ensuring the mechanical strength of a zirconia framework represent an important element in favor of the choice of this material in the present case.

On the esthetic level, the translucency of ceramic frameworks is an asset that allows the optical integration of the prostheses by promoting the circulation of light to the periodontal tissues [12].

Although the translucency of zirconia is lower than that of glass-ceramics, it remains better than the aluminous ceramics type Inceram-Zirconia [12], [13].

Our 55-year-old female patient had poor translucent teeth. Indication of an all-ceramic bridge with zirconia framework to replace the maxillary first premolar was the optimal solution.

### 4. Conclusion

The integration of the all ceramic FPD at the maxilla must be the object of particular attention for any practitioner concerned with this treatment success

This can only be expected after careful analysis of the clinical situation orienting our therapeutic choices. In some situations, periodontal surgery may be necessary to properly prepare the prosthetic tissue site.

In addition, all-ceramic FPD with zirconia framework, in accordance with their indications, allow our patients to benefit from the advantages of high fracture resistance with full respect of periodontal tissues and a satisfactory esthetics [11], [14]. This can be achieved through a judicious design of the frameworks to seek compromise between the mechanical, biological and esthetic requirements.

## References

- [1] Orthlieb JD, Zorbhi AE, Kordi M, Perez C. La fonction de guidage Un modèle biomécanique pour un concept thérapeutique. *CahProthese* 2004 ; 128 : 1-11.
- [2] De March P, Etienne O. Les bridges tout-céramique : exigences cliniques. *CahProthese* 2011 ; 155 :53-63.
- [3] Rosentiel SF, Land MF, Fujimoto J. Contemporary fixed prosthodontics, Third edition 2001 ;Mosby,Inc.
- [4] Mahiat Y. La zircone : cette méconnue. *Stratégie Prothétique*; 2006 ; 6 ; 1 :55-65.
- [5] A. Lebras. Quelle zircone pour quelle prothèse dentaire ? *StratégieProthétique*2003 ; 3 ; 5 : 351-62.
- [6] Murase T, Nomoto S, Sato T, Shinya A, Koshihara T, Yasuda H. Effect of connector design on fracture resistance in all-ceramic fixed partial dentures for mandibular incisor region. *Bull Tokyo Dent Coll*2014 ; 55(3) : 149-55.
- [7] Onodera K, Sato T, Nomoto S, Otoaki M, Yotsuya M. Effect of connetor design on resistance of zirconia all-ceramic fixed partial dentures. *Bull Tokyo Dent Coll*2011 ; 52(2) : 61-67.
- [8] Sailer I, Fehér A, FilserF, Gauckler LJ, Lüthy H, Hämmerle CH. Five-year clinical results of zirconia frameworks for posterior fixed partial dentures. *Int J Prosthodont*2007 ; 21,4 :151-56.
- [9] Raigrodski AJ, SaltzerAM. Clinical considerations in case selection for all-ceramic fixed partial dentures. *PractProcedAesthet Dent* 2002 ; 14(5) : 411-19.
- [10] Monchanin S, Viennot S, Allard Y, Malquerti G. Réalisation au laboratoire de prothèses fixées céramométalliques. EMC (Elsevier Masson SAS, Paris), Odontologie, 23-380-C-10,2008.
- [11] Komine F, Blatz MB, Matsumura H. Currentstatus of zirconia-basedfixedrestorations. *Journal of oral science* 2010 ; 52 ; 4 :531-39.
- [12] Laborde G, Margossian P. Restaurations céramo-céramiques. EMC (Elsevier Masson SAS, Paris), Odontologie, 23-272-C-15, 2007.
- [13] Raigrodski A. In: Clinical and laboratory considerations for achieving function and aesthetics with the Lava System. Spectrum International.IDS; 2003. p. 1-5.
- [14] TavaresR, Gonçalves L, DiasA P, Dias A C, Malheiros AS, Silva AC, BandecaMC. An harmonic smile resulted from the use of ceramic prosthesis with zirconia structure: a case report. *Journal of International Oral Health* 2014; 6(3):90-92.