

Abscess of the Nasal Septum and the Orbital Cavity Complicating an Acute Ethmoidomaxillary Sinusitis of the Child

A. Elboukhari¹, M. Lagtoubi², N Touihem³, K Nadour⁴, H Attifi⁵, M Zalagh⁶, A Zouhair⁷

ENT Department, Moulay Ismail Military Hospital, PC 50000. Meknès, University Hospital Center of Fez, Morocco

Abstract: ***Objectives:** Our objective is to present and discuss a rare situation that combines a double extrasinusal abscess complicating acute sinusitis. **Case report:** A 13-year-old boy presented to the emergency room with swelling of the upper left eyelid associated with purulent rhinorrhea and nasal obstruction of the same side. CT suspected the diagnosis of éthmoïdo-maxillary sinusitis and the two abscesses of the orbital cavity and nasal septum. The treatment included under antibiotic therapy, the surgical drainage of all intra- and extrasinusal purulent collections. **Conclusion:** The intra-orbital abscess associated with the abscess of the nasal septum is a rare complication of acute sinusitis and constitutes a diagnostic and therapeutic emergency. Early diagnosis and adapted treatment of acute sinusitis can avoid these complications.*

Keywords: intra-orbital and nasal septum double abscess, ethmoidomaxillary sinusitis

1. Introduction

Acute sinusitis is a common disease affecting children, accounting for 21% of prescriptions for pediatric antibiotics [1]. Serious complications of acute rhinosinusitis (ARS) may be secondary to the sinus proximity of craniofacial noble structures. These complications are related to the diffusion of the infectious process to neighboring structures. The focus of the complication may be intracranial, orbital or intranasal. Sometimes there may be the association of two or more complications. Some intranasal complications are rarely described. We report a rare case of acute ethmoidomaxillary sinusitis which was complicated by an abscess of the nasal septum and the orbital cavity.

2. Observation

A 13-year-old child without a history of purulent rhinorrhea, nasal surgery, bleeding tendency or trauma. He was admitted in ENT for upper eyelid swelling with conjunctival hyperemia, left purulent rhinorrhea and left nasal obstruction. The eyelid swelling was red, inflammatory, painful and fluctuating, affecting the entire upper part of the orbital cavity. The evolution of this purulent collection was made towards the fistulization to the skin (Figure 1). Endonasal examination showed a swelling of the nasal mucosa emanating from the nasal septum that obstructed left nasal cavity (Figure 1). Endoscopy after retraction of the nasal mucosa to the naphazoline lidocaine, found a left purulent rhinorrhea that came from the middle meatus. In addition, despite the retraction of the nasal mucosa, there was always a fluctuating swelling of the nasal septum coming into contact with another swelling of the left sinusomaxillary wall (Figure 2).

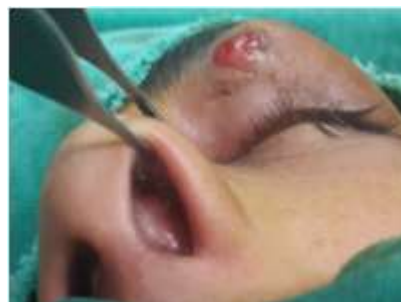

Figure 1: External view of the face showing swelling of the upper part of the orbit and nasal septum.

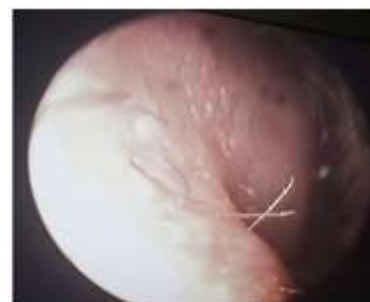

Figure 2: Endoscopic view of the left nasal cavity showing a swelling of the nasal septum.

Emergency CT has objectified a left maxillo-ethmoidal sinusitis complicated by an intra-orbital abscess with communication between the ethmoidal sinus and the orbital cavity through the thin lamina papyracea of the ethmoid (Figure 4A). The nasal septum was the site of bilateral submucoperichondrium filling with destruction of the anterior part of the septal cartilage (Figure 4B).

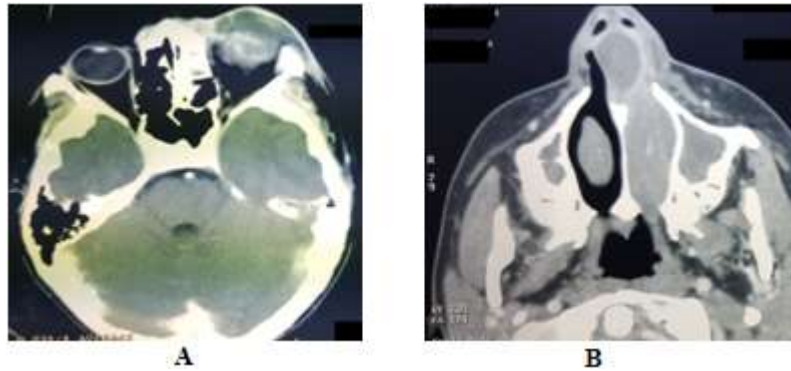


Figure 4: Axial CT showing
(A) An ethmoid sinusitis in continuity with an orbital abscess,
(B) Septal abscess and maxillary sinusitis in contact with a bulge of the sino-nasal wall

Biological evaluation showed leukocytosis at 16000 cells / ml and CRP at 83. Puncture of the purulent contents was performed at the two abscess sites, and the pathogenic microorganisms could not be isolated because of antibiotic therapy prior to collection. The patient was quickly put under parenteral antibiotherapy (amoxicillin and clavulanic acid) during his hospitalization which was relayed at his exit in peros for four weeks. It has benefited from drainage of the intra-orbital abscess by external approach; This surgical procedure was completed at the left nasal fossa by a meatotomy of the medium meatus with ethmoidectomy, which allowed the evacuation of the ethmoido-maxillary purulent contents. Concerning the nasal septum, an inter-septo-columellar incision was performed with evacuation of the abscess and resection of the necrotic fragments of the nasal septum cartilage. At the end, the nasal septum was supported by a double silastic plate placed on either side of the nasal septum with endonasal packing.

Removal of nasal packing took place on the fifth day of hospitalization and the patient was discharged. The silastic plate was removed on the 15th day after surgery. Regular follow-up of two years did not reveal any sequelae of the nasal septum or the eye.

3. Discussion

Sinusitis complications preferentially affect males and are most common in young adults and children [1] [2] [3]. Classically, sinusitis complications may result from osteitic bone destruction, congenital or acquired bony defects, or via thrombophlebitis of communicating veins [2]. Intracranial and osteitic complications are most commonly secondary to frontal sinusitis [1]. Orbital complications are the most common type of complications from acute sinusitis (80 to 91.3% of cases) [1]. Ethmoid sinusitis may spread to the orbit by defects in the thin lamina papyracea (the same mechanism we found in our case) or by the valveless ophthalmologic venous system [1].

Nasal septal abscess (NSA) in the pediatric population is a rare complication of acute rhinosinusitis [4]; its association with an orbital abscess is exceptionally described in the literature (no case so far). The collection sits between the cartilage or bone of the nasal septum and the mucoperichondrium or mucoperiosteum. NSA when associated with ARS, several mechanisms have been

proposed in the literature to explain its pathophysiology. The most probable is contiguous spread of inflammation and infection along tissue planes and/or under the periosteum or perichondrium (The same mechanism was suspected in our patient), through bone fissures or congenital bone malformations, or through hematogenous spread [4] [5]. Clinically according to the importance of swelling of the nasal septum and retention of maxillo-ethmoid sinusitis, the patient can express, pain, nasal obstruction, headache, purulent rhinorrhea, fever, dysosmia and epistaxis [5] [6]. Anterior rhinoscopy and nasal endoscopy allow an accurate assessment of lesions. The ophthalmologic symptomatology varies according to the evolutionary stage of the infectious intraorbital process; the transition from one stage to another is unpredictable. The *Streptococcus milleri* group is the most common pathogen isolated from purulent complications of sinusitis.

CT is the examination of choice, allows to specify the starting point of the infection (ethmoidomaxillary sinus in this observation), to look for the different complications and abscess locations (intra-orbital and nasal septum in our case) and to evaluate the stage of infection [6].

The therapeutic management of ARS complications always relies a broad spectrum antibiotherapy and surgical approach. Surgical options include traditional external orbital approaches and more esthetic procedures, including the transcaruncular external approach; Conventional external surgery makes it possible to efficiently drain the orbital abscess [2]. Recent techniques of transnasal endoscopic surgery allow the access to median orbital abscesses, to eradicate by mean meatotomy with ethmoidectomy the sinus infection [2]. This endoscopic surgery makes it possible to treat other endonasal complications of sinusitis, in particular the abscess of the nasal septum which it ensures the evacuation with resection of cartilaginous necrosis debris. The abscesses of the nasal septum and the orbital cavity, badly or lately treated can generate morbid sequelae; In the nose we distinguish early (saddle nose deformity, deviated nasal septum, and columellar retraction) and late sequelae (midface and maxillary hypoplasia, grossly deviated nasal septum, septal perforation) [7]; In the orbit can occur disorders of the mobility of the eye and / or a blindness.

4. Conclusion

The intra-orbital abscess associated with the abscess of the nasal septum is a rare complication of acute sinusitis and constitutes a diagnostic and therapeutic emergency. The use of imagery can guide the management. Early diagnosis and adapted treatment of acute sinusitis can avoid complications, which threaten not only the functional but also the vital prognosis.

References:

- [1] Lance E. Oxford, MD, John Mc Clay, MD. Complications of Acute Sinusitis in Children. Otolaryngology Head and Neck Surgery. 2005; 133: 32-37. PMID: 16025049
- [2] Oxford LE, McClay J. Medical and surgical management of subperiosteal orbital abscess secondary to acute sinusitis in children. Int J Pediatr Otorhinolaryngol. 2006; 70: 1853-61. PMID: 16905200
- [3] Laure B, Tiguemounine J, Picard A, Goga D. Orbital abscess of dental origin. Rev Stomatol Chir Maxillofac .2004; 105:125-9. PMID: 15211222
- [4] Alshaikh N, Lo S. Nasal septal abscess in children: from diagnosis to management and prevention. Int J Pediatr Otorhinolaryngol. 2011; 75 (6):737-44. PMID: 21492944
- [5] Pang KP, Sethi DS. Nasal septal abscess: an unusual complication of acute sphenoiditis. J Laryngol Otol. 2002; 116: 543-5. PMID: 12238677
- [6] Carty PA, Berkowitz RG. Hematoma and abscess of the nasal septum in children. Arch Otolaryngol Head Neck Surg .1996; 122: 1373-6. PMID: 8956753
- [7] Sayin I, Yazici ZM, Bozkurt E, Kayhan FT. Nasal septal hematoma and abscess in children. J Craniofac Surg. 2011; 22 (6): 17-19.