

Assessment of Greater Palatine Canal Anatomical Pathways in Iraqi People by using Cone Beam Computed Tomography

Weaam H. Abdullah¹, Ali H. Abbas Alhussaini², Maisaa K. Muhamed Ali³, Haydar Al-Shimmari⁴

¹B.D.S, Department of Oral and maxillofacial radiology, College of Dentistry, University of Baghdad, Iraq Baghdad.

²B.D.S., M.Sc. Assistant professor, Department of oral and maxillofacial surgery, University of Baghdad.

³B.D.S., M.Sc. Maxillofacial radiologist, department Oral and Maxillofacial Radiology, Al Sader Specialized Health Center for dental treatment

⁴ B.D.S., M.Sc., Lecturer, Department of Medical and Health, College of Baghdad

Abstract: ***Background:** The using of the cone beam computed tomography for investigation the greater palatine canal anatomical pathways and length is important to facilitate the surgical procedures within the canal region. The aim of the current study is to determine most anatomical pathways of the greater palatine canal in both coronal and sagittal views among Iraqi people by using cone beam computed tomography. **Materials and methods:** This prospective study included 60 Iraqi patients (28 males and 32 females) from who selected after considering the inclusion criteria, which include age range (21 - 60 years), with no dentofacial deformities or pathological lesion at the maxilla. The path of the greater palatine canal represented by the description of the descending length tracing lines in the canals in coronal and sagittal views by using cone beam computed tomography. **Results:** In the present study there are six anatomical pathways of the greater palatine canal in coronal view, and most anatomical pathway was inferior lateral then inferior medial, while in Sagittal view there are four anatomical pathways of the greater palatine canal, and most anatomical pathway was anterior inferior. **Conclusion:** The Cone beam CT imaging scan can detect the exact anatomical pathway of greater palatine canal, the most anatomical pathway of the greater palatine canal in coronal view was inferior lateral then inferior medial, and in Sagittal view was anterior inferior.*

Keywords: Greater palatine canal, Cone beam computed tomography

1. Introduction

The anatomy of the greater palatine canal (GPC) is important to oral maxillofacial surgeons, dentists and otolaryngologists who carry out procedures in this area e.g., administration of local anesthesia, orthognathic LeFort I osteotomies, dental implant placement and sinonasal surgeries[1]. The GPC houses greater palatine nerve which represents branch of the maxillary division of the trigeminal nerve, and its posterior inferior lateral nasal branches, in addition to the descending palatine artery a branch of the third division of the maxillary artery[2]. The infratemporal surface of the maxilla represent the anterior wall of the GPC, while perpendicular plate of the palatine and the pterygoid process of the sphenoid formed the medial and posterior wall respectively[3]. The maxillary sinus is situated anterior, the pterygoid plates posterior, and the nasal concha and nasal cavity medial to GPC, so the anatomy of these structures certainly influences the anatomy of the GPC. When making surgical procedures in GPC region, conservation of the descending palatine artery and palatine nerves is necessary to stay away from excessive bleeding [4]. In other hand, regional nerve block may be ineffective if excessive resistance is happened when injecting local anesthesia into the GPC, this may be explained due the variation in the anatomical pathway. The aim of this study was to identify the most common anatomic pathways of the GPC by using cone beam computed tomography (CBCT) data obtained from Iraqi adult patient.

2. Materials and Methods

A prospective study of CBCT scan for (60) Iraqi adult patients (32 female and 28 male) with age between (21-60) years attending Oral and Maxillofacial Radiology department of Al Sader Specialized Health Center for dental treatment in Baghdad city who underwent CBCT scans for different purposes since November 2016 to March 2017. The patients who visited a diagnostic centre were selected after considering the inclusion criteria which are: age range (21 - 60 years), no dentofacial deformities or pathological lesion at the maxilla. All patients had their CBCT scans taken for other purposes and they had informed consent for participation in this study. The CBCT examinations were carried out for every patient with Kodak 9500/Care stream (France), full rotation scan was performed with the size of field of view will be 18× 20.6cm diameter and the exposure parameters of radiographic machine include: voxel size 300, KV 90, MA 10. The analysis was conducted using the distance measuring tool of care stream(CS 3D)software. All images were obtained with volume 1 (high-resolution) and high-contrast options. The statistical analysis was made by using SPSS 20.0.0, Minitab 17.1.0, MedClac 14.8.1 software package was used to make the statistical analysis. Chi square test Cohen's kappa analysis and pie chart were used in statistics of study. Determination of the anatomical pathway of GPC in both sagittal and coronal view depending on methods of Haward-Swirzinski, *et al* in 2010 which stated that (The path of the greater palatine canal represented by the description of the descending length tracing lines in the

canals) [1]. so firstly locate the PPF as its pyramidal shaped begins below the middle cranial fossa, positioned lateral to nasal cavity. Then the superior limit of GPC can be determined by using pterygoid canal, the programs line coordinates was used to mark superior-inferior course of the pterygoid canal, so the vertical level of pterygoid canal was identified in different analysed plans. The length of GPC was measured from the vertical level of pterygoid canal to GPF as inferior limit of canal in both coronal and sagittal views. After that the GPC pathway assessed by describing the anatomical routes of the canal in both coronal and sagittal views.

3. Results

The GPC anatomical pathways investigation starting from pterygopalatine fossa (PPF) and ended in the greater palatine foramen (GPF), the current study result revealed six pathway types in the coronal view and four pathway types in the sagittal view as shown in figures (1) and (2).

A. In the coronal plane:

- 1) The GPC travels in a direct inferior direction (figure1, A).
- 2) The GPC travels in inferior medial then inferior lateral direction then inferior medial direction (figure1, B).
- 3) The GPC travels in an inferiorlateral direction then change into a direct inferior (figure1, C).
- 4) The GPC first travels in an inferiorlateral direction then change into a direct inferior direction, and finally change direction in an inferiomedial (figure1, D).
- 5) The GPC travels in an inferiorlateral direction then changes to an inferiomedial direction (figure1, E).
- 6) The GPC travels firstly in inferior medial direction then change into direct inferior direction (figure1, F).

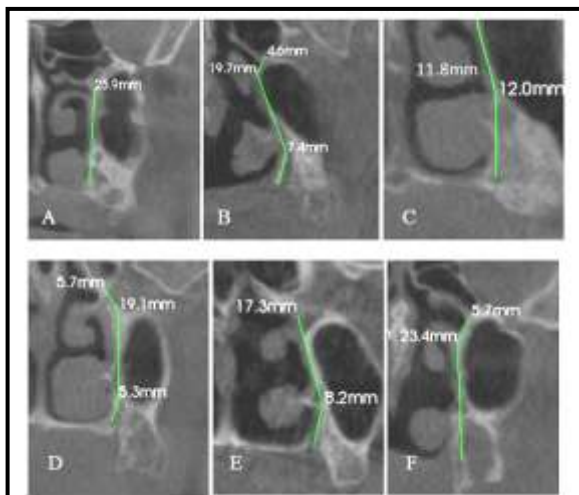


Figure 1: The anatomical pathways of greater palatine canal in coronal view

B. In the sagittal plane:

- 1) The GPC travels in an anterior inferior direction from the PPF (figure 2, A).
- 2) The GPC first travels in anterior inferior then inferior direction from the PPF (figure2, B).
- 3) The GPC first travels in an inferior direction from the PPF (figure2, C).
- 4) The GPC travels in an inferior direction and then in an anteriorinferior direction through the remainder of the canal (figure 2, D).

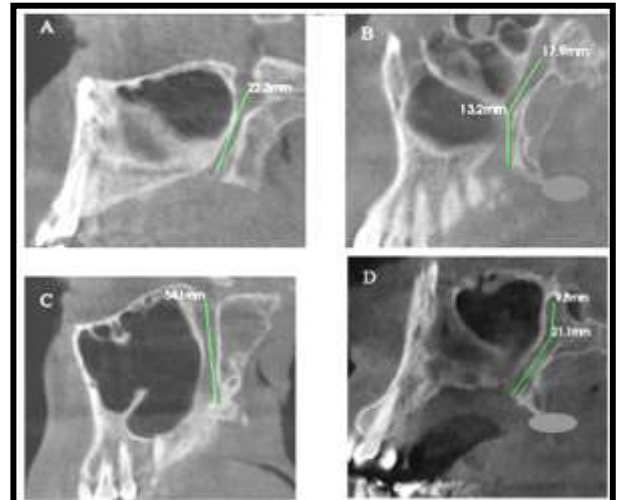


Figure 2: The anatomical pathways of greater palatine canal in sagittal view

The types of GPC pathways were summarized in table (1), figures (3) and (4) which show the frequency of canal pathways incidence observed in both coronal and sagittal views, unilaterally (out of each 60 right and 60 left), bilateral symmetry (60 pairs), and overall incidence (120 right and left sides).

Table 1: Frequency of GPC pathways incidence

Pathway	Right side unilateral incidence	Left side unilateral incidence	Bilaterally symmetrical (pairs)	Overall incidence
N	60	60	60	120
Coronal view				
direct inferior	19 (31.7%)	19 (31.7%)	10 (16.7%)	38 (31.7%)
Inferior medial then inferior lateral then inferior medial	1 (1.7%)	2 (3.3%)	No symmetry	3 (2.5%)
inferior lateral then direct inferior	4 (6.7%)	3 (5.0%)	1 (1.7%)	7 (5.8%)
inferior lateral then direct inferior then inferior medial	1 (1.7%)	2 (3.3%)	1 (1.7%)	3 (2.5%)
inferior lateral then inferior medial	34 (56.7%)	30 (50.0%)	22 (36.7%)	64 (53.3%)
inferior medial then direct inferior	1 (1.7%)	4 (6.7%)	1 (1.7%)	5 (4.2%)
Sagittal view				
anterior inferior	31 (51.7%)	31 (51.7%)	21 (35.0%)	62 (51.7%)
anterior inferior then inferior direction	4 (6.7%)	2 (3.3%)	No symmetry	6 (5.0%)
direct inferior	3 (5.0%)	4 (6.7%)	2 (3.3%)	7 (5.8%)
inferior direction then anterior inferior	22 (36.7%)	23 (38.3%)	14 (23.3%)	45 (37.5%)

N: Number

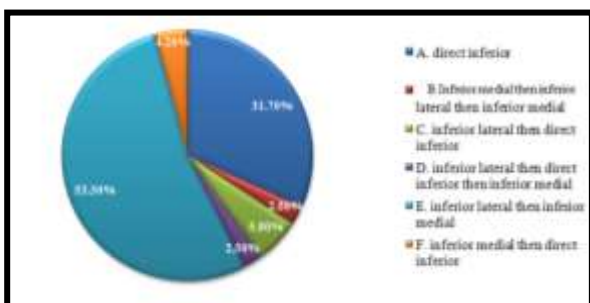


Figure 3: Pie chart show overall incidence of GPC pathways in the coronal view

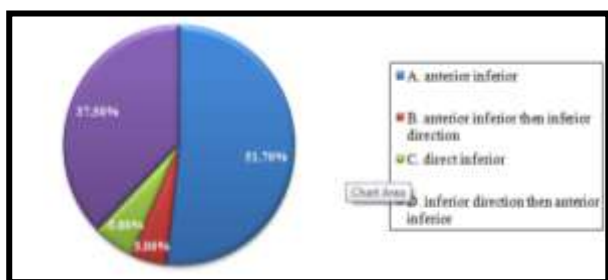


Figure 4: Pie chart show overall incidence of GPC pathways in sagittal view

Degree of symmetry between left and right sides of GPC pathways were compared in both male and female for coronal and sagittal views by Cohen's kappa analysis of agreement as illustrated in table (3.8), which shows fair agreement in all the groups ($\text{kappa} < 0.4$), that indicating low probability of symmetry in both sides. Only in female in sagittal view shows moderate agreement between left and right side of GPC pathways and symmetry is higher (47.9% agreement).

Table 2: Degree of symmetry between the right and left sides of GPC pathways

Plane	Sex	Number	Kappa	Strength of agreement
Coronal	Female	32	0.347	Fair
	Male	28	0.284	Fair
	Total	60	0.318	Fair
Sagittal	Female	32	0.479	Moderate
	Male	28	0.210	Fair
	Total	60	0.347	Fair

4. Discussion

The GPC have important role in achieving a maxillary nerve block and in reducing the bleeding during endoscopic sinus surgery or septorhinoplasty, stimulating the pterygopalatine ganglion in patients with migraine and cluster headaches, in addition to cerebral vasospasm conditions. Also the position of GPC is vital for the palatal free vascular flaps surgery, maxillary sinus surgery in addition to the cleft palate closure and in LeFort I osteotomy [5, 6]

The reduced knowledge of the GPC region anatomy can lead to many complications that can be avoided through the correct estimation of the GPC position, length, and anatomical pathway by using CBCT imaging modality which provide high resolution images with a less radiation dose and shorter exposure time in comparison to conventional CT [7,8,9,10]

The purpose of this study was to identify the most common anatomical pathway of the greater palatine canal in both coronal and Sagittal view among Iraqi people by using cone beam computed tomography.

In the present study the anatomical pathways and their incidence illustrated in table (1) and figure (1), (2), (3) (4). In the coronal view, the most common pathway of the GPC was in an inferiorlateral direction then changes to an inferiormedial direction, with over all incidence was 64 (53.3%), this result compatible with Asha et al., 2015[11], but it came in disagreement with the most anatomical pathway stated by Howard-Swirzinski et al., 2010; Sheikhi et al., 2013, which was inferior-lateral direction then direct inferior direction[1,12].

In the sagittal view the most common pathway was the GPC travels in an anterior inferior direction from the PPF with over all incidence was 62 (51.7%), this result was consistent with Howard-Swirzinski et al., 2010, but it was disagree with the most anatomical pathway stated by Sheikhi et al., 2013, which was an inferior direction and then in an anterior-inferior direction, and Asha et al., 2015, which was

an inferior direction and then change to an anterior-inferior direction then retain to inferior direction.

The variance in results can be explained by the differences in ethnicity, sex or due to the small sample included in the current study.

Degree of symmetry between left and right sides of GPC pathways were compared in both male and female for coronal and sagittal views by Cohen's kappa analysis of agreement as illustrated in table (2), which show fair agreement in all the groups except female on sagittal plane (moderate agreement), that indicating low probability of symmetry between right and left sides, this result explained scientifically that asymmetry is frequent in craniofacial bones. Incompatible growth of left and right canals may be due to environmental or genetic factors. Asymmetric expression of craniofacial features could be related to inheritance, specifically to the masticatory apparatus or the functional activity of the musculoskeletal system [12].

References

- [1] Howard-Swirzinski, K., Edwards, P.C., Saini, T.S. and Norton, N.S. Length and geometric patterns of the greater palatine canal observed in cone beam computed tomography. *International journal of dentistry*, 2010.
- [2] Apenhasmit, W., Chompoopong, S., Methathrathip, D., Sangvichien, S. and Karuwanarint, S., (Clinical anatomy of the posterior maxilla pertaining to Le Fort I osteotomy in Thais), *Clinical Anatomy*, 2005; vol. 18, no. 5, pp. 323–329.
- [3] Norton, N. S. *Netter's Head and Neck Anatomy for Dentistry*, Saunders, 2007; Philadelphia, Pa, USA.
- [4] White, S.C. and Pharoah, M.J.. *Oral Radiology: Principles and Interpretation*. Textbook, 2014; 7th ed. Elsevier Mosby
- [5] Nimigean V, Nimigean VR, Buțincu LA, Sălăvăstru DI, Podoleanu L. Anatomical and clinical considerations regarding the greater palatine foramen. *Rom J MorpholEmbryol*. 2013 Jan 1;54(3 Suppl):779-83.
- [6] Tomaszewska IM, Tomaszewski KA, Kmiotek EK, Pena IZ, Urbanik A, Nowakowski M, Walocha JA. Anatomical landmarks for the localization of the greater palatine foramen—a study of 1200 head CTs, 150 dry skulls, systematic review of literature and meta-analysis. *Journal of anatomy*. 2014 Oct 1;225(4):419-35.
- [7] Piagkou, M., Xanthos, T., Anagnostopoulou, S., Demesticha, T., Kotsiomitris, E., Piagkos, G., Protogerou, V., Lappas, D., Skandalakis, P. and Johnson, E.O. Anatomical variation and morphology in the position of the palatine foramina in adult human skulls from Greece. *Journal of Cranio-Maxillofacial Surgery*. 2012; 40(7), pp.e206-e210.
- [8] Horner K, Jacobs R, Schulze R. Dental CBCT equipment and performance issues. *Radiation protection dosimetry*. 2012 Nov 21;153(2):212-8
- [9] Ikuta CR, Cardoso CL, Ferreira-Júnior O, Lauris JR, Souza PH, Rubira-Bullen IR. Position of the greater palatine foramen: an anatomical study through cone beam computed tomography images. *Surgical and Radiologic Anatomy*. 2013 Nov 1;35(9):837-42.
- [10] Aoun, G. and Nasseh, I. The Length of the Greater Palatine Canal in a Lebanese Population: a Radio-anatomical Study. *Acta Informatica Medica*. 2016;24(6), p.397.
- [11] Asha, M.L., Arun Kumar, G., Sattigeri Anupama, V., Raja Jigna, V. and Diksha, M. Cone beam computed tomographic analysis of anatomical variations of greater palatine canal and foramen in relation to gender in South Indian population. *Oral Health Dent Manag*, 2015; 14, pp.384-90.
- [12] Sheikhi, M., Zamaninaser, A. and Jalalian, F. Length and anatomic routes of the greater palatine canal as observed by cone beam computed tomography. *Dental research journal*. 2013; 10(2), p.155.
- [13] Rossi, M., Ribeiro, E. and Smith, R. Craniofacial asymmetry in development: an anatomical study. *The Angle orthodontist*, 2003; 73(4), pp.381-385.