

Study of Metopic Suture in Dry Human Skulls

Sunara Shrestha¹, Laju M Basnet², Samit K Ghosh³

^{1,2} Lecturer, Department of Anatomy, Nepal Medical College

³ Professor, Department of Anatomy, Nepal Medical College

Abstract: Frontal bone develops from two halves connected by metopic suture. Metopic suture usually gets obliterated in the 1st postnatal year. But it may persist in small area in the adult skulls. The present study was undertaken to observe the presence of the metopic suture in the collected adult human skulls obtained from Nepal Medical College. 57 complete human skulls were taken from the Department of Anatomy, for the study of metopic suture. 42 crania had the metopic suture, out of which 4 crania were noted with the metopism. The partial sutures were of linear, V-shaped and double varieties with the highest frequency of the linear (31.6%) followed by double sutures (28.1%) and the least observed were V-shaped sutures (7%). The length of the complete metopic suture was calculated to be 12.82cm.

Keywords: Frontal bone, Metopic suture, Metopism

1. Introduction

Metopic suture is formed between two halves of frontal bone during the development. It usually closes in the first post natal year^[1] but may take 6-8 years for the closure.^[2,3] The suture may even persist in small percentage adult skulls in different ethnic groups.^[1] Metopic suture is dentate type of suture. In the posterior part, it becomes more simple and direct and this part is called as pars bregmatica. The posterior end of the suture usually does not meet sagittal suture. Similarly, its anterior end also fails to meet the internasal suture.^[4]

When the suture is present in the adult, it is either in partial or complete form. In the complete form, the suture extends from nasion to the bregma and is known as Metopism.^[5] Metopism is more common in higher races and brachycephalics. In incomplete/ partial form, the persistent metopic suture begins from nasion while the extent of this variety is variable. The partial sutures have been described in different forms: U- shape, V-shape, Y-shape and linear.^[6] Though the metopic sutures are not considered as pathological, ^[2] premature closure of the suture may lead to craniosynostosis and trigonocephaly.^[7] The factors causing metopism may include abnormal growth of cranial bones, hydrocephalus, growth retardation, heredity, mechanical causes and hormonal dysfunction.^[8] Metopism is important for the radiologist, neurosurgeon and forensic medicine because the fracture of frontal bone is most common in metopic suture.^[9]

In the present study, an attempt was to observe the characteristic and incidence of the metopic suture in the dry human skulls of Kathmandu.

2. Materials and Methods

The study was conducted in Department of Anatomy, Nepal Medical College. 57 skulls with intact calvaria were examined for the presence of the metopic suture. The skulls were examined through the naked eyes and hand lens. Both the partial and complete metopic sutures were observed and their length, extent and shapes were noted and described.

For the measurement of length, thread was spread from the nasion over the suture and subsequently measured against the scale.

3. Result and Observations

Out of 57 skulls, 15 skulls (26.3%) metopic suture were completely ossified and obliterated. While 4 skulls (7%) presented the metopism, the remaining 38 skulls (66.7%) were noted with the partial metopic suture of varying shape, size and length. Most of the partial sutures were extending from nasion to glabella, while in 2 skulls the suture was extending near to the bregma i.e. they ended few centimeters in front of bregma.

The persistent complete metopic sutures present were observed to be linear in shape while, the partial metopic sutures were linear, double or V-shaped. In partial sutures, linear shapes were noted largest number of skulls i.e. in 18 skulls with frequency of 31.6% followed by double sutures in 16 skulls (28.1%). In 4 skulls (7%) the V-shaped sutures were observed.

Regarding the length of the sutures; the average length of the complete suture was calculated to be 12.82cm with least length 12.4cm and maximum 13.3cm. The partial sutures were noted of various lengths with smallest of 0.4cm and longest about 11.7cm.

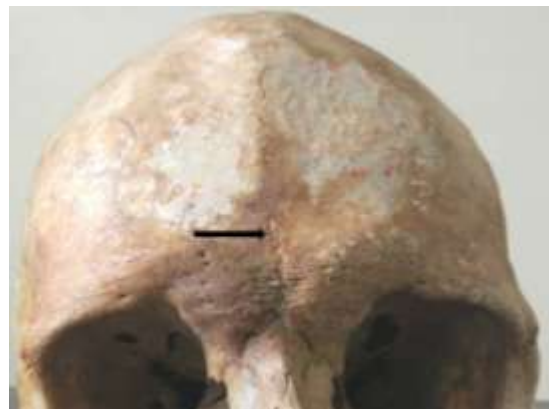




Figure 1: Complete Metopic Suture not meeting with sagittal suture (Anterior and Superior views) (MS- Metopic Suture, CS- Coronal Suture, SS- Sagittal Suture)

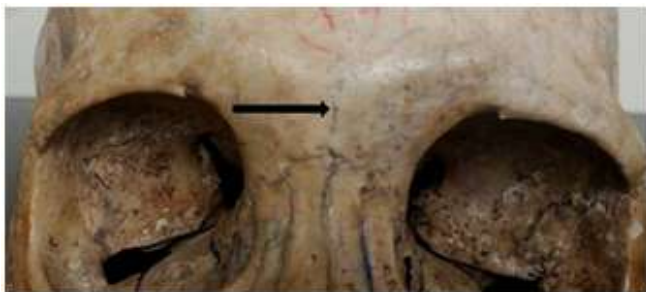

Figure 2: Partial Metopic Suture Linear type

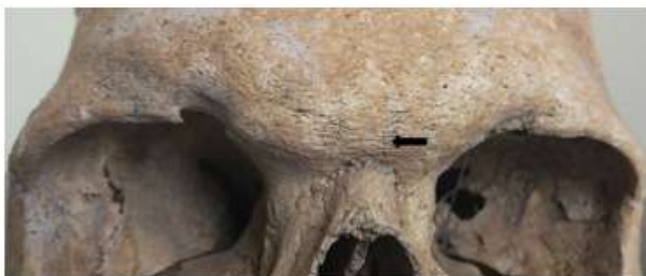

Figure 3: Partial Metopic Suture Double variety

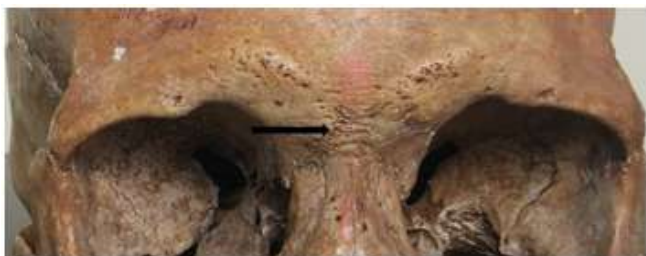

Figure 4: Partial Metopic Suture V-shaped

4. Discussion

Various studies have been conducted on the metopic suture by different investigators. The study was conducted to increase the horizon of the knowledge of the skull. In the present study, metopic suture was present in 42 skulls (78.68%) including both complete and partial sutures.

Metopism was present in 4 skulls (7%) while incomplete suture in 38 skulls (66.7%).

Table 1: Showing the incidence of metopism in various populations

Population	Incidence of Metopism (%)
Nigerian (1983) ^[10]	3.40%
Thai (2015) ^[11]	2.83%
Brazil (2016) ^[12]	4.76%
European (2017) ^[13]	0.99%
East Asian (2017) ^[13]	0.40%
Egyptian (2017) ^[13]	0.40%
Bengali (2017) ^[13]	0.20%
Nepalese (2003 and 2017) ^[5, 14]	3.92% and 3.75%
Present	7%

The incidence of metopism in this study was similar as reported by the author in Western Rajasthan (6.5%)^[7] whereas, it was higher than the findings observed by various others authors on different populations in different period^[4,6,10-13,15-17,20] (Table 1 and 2). Regarding the partial metopic suture, our observation of 66.7% was close to the finding of Murlimanju et al (63%)^[17] in India. While the prevalence of the incomplete suture was higher in this study than documented by other authors in Nigerian skull (31.25%)^[10], Nepalese (7.84%)^[5], Thai population (4.67%)^[12] and various parts of India: UP (21.36%)^[6], North India (14.6%)^[15], South India (26.4%)^[16], Andhra Pradesh (4.4%)^[20], Western Rajasthan (34%)^[9].

Table 2: Showing the incidence of metopism in various parts of India

Author	Location	Incidence of Metopism (%)
Das et al (1973) ^[6]	Uttar Pradesh	3.31%
Yadav et al (2010) ^[15]	North India	3.5%
Hussain et al (2010) ^[16]	South India	3.2%
Murlimanju et al (2011) ^[17]	Mangalore	1.23%
Masih et al (2013) ^[9]	Western Rajasthan	6.5%
Wadekar et al (2014) ^[18]	Mumbai, Maharashtra	1.25%
Khandare et al (2014) ^[19]	Mumbai, Maharashtra	4%
George et al (2015) ^[3]	South India	4%
Hemalata et al (2016) ^[20]	Andhra Pradesh	2.22%

Partial metopic suture is also classified in to various types: linear, U-shaped, V-shaped and double^[6]. In this study, only linear, double and V-shaped metopic sutures were observed. U-shaped suture was not observed in this study. Linear type partial metopic sutures were most frequently observed which other also observed congruous with various researchers. Among the total number of skulls, the incidence of linear type was 38.6%, it was higher than documented for Nigerian skulls (24.27%)^[10] and Indian population: Das et al (17.57%)^[6], Murlimanju et al (22.2%)^[17], Wadekar et al (16.25%)^[18] and Masih et al (20%)^[9].

Following the linear variety was the second commonest type in the present study was double metopic suture, which was present in 28.1%. It is recorded higher than by Murlimanju et al (19.7%)^[17] and Bilodi et al (1.96%)^[5]. V-shaped suture was the least observed in this investigation, 7.0% which was similar to the finding of Masih et al (6%)^[9], lower than of

Murlimanju et al (21%)^[17] and higher than that of observed by Ajmani et al (0.97%)^[10] and Wadekar et al (5%)^[18]. Regarding the length of the metopic suture, the mean length was observed to be 12.82cm which was similar to the results obtained Yadav A et al. (12.8cm)^[15], Das et al (12.1cm)^[6], Skrzat et al (12.31cm)^[2] while in Bilodi et al found 11.5cm^[5] which is shorter than this study.

5. Conclusion

The incidence of the Metopic suture in the present study was found to be 73.7% with metopism in 7% skulls and partial metopic suture in 66.7% skulls. The incidence of the metopic suture seems higher in this study in comparison with the previous investigations. With the higher frequency of the metopic suture, the surgeons, radiologists and forensic experts had to be more discrete as it easily confuses with the fracture.

6. Future Scope

Further research is necessary to be conducted in large sample size focusing on the age, sex and ethnicity. The radiological studies can also be done to know the incidence of the metopic suture in living population.

References

- [1] Black S. External Skull. Gleeson M, editor. Anatomy (41st Ed.). Elsevier 2016: 416.
- [2] Skrzat J, Walocha J and Zawilinski J. A note on the morphology of the metopic suture in the human skull. *Folia Morphol.* 2004; 63 (4):481-484.
- [3] George AS and Thenmozhi MS. Study of occurrence of metopic suture in adult South Indian skulls. *J. Pharm. Sci. & Res.* 2015; 7(10): 904-6.
- [4] Jones FW. Buchanan's Manual of Anatomy. 7th Ed. Bailliere, Tindall & Cox., London 1946; 226- 229.
- [5] Bilodi AK, Agrawal BK, Mane S, Kumar A. A study of metopic sutures in human skulls. *Kathmandu Univ Med J.* 2003; 2:96-9.
- [6] Das AC, Saxena RC and Beg MAQ. Incidence of Metopic suture in UP subjects. *J Anat Soc India.* 1973; 22: 140-143.
- [7] Zumpano PM, Carson BS, Marsh JL, Vanderkolk CA, Richtsmeier JT. Three- dimensional morphological of isolated Metopic synostosis. *Anat Rec.* 1999, 256: 177-199.
- [8] Del Sol M, Binvignat O, Bolini PD, Prates JC. Metopism in Brazilians. *Rev Paul Med.* 1989, 107: 105-107.
- [9] Masih WF, Gupta S, Saraswat PK and Aggarwal SK. Autopsy study of metopic suture incidence in human in Western Rajasthan. *National Journal of Medical Research.* Jan-March 2013; 3 (1): 63-65.
- [10] Ajmani ML, Mittal RK and Jain SP. Incidence of the metopic suture in adult Nigerian Skulls. *J Anat.* 1983; 137(1): 177-183.
- [11] Khamanarong K, Tuamsuk P, Woraputtaporn W, Malivalaya N, Sawatpanich T, Toomsan Y and Iamsaard S. Incidence of Metopism in Adult Thai Skulls. *Int J Morphol.* 2015; 33(1): 51-54.

- [12] Bernardes FM, Giroldo AM, Roquette AGD and Marques KV. Incidence of Metopism in adult skulls from Southeast Brazil. *Austin J Anat.* 2016; 3(3):1059.
- [13] Bliss KN, Russell ML, Koons AW, Mangus KR and Zdilla MJ. Comparison Analysis of Metopism Prevalence in Sex and Various populations. *The FASEB Journal.* April 2017; 31(1).
- [14] Sah Sk, Chaudhary D and Pandey N. Study of Metopism and Wormian bones in dry skulls of Human cadavers in Nepal. *Int J Anat Res.* 2017; 5(1): 3443-46.
- [15] Yadav A, Kumar V and Srivastava RK. Study of Metopic Suture in the adult human skulls of North India. *J Anat Soc India.* 2010; 59(2): 232-236.
- [16] Hussain SS, Mavishetter GF, Thomas ST and Prasanna LC. Incidence of Metopic Suture in adult South Indian Skulls. *J Biomed Sci and Res.* 2010; 2(4): 223-226.
- [17] Murlimanju BV, Prabhu LV, Pai MM, Goveas AA, Dhananjaya KVN and Somesh MS. Median frontal sutures- Incidence, morphology and their surgical radiological importance. *Turk Neurosurg.* 2011; 21(4):489-493.
- [18] Wadekar PR, Pundge SJ, Fulpatil MP and Pandit SV. Study of incidence of metopic suture in adult skulls. *IJBAMR.* 2014; 4(1): 277-283.
- [19] Khandare SV, Shinde AB and Punpale SB. Incidence of metopism in Mumbai region of Maharashtra. *IJBAMR.* Sep 2014; 3(4): 212-217.
- [20] Hemlata G and Subba Rao M. Persistent Metopic suture in adult skulls of Andhra Pradesh. *ISOR-JDMS.* Dec 2016; 15(12):04-06.