

# Anaesthetic Management of Neonate with Giant Occipital Meningoencephalocele: Case Report

Dr. Rajan Pandya<sup>1</sup>, Dr. Suman Sahu<sup>2</sup>, Dr. Olvyna D'Souza<sup>3</sup>, Dr. Samrajni Ganguly<sup>4</sup>

Department of Anesthesiology, MGM Medical College and Hospital Navi, Mumbai, Maharashtra, India

**Abstract:** *Meningoencephalocele is herniation of cerebrospinal fluid, brain tissue and meninges through the skull defect. The anaesthetic management of occipital meningoencephalocele is challenging because of the difficulty in securing airway, prone position, blood loss and, perioperative care. The two major aims of the anaesthesiologists while caring for children with occipital encephalocele intraoperatively are to avoid premature rupture of the encephalocele and to manage a possible difficult airway due to restricted neck movement and inability to achieve optimal position for intubation of the trachea. We report a case of giant occipital meningoencephalocele presented for surgical excision. Perioperative management of patients with giant meningoencephalocele may be challenging for both anaesthesiologist and neurosurgeon. These patients must be managed closely with an interdisciplinary approach.*

**Keywords:** Meningoencephalocele; Occipital, Anaesthesia; Prone position; Difficult intubation

## 1. Introduction

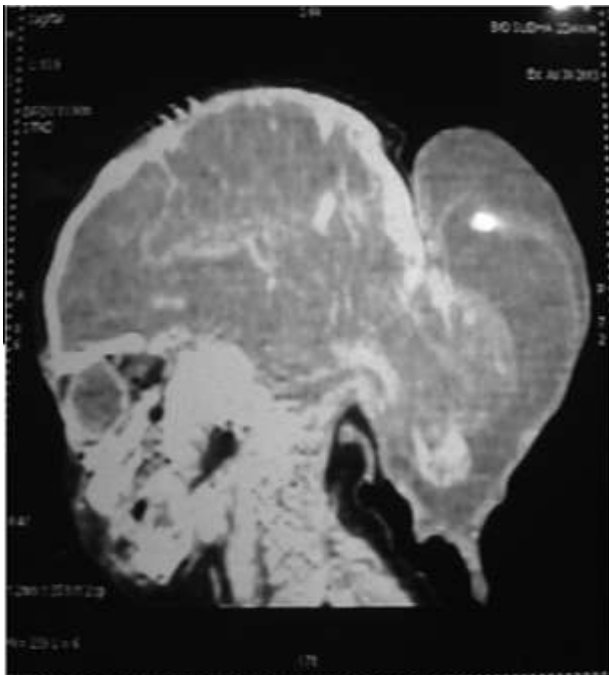
The term cephalocele refers to a defect in the skull and dura with extracranial extension of intracranial structures. Cephaloceles are divided into four types: meningoencephalocele, meningocele, atretic encephalocele and gliocele. Meningoencephalocele is a hernial protrusion of part of meninges and neural elements in a sac through the skull defect [1]. In Southeast Asia, the incidence is approximately 1 in 5000 live births [2]. The occipital bone is the most common location for cephalocele. Neurological outcome of such malformations depends on the size of the sac, neural tissue content, hydrocephalus, associated infection, and other pathologies that accompany this condition.

## 2. Case Report

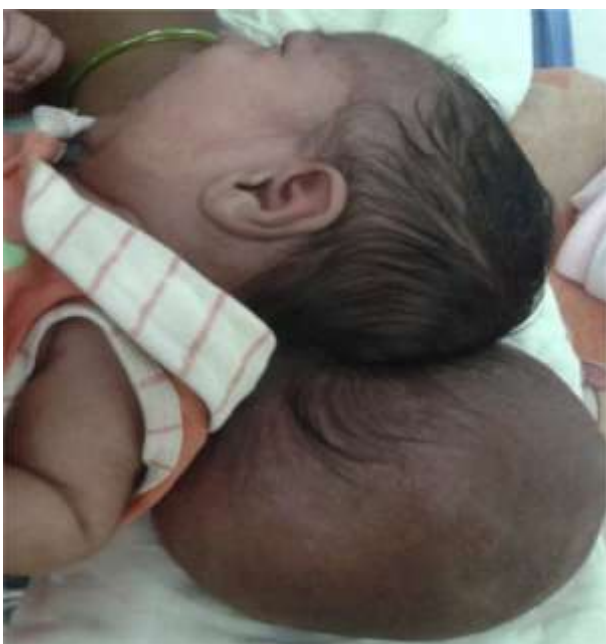A 1 month old male neonate presented with a giant occipital meningoencephalocele and was scheduled for surgical excision. The neonate had been surprisingly delivered by a normal vaginal delivery in government hospital at term and had birth weight of 3 kg. The baby cried immediately after birth. The mother had irregular prenatal care. The baby had been accepting breast feeds well since birth and had been passing stools and urine regularly. There were no signs of meningeal irritations or convulsions and there was no neurological deficit. Cardiovascular and respiratory system examination was normal. Present baby weight was 3.5 kg. The swelling was present since birth and had gradually increased to the size of 14 - 12 - 11 cm with a head circumference of 39 cm. The meningomyelocele was more or less oblong with one side bulging more than the other and size more than head circumference (Fig. 1). The MRI brain showed a defect of size 3.2 cm in the occipital region through which parenchymal tissue was seen herniating. The herniating mass measured about 4.7 - 3.5 - 3.2 cm. The mass was surrounded by hypodense collection with multiple thickened septae within suggestive of CSF collection with thickened meninges. There were suggestive of genu and part of body of corpus callosum partial agenesis. Only body of right ventricle was visualized, and rest

ventricular system was not visualized. These imaging features were suggestive of Occipital meningoencephalocele with partial agenesis of corpus callosum (Fig. 2). The CT Abdomen showed agenesis of left kidney with compensatory hypertrophy of right kidney. 2D ECHO was normal. Laboratory investigations were within normal limits.

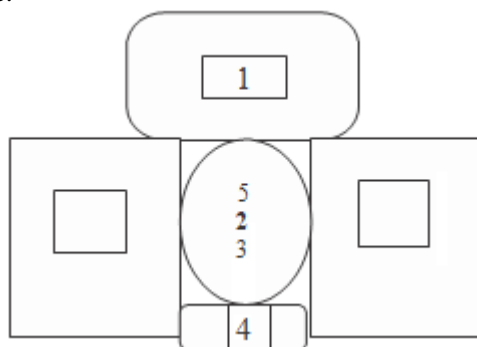
Baby was kept NPO for 4 h on the day of surgery and Ringer lactate was started at the rate of 14 ml/h by syringe pump. We planned for intubation in supine position. As the meningoencephalocele was bigger than the patient's head, and was oblong in shape, positioning of the head was anticipated to be difficult, the baby was kept on a rectangular pillow (number 1 in Fig. 3.1) with his head and the meningoencephalocele extending beyond the edge of the pillow. The head support was designed using three separate blocks made of surgical towels. After placing the child on the pillow, the head and neck were supported by an anaesthesiologist's hand under the neck. The two blocks supporting the swelling from the lateral sides (numbers 2 and 3 in the Fig. 3.1) were rectangular and were supporting the longer sides of the oval swelling. Individual block was made of stacks of surgical towels. The distance between them was approximately the size of the breadth of the oval swelling. The block supporting the head above the swelling (number 4 in Fig. 3.1) was rectangular



**Figure 2:** MRI brain showing occipital meningoencephalocele.



**Figure 1:** Huge occipital meningoencephalocele in a neonate.



**Figure 3.1:** Schematic representation of Fig. 3.2 1. Rectangular pillow, 2–4. Movable blocks made by surgical sheets, 5. Adjustable gap for occupying huge meningoencephalocele.

and placed in between the two side supports. All these efforts were taken to intubate in supine position and to prevent rupture of meningoencephalocele. A warming blanket was placed over the baby. ECG, NIBP, SPO<sub>2</sub>, ETCO<sub>2</sub>, and Precordial stethoscope were also attached for monitoring. Baseline parameters of the baby were recorded. The baby received Inj. Glycopyrrolate 0.014 mg I.M. as premedication. Baby was induced in supine position (as mentioned earlier) with sevoflurane and Inj. Succinylcholine 7 mg was given after confirming adequate mask ventilation. Laryngoscopy was done and baby was intubated using 3.0 mm inner diameter uncuffed endotracheal tube by consultant anaesthesiologist in first attempt and it was fixed at 9 cm after confirming bilateral equal air entry. Baby received Inj. Atracurium 1.75 mg as loading dose. After proper tube fixation, the baby was made prone with extreme care to prevent accidental extubation. Anaesthesia was maintained using O<sub>2</sub> + N<sub>2</sub>O (50:50) + Sevoflurane (1–2%), Inj. Atracurium 0.5 mg in top ups, Inj. Fentanyl 7 µg which was given to the baby. Before surgery approximately 100 ml of CSF was drained through the swelling with strict vitals monitoring, to facilitate surgical handling and to prevent spontaneous rupture of the cyst. The complete resection of the sac was achieved without any complication. The dysplastic portion of occipital lobe was removed, after which tight dural closure achieved in two layers. Throughout the surgery the total blood loss was 55 ml which was adequately replaced with 55 ml of whole blood. The duration of the surgery was approximately four and half hour. Intraoperative period was uneventful. In view of extensive resection of brain tissue and prolonged duration the decision to electively ventilate the baby was made. After the procedure and after adequate warming, the neonate was shifted to NICU for further monitoring and ventilation. Postoperative on 2nd day the baby was extubated and he was moving all four limbs and later accepting regular feeds. The baby was discharged on 10th postoperative day. At present (postoperative 4 months) baby is doing well without any neurodeficit as seen in neurosurgery OPD follow up.

### 3. Discussion

Meningoencephalocele is hernial protrusion of part of meninges and neural elements in a sac from congenital bony defect. Approximately 75% of the encephaloceles are located in the occipital region. Children with meningoencephalocele are likely to have varying degrees of sensory and motor deficits. Associated congenital defects include club foot, hydrocephalus, exstrophy of bladder (ectopia vesicae), prolapsed uterus, Klippel–Feil syndrome and congenital cardiac defects [3]. Once the decision to operate has been made, a perioperative plan must be formulated by an anaesthesiologist based on airway management, fluid balance and prevention of hypothermia. Major anaesthetic challenge in management of occipital meningoencephalocele is securing the airway [3,4]. Paediatric patients have a low functional reserve volume, and failure to intubate the trachea may result in hypoxaemia, bradycardia and even cardiac arrest. Improper positioning and limited neck extension can make endotracheal intubation difficult or impossible. Mask

ventilation and tracheal intubation can be performed in the lateral position [3,5] or in supine position with sac protected by elevating it, traditionally on a doughnut-shaped support [1]. Alternative approaches such as Mowafi's method can be used [6]. Other method is placing the child's head beyond the edge of the table with an assistant supporting it while another assistant stabilizing the baby's body [7-9]. This method needs at least two assistants. Quezado et al. described simple foam-cushion devices [10]. In this approach, only one person is needed to manage the airway. In our patient the oblong meningoencephalocele which was bigger than the patient's head and was bulged more on one side made the lateral approach difficult and traditional methods such as a doughnut shaped support to the patient's head or an assistant supporting the patient's head brought beyond the edge of the table impractical. The head support we made had movable blocks. So, once the baby was placed on the pillow with the head beyond its edge, we could move each part as necessary so that the head got supported from all sides with the huge swelling in the depression between the blocks. Also, as mentioned above, the side blocks (numbers 2 and 3 in the Fig. 3.1) were made from stacks of surgical towels. So, each stack could be adjusted as required to support the uneven contour of the swelling. So this was the innovative approach of positioning the patient of giant meningoencephalocele for intubation in supine position, made according to the availability of available resources (Fig. 3.2). Needle decompression of encephalocele sac, under sterile precaution, has been proposed as an alternative approach to overcome the difficulties of intubation [7]. However, the resultant rapid decompression of ventricular system may lead to fatal complications such as cardiac arrest owing to traction of cerebral neuronal pathways involving brainstem nuclei. Before administering neuromuscular blocking agents adequate mask ventilation must be verified. We intubated our patient with succinylcholine after confirming stabilization of the head and adequate mask ventilation with patient's body on the pillow and the head placed on the devised support. Although meningoencephalocele can be associated with both upper and lower motor neuron dysfunction, succinylcholine does not elicit a hyperkalemic response. Long acting non-depolarizing muscle relaxants are to be avoided, if surgeon has to use a nerve stimulator to identify functional neural elements. As nerve stimulation was not sought by the surgeon, we maintained relaxation with atracurium throughout the surgery. Children with meningoencephalocele have an increased incidence of latex allergy [11] which can manifest as intraoperative cardiovascular collapse and bronchospasm. Another problem is intraoperative neurological insult which can present with immediate postoperative seizures [12]. Intensive monitoring is required to estimate the blood loss and replace it adequately. Removal of a large quantity of CSF causes volume and electrolyte disturbances which need to be corrected perioperatively. Creighton et al. in a series of 31 patients with occipital encephalocele have observed disturbances in central autonomic control and



Figure 3.2: Arrangement for positioning neonate for intubation

#### H.D. Pahuja et al.

Defective temperature regulation in these children [3]. In infants with encephalocele, dysfunction of autonomic control below the level of the defect makes conservation of body temperature important [13]. Thus attention has to be given to blood loss, maintenance of body temperature, prone position and its associated complications and careful securing of the endotracheal tube [3]. Despite the difficulties, intubation and anaesthetic management in our patient was successfully achieved.

#### 4. Conclusion

Perioperative management of patients with giant meningoencephalocele may be challenging for both anaesthesiologist and neurosurgeon. Managing a case of meningoencephalocele includes looking for other congenital abnormalities, expertise in handling airway, and intraoperative care mainly involving proper positioning, monitoring body temperature and blood loss replacement. These patients must be managed closely with an interdisciplinary approach. Careful planning and perioperative management are essential for successful anaesthetic management of these patients.

#### 5. Conflict of Interest

Authors declare no conflict of interest.

#### References

- [1] Cote Charles J, Miller Ronald D. Miller's Anaesthesia, 7th ed., chapter: 82, Pediatric anesthesia, Churchill Livingstone, 2010, 2589.
- [2] Singh N, Rao PB, Ambesh SP, Gupta D. Anaesthetic management of a giant encephalocele: size does matter. Paed Neurosurg 2012;48:249-52.
- [3] Creighton RE, Relton JES, Meridy HW. Anaesthesiafor occipital encephalocele. Can Anaesth Soc J 1974;21:403-6.
- [4] Singh CV. Anaesthetic management of meningocele and meningomyelocele. J Indian Med Assoc 1980 Sep 16;75(6): 130-2.
- [5] Singh KV, Garasia MB, Ambardekar M, Thota R, Dewoolkar LV, Mehta K. Giant occipital

- meningoencephalocele: anaesthetic implications. Inter J Anesthesiol 2007;13:2.
- [6] Mowafi HA, Sheikh BY, Al-Ghamdi AA. Positioning for anesthetic induction of neonates with encephalocele. Inter J Anesthesiol 2000;5(3). Available at: <<http://www.ispub.com/ostia/index.php?xmlFilePath=journals/ija/vol5n3/enceph.xml>>.
- [7] Walia P, Bhargawa P, Sandhu K. Giant occipital encephalocele. Armed Forces Med J India 2005;61:293–4.
- [8] Goel V, Dogra N, Khandelwal M, Chaudhri RS. Management of neonatal giant occipital encephalocele: anaesthetic challenge. Indian J Anaesth 2010;54:477–8.
- [9] Manhas Yogesh, Chinnan Nevin Kollannoor, Singh Amrit Kumar. Neonatal airway management in occipital encephalocele. Anesthesia & Analgesia 2006;103(6):1632.
- [10] Quezado Z, Finkel JC. Airway management in neonates with occipital encephalocele: easy does it. Anesth. Analg. 2008;107: 1446.
- [11] Moneret-Vautrin DA, Laxenaire MC. Allergic shock to latex and ethylene oxide during surgery for spina bifida. Anaesthesiology 1986;73:556–8.
- [12] Arora Vishal, Zafeer Khan Mohammad, Tripathi RK, Singhal Saurabh, Mishra Saurabh, Chitranshi Shweta. Refractory seizures following encephalocoele surgery. Sch J Med Case Rep 2013;1(3):72–4.
- [13] Hamid RK, Newfield P. Pediatric neuroanesthesia: neural tube defects. Anesthesiol Clin North Am 2001;19(2):219–28.