

Lateral Cervical Mass as a First Sign of Metastases of Occult Thyroid Papillary Carcinoma

Fahd Alharbi^{1,2}, Ohud Alakhrash²

¹Department of Otorhinolaryngology-Head & Neck Surgery, Faculty of Medicine, Jazan University, 2349-Almarjan-Industrial Zone Rd. Unit No. 1, Jazan 82621-7413, Saudi Arabia

²Department of Otorhinolaryngology-Head & Neck Surgery, Prince Mohammed bin Nasser Hospital, Jazan, Saudi Arabia

Abstract: ***Introduction:** The presentation of papillary thyroid carcinoma as a lateral cystic neck mass is uncommon. **Case report:** We report a case of occult papillary thyroid carcinoma, who presented with a lateral cystic neck mass without any goiter. Imaging like ultrasound of neck, computed tomography, failed to detect any lesion in the thyroid. The patient underwent preoperative fine needle aspiration of the lateral neck mass. The cytological examination of the aspiration showed suspicion of vascular lesion. The patient underwent neck exploration and excision of the lateral neck mass. The histopathological examination of the surgical specimen came as a metastatic papillary thyroid carcinoma. The patient underwent total thyroidectomy with bilateral selective neck dissection. **Discussion:** Our case highlights the presentation of metastatic papillary thyroid carcinoma as a lateral neck mass even in a patient without any thyroid lesion or enlargement.*

Keywords: Papillary thyroid carcinoma; metastases; thyroidectomy; neck dissection

1. Introduction

Papillary thyroid carcinoma is the most common and well-differentiated malignant tumor of the thyroid gland. The presentation of papillary thyroid carcinoma as a solitary cystic neck lesion is uncommon (1). Fine needle aspiration cytology is the most important modality for the evaluation of lymphadenopathy. It is highly specific and sensitive in patients with solid lesions. However, for cystic lesions, the absence of epithelium in cyst aspiration may lead to a false negative interpretation of fine needle aspiration cytology results (2, 3). Cystic lymph node metastasis has been detected in 5.2% of malignant aspirates, and the tumor type that most frequently causes cystic change is papillary thyroid carcinoma (PTC) (4).

A lateral cervical cystic lesion mimicking a vascular tumor or branchial cyst can harbor a well-differentiated thyroid malignant tumor metastasis, which is confirmed only after the histopathological examination to reach the correct diagnosis.

In this paper, we discuss a case with a lateral cervical lesion that was initially diagnosed as vascular tumor but after histopathological examination it was diagnosed as lymph node with metastatic papillary thyroid carcinoma.

2. Case Report

A 26-year-old female patient presented to our clinic with a complaint of a neck mass that had enlarged approximately within four months on the left lateral side of the neck. She had no additional complaint. The mass was semi mobile, smooth in consistency, and painless which was located anterior to the left sternocleidomastoid (SCM) muscle. There was no other palpable mass on examination of the neck. Her medical and family histories were unremarkable. Other otolaryngology and endoscopic examinations were normal. Fine needle aspiration biopsy (FNAB) of the mass

was doubtful, and was suggestive of vascular tumor with no malignant cells. There was no palpable mass on the neck of the patient, except that lateral cervical cystic mass in the left side.

Ultrasound (US) examination of the neck showed suspicion of cystic lesion in the left lateral side of the neck with multiple reactive lymph nodes. The thyroid gland examination with US was normal. Contrast enhanced computerized tomography (CT) was also performed and showed cystic mass with multiple reactive lymph nodes and showed no nodule in the thyroid gland Figure 1a, b, c.

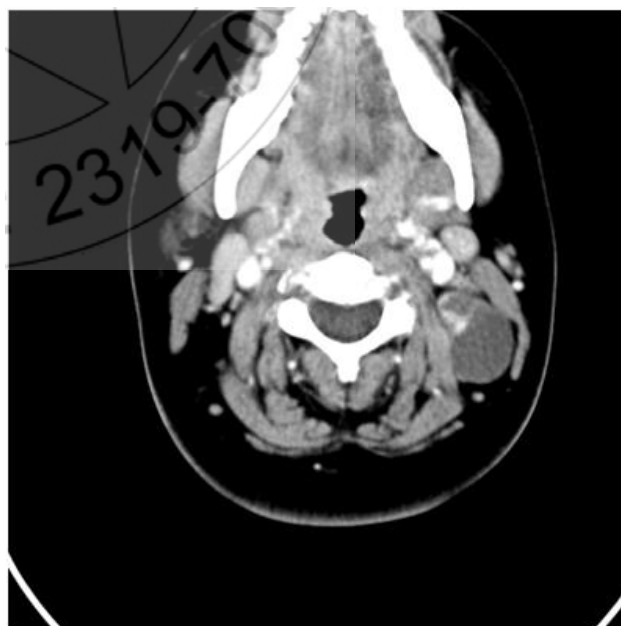


Figure 1 a: Axial CT-scan with contrast showed cystic mass with multiple reactive lymph nodes.

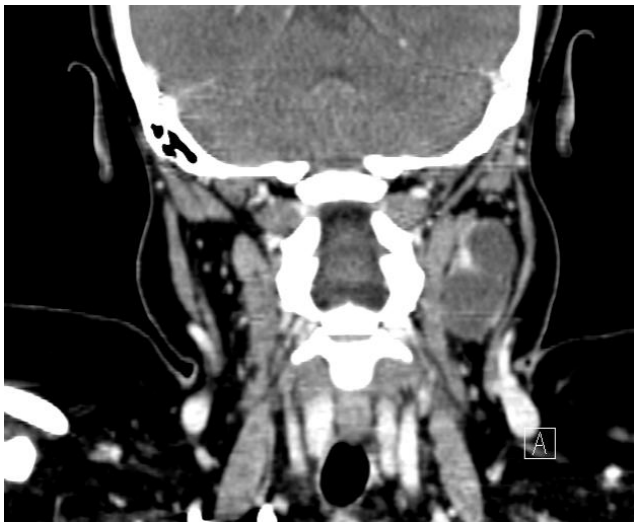

Figure 1 b: Coronal CT scan of the neck with contrast showed cystic mass with multiple reactive lymph nodes

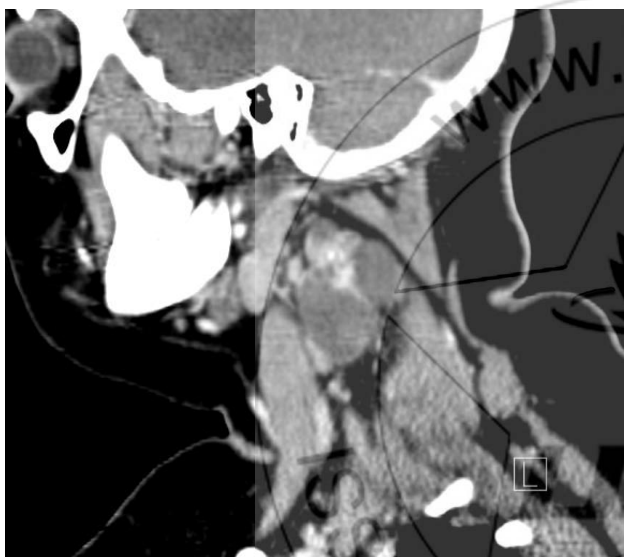


Figure C: Sagittal CT scan of the neck with contrast showed cystic mass with multiple reactive lymph nodes

The patient underwent left lateral neck exploration and excision of the cervical mass and the adjacent lymph nodes. The postoperative histopathological examination of the mass and the lymph nodes revealed a metastatic papillary carcinoma of the thyroid with reactive two lymph nodes with no evidence of malignancy. Thyroid function tests were normal. The patient later underwent total thyroidectomy with bilateral selective neck dissection. The histopathological examination showed papillary thyroid carcinoma of the right thyroid lobe with microscopic metastasis to the right cervical lymph nodes. The patient underwent a radioactive iodine (RAI) ablation therapy 8 weeks after the operation, with planning of thyroid hormone replacement therapy after finishing the RAI.

3. Discussion

Cystic change in metastatic lymph nodes of papillary thyroid carcinoma is considered a diagnostic challenge for fine needle aspiration (FNA) because of the scant cellularity. Thyroglobulin measurement in FNA material appears to be a useful ancillary test that improves the detection of cystic

papillary thyroid carcinoma metastases, and the maximum normal serum-Tg level (77.0 ng/mL) is suggested as the threshold value with a good diagnostic performance for cystic lesions (5)

To minimize the imaging artifact, CT was performed before US guided FNAB. FNAB result was suspicion of vascular tumor. It is concluded in the literature that thyroid nodules can be missed despite performing CT and /or MRI as in our case (6, 7). Thyroid nodules smaller than 1cm in size are mostly non palpable, the gold standard for the thyroid nodule is the thyroid US.

Therefore, thyroid US should be performed in suspected cases (8).

Papillary thyroid carcinoma is the most common type of thyroid cancer (9)

Metastatic lymph nodes do not all carry the same prognostic significance, but a risk assignment based on the American Thyroid Association (ATA) guidelines is limited by a lack of standardization in clinical and pathologic definitions, lymph node sampling, and reporting. The presence of extranodal extension (ENE) increases the risk of recurrence (10).

Thyroidectomy should be performed even if there is no nodule on thyroid imaging to rule out an occult primary tumor in the thyroid gland. RAI ablation is essential part of treatment for well-differentiated thyroid cancer. In Conclusion: lateral neck mass can be the initial presentation of cystic enlarged lymph node due to metastasis papillary thyroid carcinoma in young adult. Ultrasound guided Fine needle aspiration biopsy may be performed for careful examination of all lesions including the thyroid gland. This may lead to a correct initial diagnosis of the lesion.

4. Conflict of Interests

The author declares that there is no conflict of interests regarding the publication of this paper.

References

- [1] Patil M, Kamalanathan S, Sahoo JI, Vivekanandan M, Kate V, Pandit N, Badhe B. Papillary thyroid microcarcinoma in Graves' disease presenting as a cystic neck mass. *J Cancer Res Ther.* 2015 Oct-Dec;11 (4):986-8.
- [2] C. S. Landry, E. G. Grubbs, N. L. Busaidy et al., "Cystic lymph nodes in the lateral neck as indicators of metastatic papillary thyroid cancer," *Endocrine Practice*, vol. 17, no. 2, pp. 240–244, 2011.
- [3] M. Cignarelli, A. Ambrosi, A. Marino et al., "Diagnostic utility of thyroglobulin detection in fine-needle aspiration of cervical cystic metastatic lymph nodes from papillary thyroid cancer with negative cytology," *thyroid*, vol. 13, no. 12, pp. 1163–1167, 2003
- [4] M. Uestuen, B. Risberg, B. Davidson, and A. Berner, "Cystic change in metastatic lymph nodes: a common diagnostic pitfall in fine-needle aspiration cytology," *diagnostic Cytopathology*, vol. 27, no. 6, pp. 387-392, 2002

- [5] Wang Y, Zhao H, Wang YX, Wang MJ, Zhang ZH, Zhang L, Zhang B, Ahuja AT, Zhou CW, Jiang YX, Guo HQ.; Improvement in the Detection of Cystic Metastatic Papillary Thyroid Carcinoma by Measurement of Thyroglobulin in Aspirated Fluid. *Biomed Res Int*. Volume 2016, Article ID 8905916, 6 pages
- [6] H. Seven, A. Gurkan, U. Cinar, C. Vural, and S. Turgut, —Incidence of occult thyroid carcinoma metastases in lateral cervical cysts,” *American Journal of Otolaryngology—Head and Neck Medicine and Surgery*, vol. 25, no. 1, pp. 11–17, 2004.
- [7] S. C. Coleman, J. C. Smith, B. B. Burkey, T. A. Day, R. N. Page, and J. L. Netterville, —Long-standing lateral neck mass as the initial manifestation of well-differentiated thyroid carcinoma,” *Laryngoscope*, vol. 110, no. 2 I, pp. 204–209, 2000.
- [8] D.S. Cooper, G.M. Doherty, B.R. Haugen et al., —Revised American thyroid association management guidelines for patients with thyroid nodules and differentiated thyroid cancer,” *thyroid*, vol. 19, no. 11, pp. 1167–1214, 2009.
- [9] N. D. Goldman, J. U. Coniglio, and S. A. Falk, “thyroid cancer I: papillary, follicular, Hurthle cell,” *Otolaryngologic Clinics of North America*, vol. 29, pp. 593–609, 1996.
- [10] Urken ML, Haser GC, Likhterov I, Wenig B, The impact of metastatic lymph nodes on risk stratification in differentiated thyroid cancer: Have we reached a higher level of understanding? *Thyroid*. 2016 Apr; 26(4): 481-488