

Clinico-Pathological Study of Solitary Thyroid Nodule with Special Reference to Fine Needle Aspiration Cytology

Dr. Shyam Prasad Keshri¹, Dr. Shashi Kumar², Dr. Shiva Thakur³

Abstract: **Introduction:** Nodular goiter is a common endocrine problem in the world today. The primary aim of investigating a thyroid nodule is to look for the possibility of malignant transformation. The objective of the study was to understand the usefulness of FNAC as a diagnostic tool in the evaluation of Solitary nodule of thyroid. **Materials and methods:** Prospective analysis of 50 cases of solitary nodule of thyroid was done. FNAC of the nodule was compared with histopathological examination. **Results:** All cases that were benign on FNAC showed benign features on histopathology also, except in one case, which was a papillary carcinoma. FNAC was significantly associated with histopathology. **Conclusion:** FNAC is an invaluable tool for pre-operative assessment of thyroid lesions, but malignancy can still come as a surprise on postoperative histopathological examination.

Keywords: Solitary thyroid nodule, clinical examination; Fine needle aspiration cytology, Thyroid Carcinoma; management

1. Introduction

The term 'Solitary thyroid nodule' refers to distinct lesion in the thyroid gland that is palpably or radiologically distinct from thyroid parenchyma (discrete thyroid swelling). A discrete swelling in an otherwise impalpable gland is termed as isolated or solitary and discrete swelling in a gland with clinical evidence of abnormality elsewhere in thyroid is dominant nodule. About 70% of discrete thyroid swelling is clinically "isolated" and 30% are dominant. In India the prevalence of a palpable thyroid nodule in the community is about 12.2%. However, thyroid cancer is quite rare, it is the most common endocrine malignancy and the incidence is 8.7 per 100000 people per year in US, though this seems to be increasing over the years. It is therefore crucial to have a clear diagnostic approach to ensure patients, presenting with thyroid nodules, are managed appropriately and are not over or under-treated. Present study is to evaluate FNAC and USG as a diagnostic method in solitary thyroid nodule and to plan surgery accordingly.

2. Materials and Methods

Study Design: This is a prospective comparative study of patients admitted for solitary thyroid nodule at Rajendra Institute of Medical sciences (RIMS) from July 2014 to September 2016.

Source of Data: Patients admitted from opd [outdoor patient department] and central emergency of RIMS surgery department with features of thyroid nodule.

Inclusion Criteria: All patients who admitted with solitary thyroid nodule with age between 11 - 70years.

Exclusion Criteria- (1) Patients with thyroid swellings which are not nodular or multinodular or with dominant nodule. (2) Patients unfit for surgery (3) Patients who fail to give proper history and those without next of kin to consent for the study will be excluded from the study.

Study Tools- (1) Detailed history. (2) Thorough examination (3) Necessary routine. (4) investigation. (5) FNAC of nodule, Ultrasonography of thyroid (6) Treatment modality (7) Histopathology of specimen obtained

3. Results

3.1 Age and Sex of Patients

Table 3: Age and sex distribution

Age (years)	Male (30)	Female (70)	Total (100)
20-Nov	1	8	9
21-30	5	23	28
31-40	10	28	38
41-50	9	6	14
51-60	4	4	8
61-70	1	1	2

- Commonest age group of presentation was 31-40 years, mean age was 35.5 years.
- Ratio of female was 70 %. M: F ratio -1: 2.33.

3.2 Presenting Complaints:

Table 4: Presenting complaints

S. No.	Presenting Complaints	No. of Patients
1.	Swelling in front of lower neck	100
2.	Mild Pain in the swelling	15
3.	Difficulty in breathing	04
4.	Cervical lymph adenopathy	08
5.	History of Change in voice	01
6.	Loss of weight / hyperthyroidism	03
7.	Intolerance to cold / hypothyroidism	02

- All the patients presented with swelling in the front of lower neck (100%).
- On examination 08 (08%) patients had cervical lymphadenopathy.
- 03 Patients had history suggestive of hyperthyroidism and 02 had hypothyroidism.
- 04 patients had history of fever and sore throat.

3.3 Duration of Complaints

Table 5: Duration of Symptoms

S. No.	Duration	No. of Patients n=100
1	< 3 months	6
2	3-6 months	8
3	>6months – 3 years	76
4	> 3 years	10

- The duration of complaints ranged from 15 days to 10 years.
- Majority of the patients (76%) presented between >6 months to 3 years of onset of swelling.
- None of the patients had significant past or family history.

3.4 Clinical Diagnosis

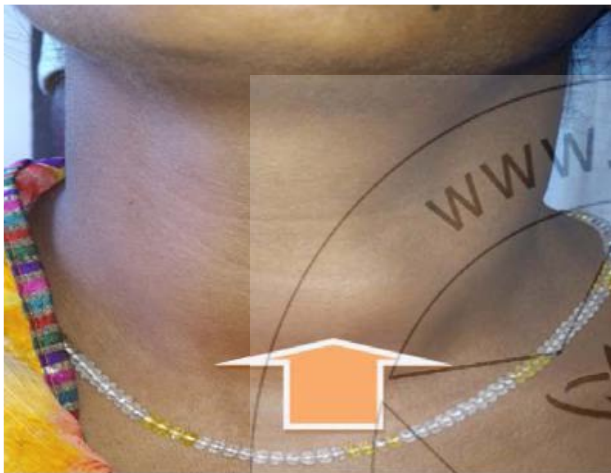

Figure 4: Solitary thyroid nodule

3.5 Fine Needle Aspiration Cytology

Table 6: FNAC report

Category	Classification	FNAC lesion	N=100
Thy 1	Inadequate aspirate(6)		6
Thy 2	Benign (58)	Colloid nodule	25
		Nodular goiter	16
		Benign cystic lesion	13
		Chronic lymphocytic thyroiditis	4
Thy 3	Follicular (18)	Follicular neoplasia	18
Thy 4	Suspicious (06)	Suspicious of malignant papillary neoplasm	6
Thy 5	Malignant (12)	Papillary carcinoma	8
		Medullary carcinoma	3
		Ana plastic carcinoma	1

- On FNAC 58% of nodules were benign and 12% were malignant.
- 3.10% (25) of benign lesion were colloid nodule and 6.90 % (4) were lymphocytic thyroiditis.

3.5 Ultrasonography Report

Table 7: USG report

Category	Lesion	no. of cases n=100
Benign (68)	Cystic	11
	Hyperechoic nodule	43
	MNG	14
Suspicious (06)	Suspicious MNG	3
	Suspicious mixed echogenic	3
Malignant (26)	Mixed , hypoechoic	26

On USG 68% of nodules had features suggestive of benign nodule and 26% were malignant.

3.6 Histopathological Diagnosis

Table 8: HPE report

S. No.	Histopathological diagnosis	n -100
1	Benign follicular adenoma	31
2	Colloid nodule	24
3	Benign cyst	10
4	Hyperplastic nodule	2
6	MNG	8
7	Chronic lymphocytic thyroiditis	4
8	Follicular carcinoma	4
9	Papillary carcinoma	13
10	Medullary carcinoma	3
11	Anaplastic carcinoma	1

- 79 % of clinically diagnosed solitary nodules were benign and 21 % of nodules were malignant.
- So incidence of malignancy in clinically diagnosed solitary thyroid nodule is 21% (100% specific, as on FNAC report)
- Most common benign nodule was benign follicular adenoma (31%), followed by colloid nodule and benign cyst (24% and 10% respectively).

3.7 Correlation of FNAC Lesions with Histopathology

Table 9: Correlation of FNAC lesions with HPE

Category	FNAC lesions	Histopathological diagnosis	n-100
Thy 1 (06)	inadequate aspirate (06)	Benign Follicular adenoma	4
		colloid nodule	2
Thy2 Benign (58)	Colloid nodule (25)	Benign follicular Adenoma	11
		Colloid nodule	21
	Nodular goiter (16)	MNG	8
		Chronic lymphocytic thyroiditis (04)	Benign cyst
Thy3 Follicular (18)	suspicious of malignant papillary carcinoma (06)	Hyperplastic nodule	2
		Lymphocytic thyroiditis	4
		Papillary carcinoma	2
Thy4 Suspicious (06)	Papillary carcinoma (08)	Benign Follicular adenoma	14
		Follicular carcinoma	4
		Benign Follicular adenoma	2
Thy5 Malignant (12)	Medullary carcinoma (03)	Colloid nodule	1
		Papillary carcinoma	3
		Anaplastic carcinoma	1

- All inadequate FNAC were benign on HPE.
- Out of 58 benign on FNAC only 2 (3.44%) turn out malignant on HPE.
- Out of 18 follicular Neoplasia 4 turn out malignant [follicular carcinoma] on HPE, so incidence of malignancy was 22.22% in this group.

- 3 out of 6 report of suspicious lesion turn out malignant, so Incidence of malignancy is 50%.
- All malignant aspirate were malignant too in HPE (100% specific).

3.8 Correlation of Ultrasonography with Histopathology

Table 10: Correlation of Ultrasonography with Histopathology

Category	USG Lesions	Histopathological Diagnosis	N= 100
Benign (n=68)	Cystic (11) Hyperechoic nodule (43) MNG(14)	Benign follicular adenoma	27
		Colloid nodule	21
		Benign cyst	06
		Hyperplastic nodule	02
		MNG	08
		Papillary carcinoma	04
		Suspicious (n=06)	Suspicious MNG Suspicious mixed echogenic
MNG	02		
Papillary carcinoma	02		
Malignant (n=26)	Mixed echogenic and hypoechoic nodule	Papillary carcinoma	07
		Follicular carcinoma	04
		Medullary carcinoma	03
		Anaplastic carcinoma	01
		Benign follicular adenoma	04
		MNG	02
		Colloid nodule	03
		Benign cyst	02

- 4 (5.88%) out of 68 benign Ultrasonography lesion turnout malignant on HPE.
- Incidence of malignancy in suspicious lesion is 33.33% (2/6)

- In total 26 malignant lesion on USG only 15 (57.69%) turn out malignant rest 11 (42.30%) were benign.

3.9 Comparison of FNAC With Histopathology

1. Malignant :

Table 11: Comparison of FNAC with Histopathology

FNAC HPE	Inadequate	Benign	Follicular	Suspicious	Malignant	n
Benign	06	56TN	14	03	00FP	79
Malignant	00	02FN	04	03	12TP	21
Total	06	58	18	06	12	100

Sensitivity: $12/12+2 = 85.71\%$

Specificity: $56/56+0 = 100\%$

PPV: $12/12+0 = 100\%$

NPV: $56/56+2 = 96.55\%$

Sensitivity and specificity of FNAC to diagnose malignant solitary thyroid nodule as 85.71% and 100% respectively

2. Benign:

Sensitivity: $56/56+2 = 96.55\%$

Specificity: $12/12+2 = 85.71\%$

PPV: $56/56+2 = 96.55\%$

NPV: $12/12+0 = 100\%$

Sensitivity and specificity of FNAC to diagnose benign solitary thyroid nodule as 96.55% & 85.71%




Figure 5: Solitary thyroid nodule diagnosed by FNAC

3.10 Comparison of USG with Histopathology

1. Malignant nodule

Table 12: Comparison of USG with HPE

USG \ HPE	Benign	Suspicious	Malignant	Total
Benign	64	04	11	79
Malignant	04	02	15	21
Total	68	06	26	100

Sn: $15/19 = 78.94\%$ **Sp:** $64/64+11 = 85.33\%$
 PPV: $15/15+11 = 57.69\%$ NPV: $64/68 = 94.11\%$

2. Benign nodule

Sn: $64/64+4 = 94.11\%$ **Sp:** $15/26 = 57.69\%$
 PPV: $64/75 = 85.33\%$ NPV: $15/19 = 78.94\%$

Sensitivity and specificity of USG to diagnose malignant solitary nodule are 78.94% and 85.33% respectively.

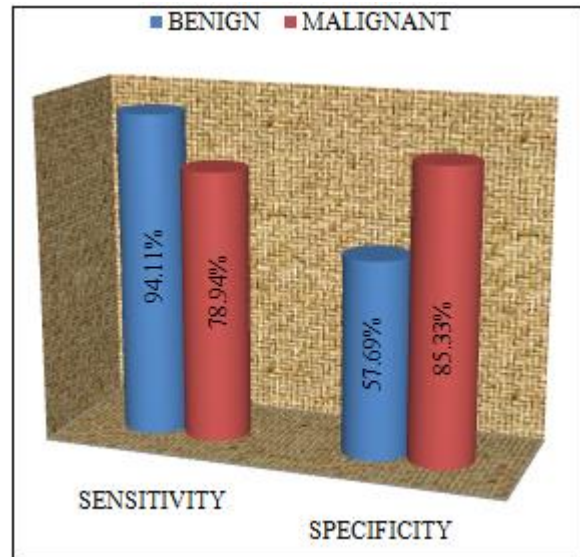


Figure 6: Solitary thyroid nodule diagnosed by USG

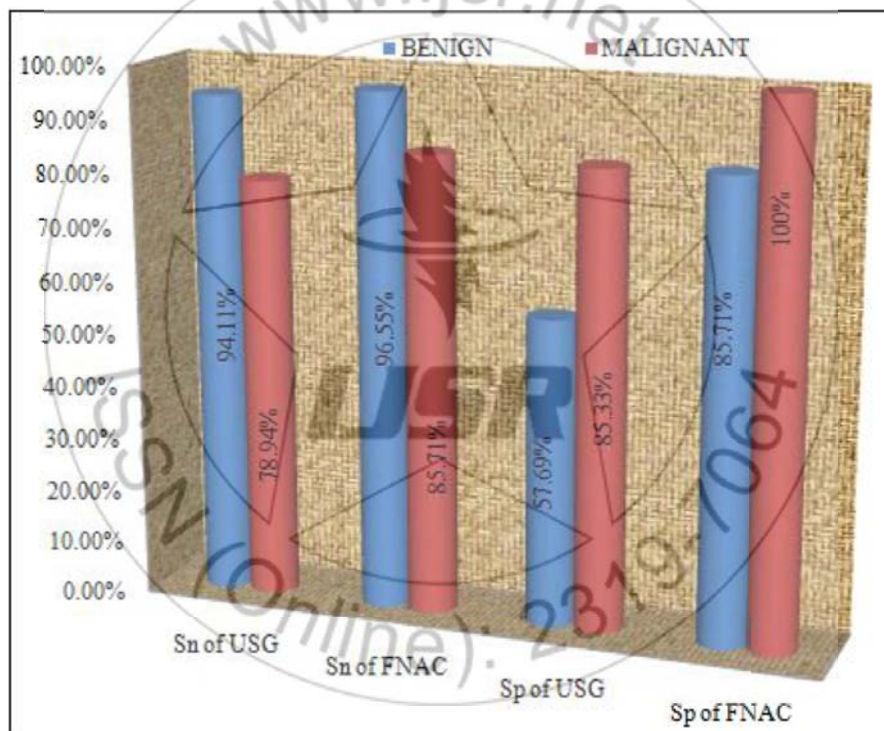


Figure 7: Comparison of FNAC with USG

Specificity of FNAC to diagnose both benign and malignant solitary nodule is higher than USG.

Table 13: Assessment of Nodularity by various methods

Modality	Nodularity	
	Solitary	multiple
Clinical examination	100	00
USG	81	17

Out of total 100 clinically diagnosed solitary thyroid nodule, 17 turn out multinodular on ultrasound. So Incidence of true solitary nodule is only 83%.

4. Surgery Performed on Basis of FNAC Report

Table 14: Surgery performed on basis of FNAC report

S. No.	Type of Surgery	No.
1	Lobectomy	70
2	Subtotal or near total thyroidectomy	9
3	Total thyroidectomy	21
4	Total thyroidectomy with Neck dissection	18

- Most commonly performed surgery was lobectomy (70%), Of all benign lesion of size < 4cm. [lobectomy = 1 total lobectomy + isthmusectomy, 26th edition bailey & love's]

- Subtotal thyroidectomy is performed in benign nodule of larger size (size > 4cm).
- All patient diagnosed as malignant (12) or suspicious of malignancy (6) in FNAC went for total thyroidectomy followed by central or functional neck dissection.
- Central neck dissection was performed in all patients with total thyroidectomy but functional dissection only in case of radiological or clinical evidence of enlarged cervical lymph nodes.
- All 3 patients who diagnosed as nodular toxic goiter also went for total thyroidectomy in view of difficulty in treatment of recurrence.
- All the patient of follicular Neoplasia went for Lobectomy and only 4 patients went for total thyroidectomy after 8 wks of 1st surgery due to malignant HPE report.

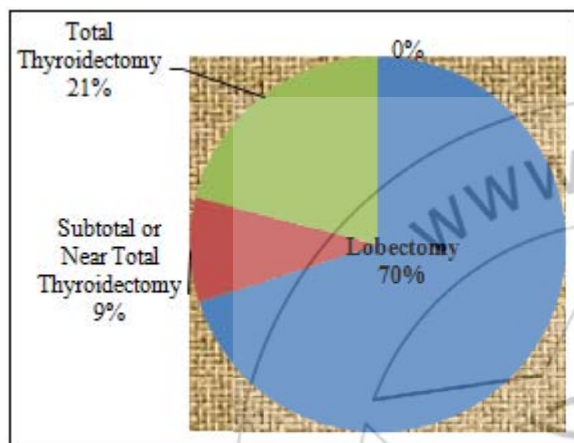


Figure 8: Surgery Performed

Postoperative Complication

- Except the transient hypocalcaemia and transient voice changes no other major complication noted.

Follow Up

- No any complication noted during follow up period.

5. Discussion

Pathogenesis of Thyroid Nodule

The normal thyroid is impalpable. The term goiter is used to describe generalized enlargement of the thyroid gland. A discrete swelling (nodule) in one lobe with no palpable abnormality elsewhere is termed an isolated (or solitary) swelling. Discrete swelling with evidence of abnormality elsewhere in the gland is termed dominant.

Stages

- Persistent growth stimulation causes diffuse hyperplasia; all lobules are composed of active follicles and iodine uptake is uniform. This is a diffuse hyperplastic goiter, which may persist for a long time but is reversible if stimulation ceases.
- Later, as a result of fluctuating stimulation, a mixed pattern develops with areas of active lobules and areas of inactive lobules. Active lobules become more vascular and hyperplastic until hemorrhage occurs, causing central necrosis and leaving only a surrounding ring of active follicles. Necrotic lobules coalesce to form nodules filled

either with iodine-free colloid or a mass of new but inactive follicles.

- Continual repetition of this process results in a nodular goiter. Most nodules are inactive, and active follicles are present only in the internodular tissue.

Risk of malignancy in thyroid swellings

The risk of cancer in a thyroid swelling can be expressed as a factor of 12. The risk is greater in isolated vs. dominant swellings, solid vs. cystic swellings and men vs. women.

Factors Suggesting Increased Risk of Malignant Potential

- 1) History of head and neck irradiation
- 2) Family history of medullary thyroid carcinoma, multiple endocrine neoplasia type 2, or papillary thyroid carcinoma
- 3) Age < 14 or > 70 years
- 4) Male sex
- 5) Growing nodule
- 6) Firm or hard
- 7) consistency
- 8) cervical adenopathy
- 9) Fixed nodule
- 10) Persistent dysphonia, dysphagia, or dyspnea

6. Clinically Suspected Solitary Thyroid Nodule

Thyroid nodules are a common problem. They are found in 4-8% of adults by population and 16-17% when ultrasound detection is used. In autopsy studies, they have a prevalence of approximately 50%. The prevalence of thyroid nodules increases with age and women have a high prevalence than men. The natural history of benign nodules is unclear, but most palpable nodules reduce in size, with up to 38% disappearing altogether. Sometimes this clinically palpated solitary thyroid nodule may be part of a diffuse multinodular disease group. This forms the most important indication for the use of ultrasound in thyroid pathologies i.e. to prove beyond doubt the presence of a solitary nodule. Solitary nodules presented a higher but not significantly risk of cancer as opposed to lesions embedded in multinodular goiter. Available data suggest that approximately of these solitary nodules 5% are toxic, 10% are warm and 85% are cold. The common indication for the use of ultrasound lies in the fact that:

- 1) It helps to discriminate pure solitary lesions from a spectrum of multinodular goiter. In one series of 98 patients Scheible et al reported that of 73 patients with a solitary lesion checked by palpation and a radionuclide scan, 29 patients had a second lesion, and two had a solitary lesion in a location other than that which was originally suspected.
- 2) Ultrasound excels at differentiating the purely cystic lesion from the mixed or solid lesions with a reported accuracy of 95 to 100%. This is important because elucidation of a simple cyst less than 4 Cm in diameter is virtually diagnostic of a benign disease with an accuracy of 98%.
- 3) Ultrasound is able to define the halo sign around the solitary nodule. Earlier this seemed to be a reliable sign of a benign adenoma or an adenomatous nodule.

This was until Proper and co-workers reported the first two cases with a halo sign which proved to be carcinomas. With the advent of very high-resolution ultrasound scanners some new facts have come to light. It is now said that 90% of all echo poor solitary lesions are either malignancies (papillary/medullary or anaplastic) or they can be adenomas (nonfollicular). Thus all focal solitary lesions warrant biopsy⁵⁶. It is stated that, the presence of micro calcifications less than 2 mm in diameter are seen in 75% of papillary and medullary cancers and is considered a reliable sign of malignancy on ultrasound. The reliable indicator of malignancy in solitary lesions is the evidence of infiltration of structures around the thyroid and metastasis to cervical lymph nodes. Ultrasound is able to show these features both earlier and with more certainty. Cervical lymph node metastases are associated in about 20% of papillary and medullary carcinomas at the time of presentation⁵⁷. Another study of 299 patients by Diggot J D et al who were operated for solitary thyroid nodules. The overall incidence of cancer in by these was only 5.70/0 (17 cases). The female to male ratio was 8: 1 with the average age of 42.3 years. A bimodal curve showed an increase in the incidence of cancer in the very young and old.

A twenty year experience of thyroid cancers between 1953 and 1973 was reviewed. According to this study by D J Campell et al only 8 out of 293 cases of solitary thyroid nodules were malignant, an incidence of only 2.7%. In one series of 200 patients of solitary thyroid disease the incidence of malignancy was in only 8 cases and all of these 8 were solid lesions on ultrasound .In one study of 72 patients of solitary nodules by Brander A et al, only one third of the clinically solitary- nodules proved to be solitary by ultrasound examination. Of 77 separate nodules 43 escaped detection on clinical examination. In the study of Jones A J et al the sensitivity, specificity and positive predictive value of FNAC, radioisotope scan and ultrasound was evaluated for thyroid cancer in solitary nodules. For FNAC it was 92%, 85% and 41% respectively. For ultrasound it was 75%, 61.1 % and 19% while for radioisotope scanning it was 82%; 34% and 11 % respectively. The combined result of ultrasound and radionuclide scan was 82%, 34% and 11 %. In one study of solitary nodules by Serga A et al only 64.3% of the carcinomas exhibited the typical malignant pattern on ultrasonography and in 21.4% of the carcinomas a homogenous nodule with a clear margin was observed which was often observed in benign nodules also.

In the present study age of the patient ranged from 11-70 years with a median age of 35.5 years. Age distribution of the present study is comparable to Jose RJ et al.

Table 15: Age range and median age of different studies

Authors	Range of age	Median age
Tabaqchali et al (2000)	8.5-85	48
Jose R J et al (2002)	17-65	35.5
Afroze N et al (2002)	16-78	40.2
Sekhri et al (2001)	9-70	33.9+11
Mitra R B et al (2002)	16-70	39.6
Present study	11-70	35

The number of males in the present study was 30(30%) and the females were 70 (70%) with a male to female ratio of 1:2.33. Sex distribution was similar when compared to Afroze et al

Table16: Sex distribution and male to female ratio in different studies

Series	Total cases	Male	Female	M:F Ratio
Sekhri T et al(2001)	300	44	256	1:6
Tabaqchali et al(2000)	239	26	213	1:8.2
Popivanov et al(2000)	175	10	165	1:16.5
Jose RM et al	98	16	82	1:5.1
Afroze et al(2002)	170	48	122	1:2.54
Presentstudy	100	30	70	1:2.33

The commonest clinical presentation is the presence of swelling in front of the neck and majority presented between 6 months to 3 years.

Table 17: Comparison of FNAC results

Study	Sensitivity (%)	Specificity (%)
Goellner et al	98	99
Cai et al	83.5	98
Morgan et al	55.0	73.7
Altavilla et al	71.43	100
Kim et al	85.7	100
Carol et al	86	81
Fazal et al	88.09	77.43
Malignant	85.71	100
Present study		
Benign	96.55	85.71

The overall sensitivity in our series was 85.71% & 96.55 %, while the specificity was 100% \$ 85.71 % for both malignant and benign lesions which is comparable to study done by kim et al . FNAC has certain limitations because of suspicious diagnosis. In present series out of 6 (6%) suspicious lesion on FNAC , 3 were found to be malignant on final HPE report so , incidence of malignancy in this group is 50% . Due to high level of malignancy ,surgery like total thyroidectomy is justifiable on basis of FNAB report . The overall incidence of malignancy in solitary thyroid nodules varies from 10%-30% according to various studies. In our study, the overall incidence of malignancy in solitary nodule was 18%.

The thyroid nodules on USG were subdivided in to 3 groups-benign, suspicious and malignant on the basis of various sonographic features. Features suggestive of malignancy on USG are-hypoechoic pattern, incomplete peripheral halo, irregular margins, internal micro calcification, increased vascularity, presence of cervical lymphadenopathy and peripheral degeneration in mixed nodules. Features suggestive of benign diseases on USG are-halo sign (transonic uniform rim surrounding the mass), variable echogenecity, multinodularity, large cystic lesion, diffusely nodular in homogenous gland and peripheral calcification.

In our study, out of 26 cases diagnosed to be malignant on USG, 15 cases were confirmed on histopathology and remaining 11 cases were differed to be benign. In 7 cases in whom USG gave false negative diagnosis of benign disease, histopathology revealed papillary carcinoma.

The overall sensitivity in our series was 78.94 % & 94.11 %, while the specificity was 85.33% & 57.69 % for both malignant and benign lesions on USG.

Table 18: Comparison of USG results

Series	Sensitivity (%)	Specificity (%)
Watters et al.	74	83
Jones et al.	75	61
Ajith et al	20	97.6
Malignant	78.94	85.33
Present study	94.11	57.69
Benign		

Watter et al, interpreted an USG report as suggestive of malignancy if the nodule was solid or of a mixed-solid-cystic variety and a hypoechoic and nonhaloed lesion. They emphasized that the USG has added advantage of allowing the whole gland to be examined rather than the dominant nodule but was limited by the fact that no features were Pathognomic for malignancy, so that it should be regarded as complementary rather than an alternative investigation to FNAC in the management of solitary thyroid nodule. It has been a consistent observation according to published literature, that the risk of thyroid cancer is less with multiple nodules than with the solitary nodules. High resolution real-time USG is far better than clinical examination in detecting thyroid nodularity. Watter et al have shown that the prevalence of multinodularity in clinically solitary thyroid nodules is between 20% and 40%, and it has been observed that for a thyroid nodule to be detected by palpation, it must be at least 1 cm in diameter, while USG detects nodules as small as 3mm in diameter. In present series incidence of

multinodularity in clinically dignosed solitary nodule is 17%.

7. Management of Thyroid Nodules

Indications for operation in thyroid swellings

1. Neoplasia (FNAC positive, clinical suspicion)
 - (a) Age
 - (b) Male sex
 - (c) Hard texture
 - (d) Fixity
 - (e) Recurrent laryngeal nerve palsy
 - (f) Lymphadenopathy
 - (g) Recurrent cysts
2. Toxic adenoma
3. Pressure symptoms
4. Cosmesis
5. Patient's wishes

The types of thyroid operations can be assembled from 3 basic elements

1. Total lobectomy
2. Isthmusectomy
3. Subtotal lobectomy

Total thyroidectomy = 2x Total lobectomy + Isthmusectomy

Subtotal thyroidectomy = 2x Subtotal lobectomy + Isthmusectomy

Near total thyroidectomy = Total lobectomy + Isthmusectomy + H- subtotal lobectomy

Lobectomy = Total lobectomy + Isthmusectomy

Table 19: Role of different thyroid operations in relation to presenting condition

Procedure	Multinodular goiter	Isolated or dominant Swelling	Graves disease
Total thyroidectomy	Risk of Hypoparathyroidism	Known to be PCT or FCT and in risk group or MCT	If small gland and young patient risk of hypoparathyroidism
Subtotal thyroidectomy	Best prospect of long term euthyroidism	No	Best prospect of long term euthyroidism
Near total thyroidectomy	Risk of re growth and difficult reoperation	Known to be PCT or FCT and in risk group or MCT	Easier to estimate remnant size after one subtotal thyroidectomy
Lobectomy	If confined to one lobe	Diagnosis benign or uncertain or if PCT or FCT in lower risk group	NO

8. Management of Solitary Thyroid Nodules

Surgical excision based on clinical indicators:

The following clinical factors may warrant surgery despite an FNA that is reported as 'benign' or 'non-diagnostic':

- (1) Age extreme (younger than 20 or older than 45);
- (2) Male sex;
- (3) Nodules that occur in patients with Grave's

disease or Hashimoto's thyroiditis; (4) Previous radiation to the cervical region; (5) Strong family history of thyroid cancer; (6) Pain; (7) Compressive, infiltrative/invasive features; (8) Cervical metastasis; (9) Large nodule (>4cm); (10) Rapid growth; and (11) Growth despite thyroid suppression therapy.

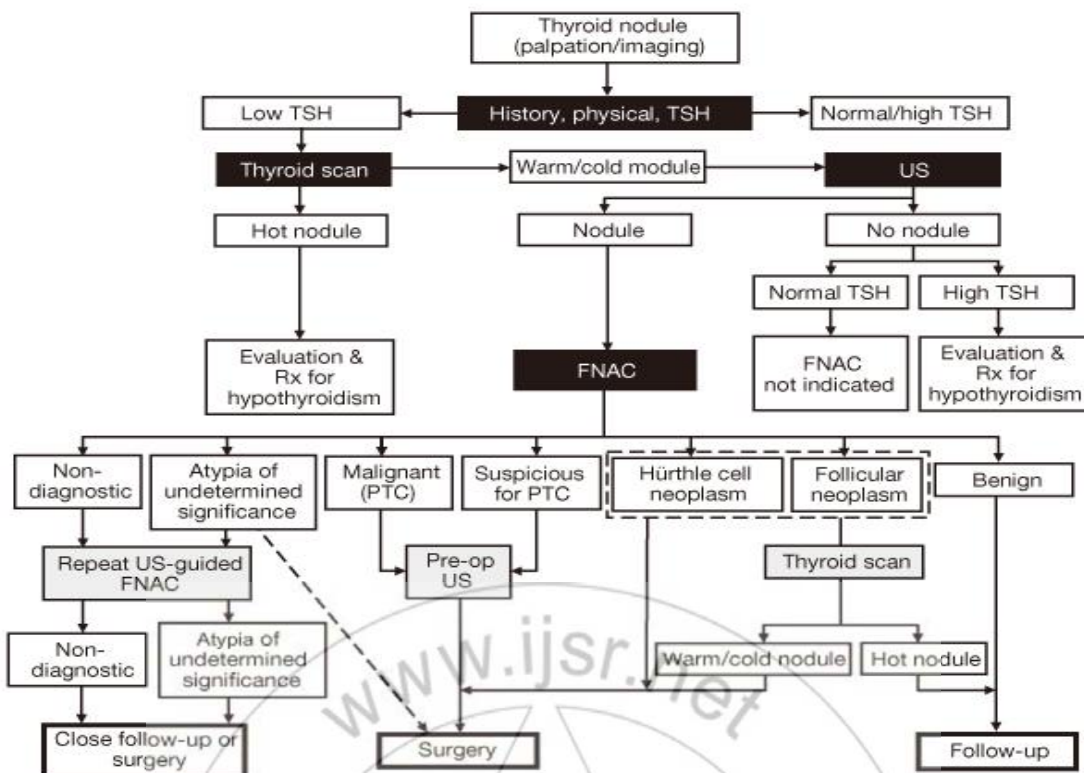


Figure 9: Management algorithm of a solitary thyroid nodule based on FNA results

The natural history of FNA 'benign' nodules is unpredictable, and therefore, close observation is recommended. Although yearly follow up with or without USG is probably sufficient, some nodules may warrant further work up when poor clinical indicators are present.

Thyroid suppressive therapy: Several series were conducted to determine the benefits of T4 suppressive therapy of patients with benign solitary nodules. Gharib and Mazzaferri reviewed the literature and concluded that because only 10%-20% of patients respond to suppressive therapy, benign solitary nodules are best followed without suppression, thus avoiding potential complications of long term therapy.

The management of FNA 'malignant' nodules is more straight forward because the predictive value of malignancy in FNA is close to 100% with a specificity also close to 100%. Surgical excision is warranted for 'malignant' nodules.

For the FNA 'suspicious' lesions, literature strongly suggests the need for surgical management. The last category of a FNA result is the 'non-diagnostic' or 'insufficient' for diagnosis reading, a repeat FNA is performed, possibly with ultrasound guidance to increase the yield. The clinical follow up, with surgical intervention only when poor prognostic indicators were present was acceptable.

Table 20: AACE/AME/ETA Classification for Cytologic Diagnosis of Thyroid Nodule and management²⁰

Class	Diagnostic Category	Suggested Action
Class 1	Nondiagnostic (inadequate /insufficient)	Repeated US-guided FNA biopsy, unless pure cyst Class
Class 2	Benign (non-neoplastic)	Clinical and US follow-up FNA biopsy repetition if nodule size increases or according to clinician's or cytopathologist's judgment
Class 3	Follicular lesion/neoplasm	Surgery for most Frozen section usually not recommended In some cases follow-up on the basis of a multidisciplinary team evaluation
Class 4	Suspicious	Surgery Frozen section recommended Repeated FNA biopsy only if more material is needed
Class 5	Positive for malignant cells	Surgery for differentiated carcinomas Further diagnostic workup for anaplastic carcinomas, lymphomas, and metastatic lesions

Abbreviations: AACE, American Association of Clinical Endocrinologists; AME, Associazione Medici Endocrinologi; ETA, European Thyroid Association; FNA, fine-needle aspiration. This proposed classification is based on the results of the British Thyroid Association Thyroid Cancer Guidelines (2002-2006) (62) and the Italian SIAPEC-IAP Working Group for the Consensus on Classification of Thyroid Cytology (2008) (63).

Postoperative Complications⁴²

In a well managed thyroid patient, the postoperative complications are uncommon. But when they occur, they may prove to be quite dangerous.

They are

- 1) Hemorrhage
- 2) Respiratory obstruction
- 3) Recurrent laryngeal nerve injury
- 4) External laryngeal nerve injury
- 5) Homer's Syndrome
- 6) Thyroid insufficiency
- 7) Parathyroid insufficiency
- 8) Thyroid storm (thyroid crisis)
- 9) Wound infection
- 10) Keloid of the scar
- 11) Stitch granuloma
- 12) Recurrence of the tumour

9. Conclusion

The present study was undertaken to evaluate the usefulness of clinical examination, FNAC and USG of thyroid in the management of solitary thyroid nodule and to know the sensitivity and specificity of the investigations by comparing with histopathological report.

- 1) Thyroid nodules are common in females of age group 31 to 40 years.
- 2) Commonest presenting complaint is swelling in the front of lower neck.
- 3) Most of the patients presented between 6 months to 3 years of onset of swelling.
- 4) In our study, the sensitivity and specificity of FNAC was 85.71% and 100% respectively. All malignant lesions on FNAC were confirmed by histopathology indicating its excellence. Therefore FNAC helps in planning the correct management and avoids second surgery.
- 5) In our study, the sensitivity and specificity of USG was 78.94 % and 85.33% respectively. Therefore use of ultrasound along with FNAC will improve the diagnostic accuracy to higher level and help in better management.
- 6) Minimal surgery is lobectomy. This was undertaken in all cases, which help in establishing the histopathological diagnosis and in comparing the efficacy of above investigations.
- 7) The ideal test should have a sensitivity and specificity of 100%. The closest method to ideal test is, thus, FNAC which has high sensitivity and specificity. However, a combination of both FNAC and Ultrasound will give optimal results and avoid mismanagement.

References

- [1] Yeung MJ, Serpell JW. Management of the solitary thyroid nodule. *Oncologist*. 2008;13:105-12. [PubMed]
- [2] UshaMenon V, Sundaram KR, Unnikrishnan AG, Jayakumar RV, Nair V, Kumar H. High prevalence of undetected thyroid disorders in an iodine sufficient adult south Indian population. *J Indian Med Assoc*. 2009; 107:72-7. [PubMed]
- [3] Davies L, Welch HG. Increasing Incidence of Thyroid Cancer in the United States, 1973-2002. *JAMA*. 2006; 295:2164-7. [PubMed]
- [4] Jhon B Hanks, Thyroid. *Sabiston Textbook of surgery: the biological basis of Modern Surgical Practice Vol 1*, 18th. Saunder's Elsevier publishers; 2004: 947-983.
- [5] Gregory P Saddler, Orlo H Clarke, Jon A, Van Heerder. *Schwartz- Principles of Surgery*, 7th edition. Mcgraw hill; 1999:36: 1661-1711.
- [6] Skandalakis JE, Gray SW (eds). *Embryology and anatomy for surgeons*, 2nd ed. Baltimore: Williams & Wilkins, 1994.
- [7] Inderbir Singh B, Pal J P. *Embryology of thyroid gland*. *Text book of Embryology* ; 2000 :30- 40.
- [8] *Grays anatomy 38th edition: The Thyroid gland*.
- [9] Gregory p. Sadler and Nicholas Dudley. *The thyroid gland chapter 20.2.2*. In: Peter J. Morris and William C. Wood, editors. *Oxford textbook of surgery .2nd edition vol 2*. New York. Oxford University Press; 2000: page no: 1100.
- [10] Decker G A, Pleiss D J. *The Thyroid, Thymus and the Parathyroid gland*. *Lee McGregors Synopsis of Surgical Anatomy*. 17 12th edition: 1996:198- 205.
- [11] Miller F R, Netterville J L. *Surgical management of Thyroid and Parathyroid disorder Med Clin North Am* 1999; 83:247-259.
- [12] Hooper M, Thyroid, Jamieson and Kay's: *Textbook of Surgical Physiology*. 4th edition; Churchill Livingstone; 1990:7:85-107.
- [13] Anna L B. *Thyroid physiology and Thyroid function testing*, *Disorders of Thyroid*. *Otolaryngol Clin N Am* 2003; 36:9-15.
- [14] Gharib H, Papini E. *Thyroid nodules: Clinical importance, assessment and treatment*. *Endocrinol Metab Clin North Am* 2007; 36:707-73.
- [15] Larry J, Anthony P Weetman. *Disease of Thyroid gland*, *Harrison's Principles of Internal Medicine Vol 2*. 16th edition 2005; 2104-2125.
- [16] Kaye TB: *Thyroid Function Tests: Application of newer methods*. *Post Grad Med*; 2003: 9481: 87-90.
- [17] American Association of Clinical Endocrinologists and medical guidelines for clinical practice for the diagnosis and management of thyroid nodules *Endocr Pract* 2006, 12:63-102.
- [18] Goudy SL, Flynn MB: *Diagnostic accuracy of palpation-guided and imageguided fine-needle aspiration biopsy of the thyroid*. *Ear Nose Throat J* 2005, 84:371-374.
- [19] Hales M S, Hsu FS. *Needle tract implantation of papillary carcinoma of the thyroid following aspiration biopsy*. *Acta Cytol* 2002; 34: 801.
- [20] American Association of Clinical Endocrinologists and medical guidelines for clinical practice for the diagnosis and management of thyroid nodules: *AACE/AME/ETA Thyroid Nodule Guidelines*, *Endocr Pract*. 2010; 16 (Suppl 1); 1-43.