

Mediastinal Paraganglioma: A Challenge to a Radiologist in a Non Functional Paraganglioma

Zalak Patel¹, Yashpal Rana², Megha Sheth³, Dinesh Patel⁴, Samir Patel⁵, Millin Garachh⁶

^{1, 2, 3, 4, 5, 6}Faculty, Department of Radiology, U.N. Mehta Institute of Cardiology and Research Center

Abstract: *Mediastinal paragangliomas are rare tumours derived from chromaffin cells (neuroectodermal cells) associated with sympathetic ganglion of the autonomic nervous system arising from two major location near paraaortic (aorticopulmonary) and paravertebral (aortic sympathetic) region. It is highly important to suspect paraganglioma whenever vascular lesion is noted in middle or posterior mediastinum on imaging. Majority of cases present with episodic palpitation, hypertension, sweating or symptomatology due to mass effect in case of non functional paraganglioma. Management is usually surgical and it's a challenging due to vascular nature of lesion particularly in case of non functional paraganglioma. Imaging modality is helpful to identify feeding vessel so that preoperative embolization can be performed to minimize bleeding.*

Keywords: Mediastinal paraganglioma, CT angiography, hypervascular tumor, avoid FNAC

1. Introduction

Mediastinal paragangliomas are rare tumours derived from chromaffin cells (neuroectodermal cells) associated with sympathetic ganglion of the autonomic nervous system. They can arise from two major cluster of sympathetic ganglion cells: paraaortic (aorticopulmonary) and paravertebral (aortic sympathetic) location.¹ They are vascular tumours derived from chromaffin cells associated with sympathetic ganglion of the autonomic nervous system. Common locations include abdominal paraaortic bodies, carotid body, nodose ganglion of the vagus nerve, glomus bodies in the region of the jugular foramen and cochlear promontory.² Most of the functional mediastinal paragangliomas were noted during the investigation of hypertension or other symptoms secondary to catecholamine excess. Non-functional mediastinal paragangliomas are noted incidentally and the diagnosis is confirmed postoperatively. Mediastinal paragangliomas are hypervascular tumors and many of them directly invade or firmly adhere to the adjacent mediastinal organs, such as the heart, great vessels, the trachea and the spine.^{1,3}

2. Case Report

A 50-year-old previously healthy man presented with intermittent history of chest pain, patient was sent to radiology department for CT coronary angiography. Patient have not had any other symptoms, such as headache, palpitations or sweating, and had no other significant past medical or travel history. Physical examination and laboratory data were all normal.

Doing CT coronary angiography, A large incidental middle mediastinal mass was suspected. The mass lesion was approx. 7.4 x 6.3 x 5.4 cm (TR X AP X CC) in size, showed heterogeneously per enhancement. The mass was located in middle mediastinum between left pulmonary artery and left atrium. Fat plane with left atrium and LPA was preserved. No evidence of intralesional calcification noted. Few tiny non-enhancing necrotic areas noted within. Hyperdynamic enhancement continuing from the early to delayed phase was

seen. Arterial supply to mass lesion is from branches of RCA, LCx as well as from aortic branches.

From CT findings paraganglioma was suspected and so FNA was avoided and patient was scheduled for surgery.

The tumour was fortunately non-functional without any complications related to catecholamine release. The patient underwent subsequent successful surgical resection.

Post operatively patient was sent for follow up CT thorax study, which shows complete resection of mass lesion with reduction of mass compression symptoms.

3. Discussion

Most paraganglioma occurs sporadically in the 3rd to 5th decade. Although usually intra-abdominal, up to 15% may occur in the intrathoracic region as seen in this case. These tumors are usually solitary and grow slowly to reach several centimeters in size where they may cause symptoms from mass effect. These lesions are usually solid but can undergo cystic degeneration. Mediastinal lesion may show associated superior vena caval obstruction as manifested by "downhill" varices.

On CT scan imaging mediastinal hemangioma and focal castleman's disease (angiofollicular lymph node hyperplasia) should be considered as differential based on location and contrast enhancement pattern.⁶

Functional paragangliomas can be diagnosed with measurement of fractionated catecholamines and metanephrines; mediastinal localization is determined with appropriate scanning techniques like CT angiography or MRI study. These tumors can be treated successfully by surgical resection with modest surgical risk, often necessitating cardiopulmonary bypass, with good long-term survival.⁴

Management is surgical and frequently challenging due to the vascular nature of lesion. Preoperative embolization of feeding vessels may be performed to minimize the risk of intraoperative bleeding.⁵

4. Conclusion

Non functional paraganglioma can be a challenge to a radiologist. Its highly important to suspect paraganglioma whenever vascular lesion is noted in middle or posterior mediastinum on imaging near paraaortic (aorticopulmonary) and paravertebral (aorticosympathetic) location because it is one of the few exceptions when FNA may pose a serious and unexpected risk. CT angiography may reveal feeding vessels in many cases, so that preoperative embolization can be done to minimize the intraoperative bleeding risk. Functional paraganglioma is comparately easy to locate and diagnose by imaging modality.

References

- [1] Journal of Cardiothoracic Surgery 2010 5:19, DOI: 10.1186/1749-8090-5-19- Paraganglioma of mediastinum.
- [2] Young WF: Paragangliomas: clinical overview. Ann N Y Acad Sci. 2006, 1073: 21-29. 10.1196/annals.1353.002.
- [3] Balcombe J, Torigian DA, Kim W, Miller WT: Cross-sectional imaging of paragangliomas of the aortic body and other thoracic branchiomericparaganglia. AJR Am J Roentgenol. 2007, 188: 1054-1058. 10.2214/AJR.05.1497.
- [4] Oxford Journals, Interactive CardioVasc Thoracic Surgery, Volume 9, Issue 3- Non functionalparaganglioma.
- [5] Paraganglioma of the posterior mediastinum: a case report and review of the literature. J Pediatric Surg 2003;38:1114-1116.

- [6] Mediastinal paraganglioma- Dr Yuranga Weerakkody and Dr Charlie Chia-Tsong Hsu et al. Radiopedia.org

Authors Profile

Dr Zalak Patel, finished MBBS and MD Radiology from B. J. Medical College, Civil Hospital, Ahmedabd. Presently working as faculty at U. N. Mehta Institute of Cardiology and Research Center, Ahmedabad, Gujarat, India.

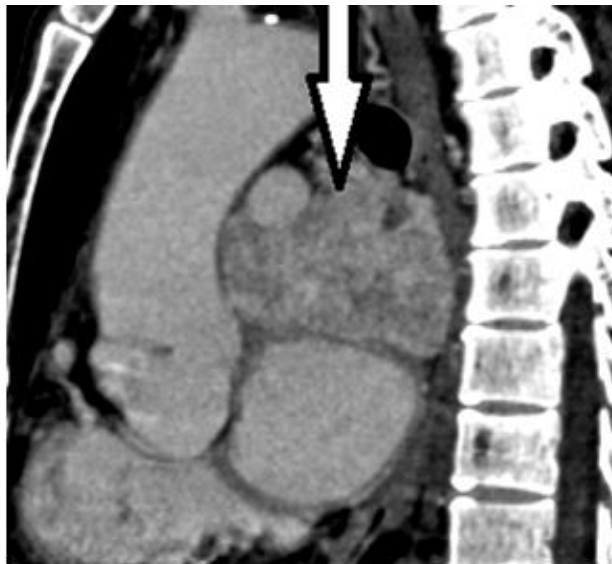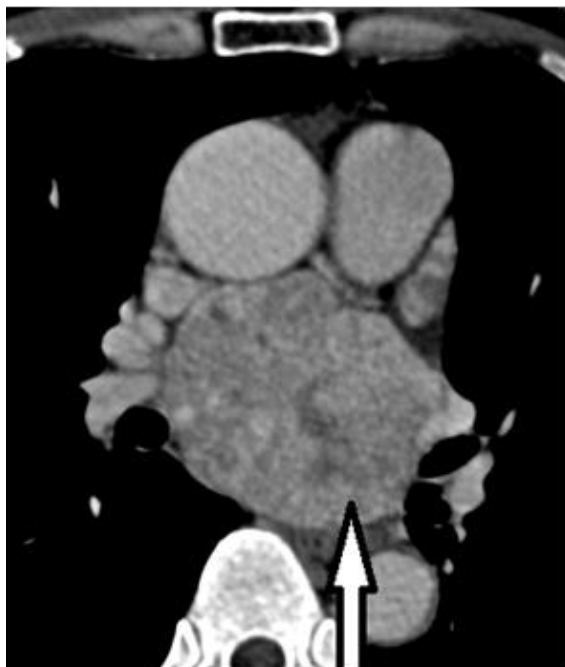Dr Yashpal Rana, finished MBBS and MD Radiology from B. J. Medical College, Civil Hospital, Ahmedabd. Presently working as faculty at U. N. Mehta Institute of Cardiology and Research Center, Ahmedabad, Gujarat, India.

Dr MeghaSheth, finished MBBS and DMRD Radiology from B. J. Medical College, Civil Hospital, Ahmedabd. Presently working as faculty at U. N. Mehta Institute of Cardiology and Research Center, Ahmedabad, Gujarat, India.

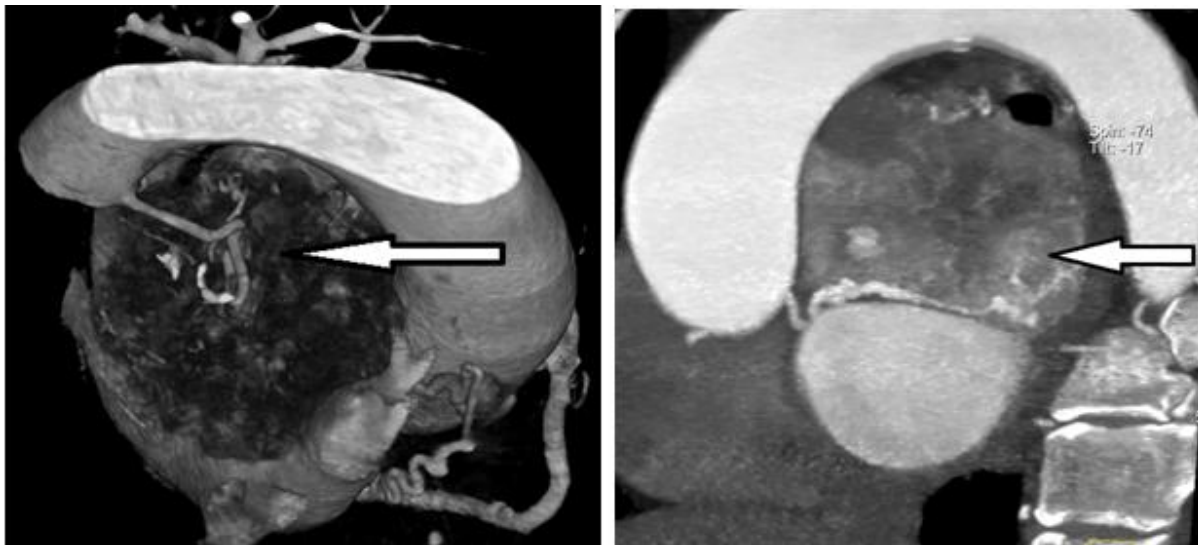
Dr Dinesh Patel, finished MBBS and DMRD Radiology from B. J. Medical College, Civil Hospital, Ahmedabd. Presently working as Assistant Professor and Head of Department of Radiology at U. N. Mehta Institute of Cardiology and Research Center, Ahmedabad, Gujarat, India.

Dr Samir Patel, finished MBBS and DMRD Radiology from B. J. Medical College, Civil Hospital, Ahmedabd. Presently working as faculty at U. N. Mehta Institute of Cardiology and Research Center, Ahmedabad, Gujarat, India.

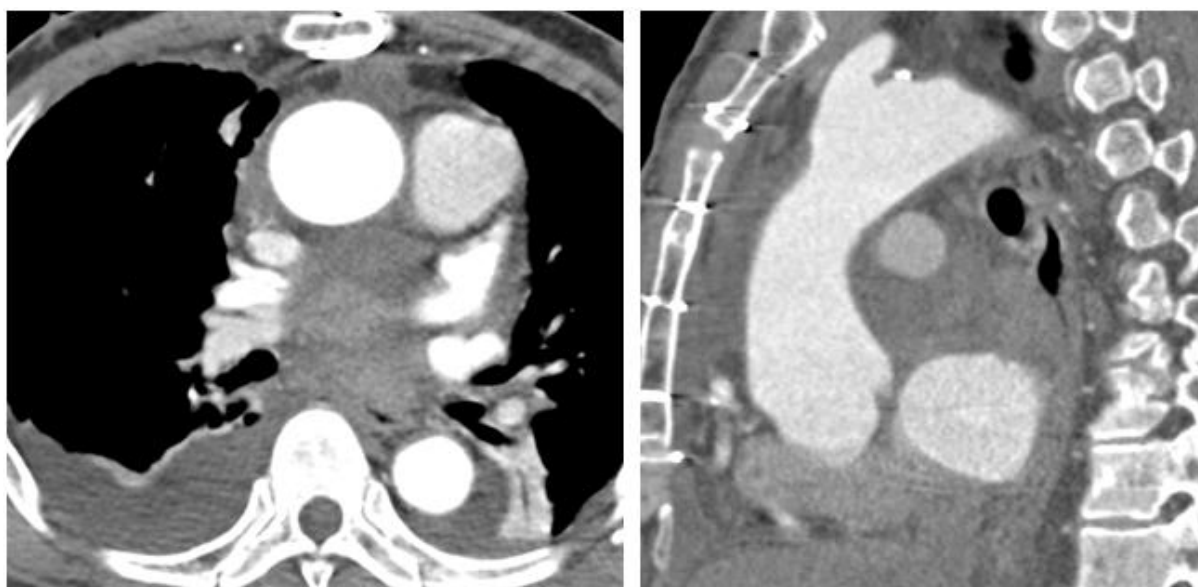
Dr MillinGarachh, finished MBBS from Sumandeep University, Baroda, Gujarat and DMRD Radiology from KLE university, Karnataka. Presently working as faculty at U. N. Mehta Institute of Cardiology and Research Center, Ahmedabad, Gujarat, India.



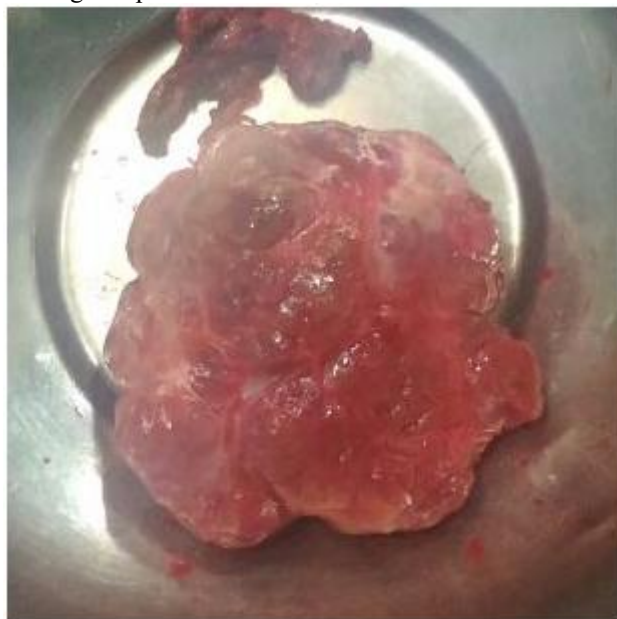Large heterogenous enhancing mass lesion is seen in middle mediastinum with few tiny non enhancing necrotic area without intralesional calcification



Arterial supply to the lesion is from RCA (Right coronary artery) and aortic branches as noted below



Post operative images showing complete removal of mediastinal mass with mild bilateral pleural effusion



Resected mass – Which was sent for histopath examination and turned out to be Paraganglioma