

Matrix Miniplate versus Locking Miniplate in the Management of Displaced Mandibular Angle Fractures

Wael Nagy Holaiel¹, Nagy Elprince², Magued Hussein Fahmy²

¹BDS, MS, Alexandria University, Faculty of Dentistry, Alex, Egypt

²Professor of Oral and Maxillofacial Surgery, Alexandria University Faculty of Dentistry, Alex, Egypt

Abstract: ***Aim:** this study aimed to compare clinically and radiographically the use of single locking miniplate with the 3d threadlockminiplate in the management of the isolated mandibular angle fractures. **Material and methods:** fourteen patients with isolated displaced mandibular angle fractures were subdivided into two equal groups. Group 1: were treated by open reduction and internal fixation using single locking miniplate through intraoral approach. Group 2: were treated by open reduction and internal fixation using 3d thread lockminiplate through extraoral approach. Both groups were followed up clinically and radiographically for 3 months evaluating the pain, the facial edema, the occlusal disturbances, the maximal mouth opening, the sensory function, the infection at the surgical site and the bone density at the site of the fracture. The results were calculated, compared and statistically analysed to indicate the efficacy of both plate types in the treatment of displaced isolated mandibular angle fracture. Results: All the clinical parameters evaluated were statistically insignificant (p value ≥ 0.05) except the facial edema as p value was 0.001, 0.001 and <0.001 along the follow up period. Radiographically the results were statistically significant at the 6th week and at the 12th week postoperatively p value was 0.001 and <0.001 respectively. Conclusion: both plating systems were suitable for the management of isolated mandibular angle fractures with small number of major complications, but the single locking miniplate was economically better and giving almost the same result as the 3d threadlockminiplate did.*

Keywords: locking miniplate, 3D thread lock miniplate, mandibular angle fractures, open reduction and internal fixation

1. Introduction

The mandibular angle is one of the most frequent sites for fractures of the lower jaw accounting for 20% to 36% of all mandibular fractures [1].

Osteosynthesis by using plates was a breakthrough in maxillofacial surgery. Its main advantage was that the patient did not need to undergo intermaxillary fixation for weeks [2].

Methods for open reduction of mandibular fractures have changed and diversified enormously in recent decades, but there is still controversy regarding the optimal treatment [3].

In 1973, Michelet et al describe the treatment of mandibular fractures using small, easily bendable, non compression miniplates placed transorally and anchored with monocortical screws. This technique contradicted the AO and Luh'r technique. Champy later performed a series of experiments with miniplates that delineated "ideal line of osteosynthesis" with in the mandible [4,5].

Champy's method of semi rigid fixation used one easily bendable monocortical miniplates along an ideal osteosynthesis line. Plates placed along these lines were thought to provide optimum fixation and stability but still many maxillofacial surgeons feel that miniplates also do not provide adequate stability and required maxillomandibular fixations for additional stability [6,7].

The shortcomings of rigid and semi rigid fixation led to the development of 3-dimensional miniplates. Unlike

compression and reconstruction plates, their stability is not derived from thickness of the plates. In combination with the screws monocortically fixed to the outer cortex, the matrix miniplate forms a cuboid, which possesses 3-dimensional stability [8].

To overcome the drawbacks associated with the use of previous modalities for the treatment of mandibular angle fractures and considering the current concept of the 3-dimensional miniplates, this study will be conducted in the Department of Oral and Maxillofacial Surgery, Alexandria University to evaluate the efficacy, stability and the clinical outcomes of the matrix miniplates for open reduction and internal fixation for non comminuted mandibular angle fractures.

2. Materials and Methods

Study Design

This study was conducted on a total number of 14 adult patients, who are suffering from isolated mandibular angle fractures which were not infected, nor comminuted.

All patients were selected, admitted and were operated in Oral and Maxillofacial surgery department, Faculty of Dentistry, Alexandria University, Egypt.

All patients had assigned an informed consent before they had been operated. This research had approved by the research ethics committee of Faculty of Dentistry, Alexandria University, Egypt.

All cases were divided into two groups of 7 patients in each group.

Group 1, control group treated using single intraoral locking miniplate on Champy principles.

Group 2, study group treated using 2 mm rectangular Titanium 3D miniplate (4x2 holes interconnected by vertical struts).

The 3D miniplates is a misnomer as the plates are not three dimensional but hold the fracture fragments rigidly by resisting the forces in three dimensions namely shearing, bending and torsional forces. The basic concept of 3D fixation is that a geometrically closed quadrangular plate secured with bone screws creates stability in three dimensions. The stability is gained over a defined surface area and is achieved by its configuration and not by thickness or length. The large free areas between the plate arms and minimal dissection permit good blood supply to the bone.

Both types of miniplates were fixed using

1. 2 mm mini screws (7 mm length and 5 mm length).
2. 1.5 mm drilling pit.

Inclusion criteria

- Medically fit patients free from relevant conditions contraindicating surgery.
- Patients suffered from recent, uninfected, noncomminuted isolated mandibular angle fractures.
- Patients aged from 20 to 60 years will be included.

Exclusion criteria

- Edentulous patients.
- Non displaced fractures.


Study sample

Patients who meet the inclusion criteria had been divided into 2 equal groups:

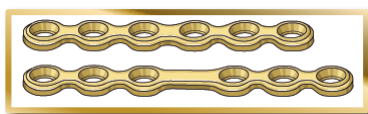
- Group 1 consists of 7 patients with mandibular angle fracture treated with locking miniplate.
- Group 2 consists of 7 patients with mandibular angle fracture treated with matrix miniplate.

In this study, 2 types of plates had been used for fixation of the isolated mandibular angle fractures:

- 1- Matrix miniplate (KLS Martin Group, Tuttlingen, Germany).



- 2- Locking miniplate.



A- Preoperative Assessment

1- History

Time, cause, place and type of injury recorded as well as past and present medical and dental history.

2- Clinical examination

a- Extraoral examination

- Inspection: including swelling, ecchymosis, facial deformity, jaw deviation during function, and soft tissue laceration.
- Palpation: any step deformity, tenderness, bony crepitus, condylar movements during opening and closing, and altered lip sensation (indicating inferior alveolar nerve injury) will be assessed.

B- Intraoral examination

- Inspection: including lingual hematoma, teeth integrity, and occlusal derangement.
- Palpation: of buccal and lingual sulci for the presence of tenderness or alteration in contour. Bimanual manipulation of the mandible on either side of the suspected fracture to detect any abnormal mobility.

1- Radiographic examination

Routine orthopantomogram or cone beam computerized tomograms were obtained for all patients preoperatively. Cone beam CT (CBCT) is a relatively new three-dimensional imaging technology, which has been specifically developed for imaging of the teeth and jaws with lower irradiation than conventional CT [9,10].

Radiological findings include: fracture site, degree of fracture displacement, presence of tooth in the fracture line, and presence of additional fractures.

C- Preoperative patient preparation

All patients instructed to perform oral hygiene measures.

Preparation for operation under GA

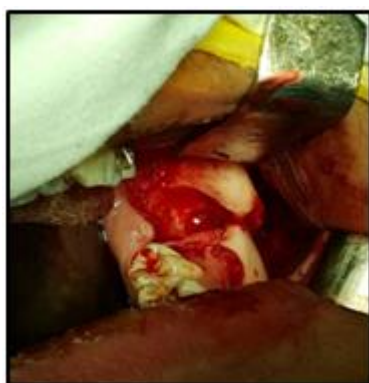1. Complete evaluation of the patient for medical and post traumatic status.
2. Routine preoperative laboratory investigations (Haemoglobin, Clotting time, Bleeding time, Prothrombin time and activity, Liver and kidney functions and fasting blood sugar)
3. Chest x-ray and ECG.
4. Prophylactic antibiotic (Amoxicillin 1g/Clavulanic acid every 12hrs). (Augmentin: Amoxicillin 875 mg + Clavulanic acid 125mg. manufactured by MPU)
5. Preoperative informed consent.

D- Operative Procedures

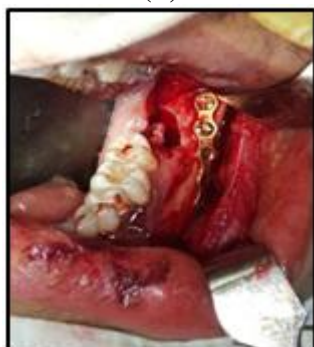1. General anaesthesia
 - a. Patient received induction and muscle relaxant then intubated via cuffed naso tracheal tube.
 - b. A pack is applied to prevent any blood, saline and foreign bodies to fall in the airway.
 - c. Patient is put in a hyper-extended neck position after ensuring that patient does not have a cervical spine fractures.
2. Disinfection, Draping and Towing

3. Application of upper and lower arch bars or eyelets or combination between them according to needs and IMF. (Figure 7)
4. Management of teeth in the fracture line by extraction or preservation as each case indicates.
5. Gaining access to the fracture site

For Group I: an intraoral incision had been made followed by reflection of mucoperiosteal flap till reaching the lower border of the mandible and reduction of the fractured segments then adaptation of a single locking miniplate along Champy's line of ideal osteosynthesis; secured with monocortical screws then The area was irrigated with betadine and saline and after adequate hemostasis was achieved then closure of the wounds in layers using resorbable sutures without drains. (Figure 1)



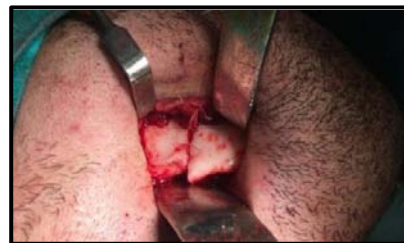(A)



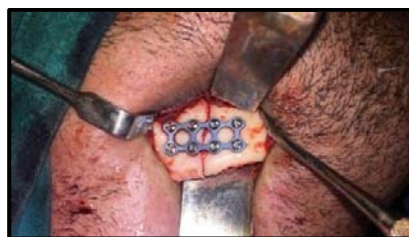(B)

Figure 1: (A) Clinical photograph showing right displaced mandibular angle fracture, (B) Showing single locking miniplate adapted and fixed to the reduced fracture.

For Group II: gloves had been changed followed by rescrubbing of the surgical site and exposure of the mandibular angle via a submandibular incision and dissection till reaching the fracture site, then the fractured segments had been reduced into proper anatomical position followed by drilling of the screw holes using surgical drill under constant saline irrigation. Fixation of the fractured angle was then accomplished using matrix miniplate followed by closure of the extraoral wound in layers after ensurance of heamostasis and irrigated surgical site. (Figure 2)



(A)



(B)

Figure 2: (A) Showing displaced mandibular angle fractures, (B) showing 3D locking miniplate adapted to the lateral aspect of the mandible after reduction of the fracture.

Estimation of the Operation Time

A- Postoperative care

Each patient had received intravenous Cefotax I gm/12 hours for one day postoperatively followed by Augmentin (Augmentin: Amoxicillin 875 mg + Glavulanic acid 125mg, manufactured by MPU.) 1 gm twice daily for the next 5 days.

- Analgesic anti-inflammatory drug in the form of Rheumafen (Rheumafen: Diclofenac Sodium 75mg/2ml amp. by GlaxoSmithKline.) 75 mg vial till the second postoperative day followed by Cataflam (Cataflam: Diclofenac Potassium 50mg, by Novartis.) 50 mg tablets three times daily.
- All patients were instructed to use chlorhexidine mouth wash for maintenance of good oral hygiene.
- Instruction of soft diet for all patients for 4 weeks postoperatively.
- Patients were instructed for application of cold fomentation on the extraoral surgical site for 10 min/1 hour in the first postoperative day, followed by hot fomentations for 10 min/1 hour starting from the second postoperative day.

B- Follow-up

Follow-up schedule: 1 week, 2 weeks, 1 month, 6 weeks, and 3 months.

Clinical Parameters

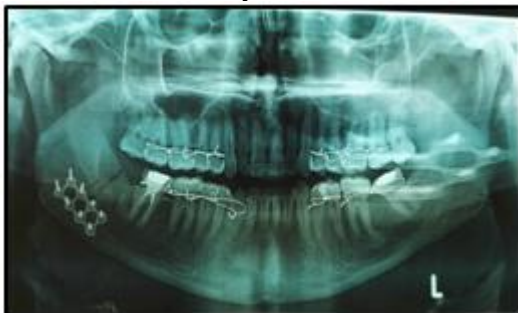1. Pain: had been measured on Visual Analogue Scale (VAS). The patients were asked to rate their postoperative pain on a 4-point scale (0= none, 1= slight, 2= moderate, 3= severe) [11].
2. Facial edema, determined using a measuring tape. Three measurements were made between 5 reference points: tragus, soft tissue pogonion, lateral corner of the eye, angle of the mandible, and outer corner of the mouth, preoperatively, and on the second and seventh postoperative days. The preoperative sum of the 3 measurements will be considered as the baseline for that side. The difference between each postoperative measurement and the baseline indicates the facial swelling for that day [12].

3. Maximal mouth opening: we measured maximal interincisal opening between maxillary and mandibular central incisors.
4. Sensory function: assessment of sensory function of the inferior alveolar nerve subjectively by asking the patient about any alteration in sensation in addition to objective examination by using a dental probe to assess the sensory changes along the distribution of the mental nerve (lower lip and chin) through examining lip sensation in comparison to the contralateral side [13].
5. Surgical wound: assessed for signs and symptoms of infection including swelling, redness, hotness, discharge, and pain in addition to observation for any manifestations of wound healing disturbance.
6. Occlusion: Occlusion had checked in the maximal intercuspal position (centric occlusion) to ensure proper occlusal relationship including molar relation and midline centralization. Any occlusal disturbance including open bite or improper tooth contact had recorded.

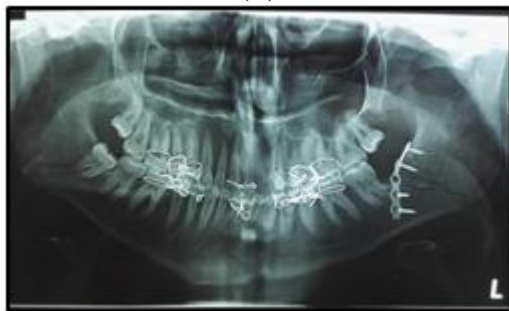Radiographic follow-up

We used O.P.G. before patient discharge to assess adequate reduction of the fractured segments. (Figure 3). Furthermore cone beam computerized tomograms had been taken at 6 weeks, and 3 months postoperatively for:

- Assessment of progressive healing of the fracture.
- For radiodensitometric measurement: to analyze the mean bone density at the site of fracture using the other side as a control for the bone density values in each case.



(A)



(B)

Figure 3: (A) An immediate panoramic x-rays showing a properly reduced mandibular angle fracture using 3D locking miniplate, (B) An immediate panoramic x-ray showing a properly reduced mandibular angle fracture using a single locking miniplate.

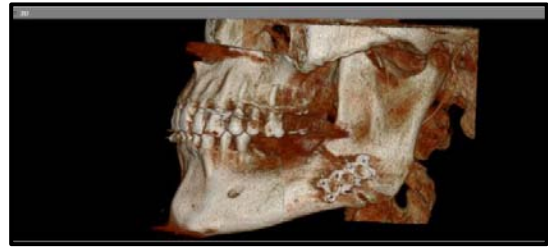

Figure 4: 3D image showing the bone healing after 3 months in isolated mandibular angle fracture fixed with 3D threadlock miniplate.

3. Results

Fourteen patients; ten males and four females; with a ratio of (5:2) divided into two groups, of seven patients in each group were included in this study. Patient's age were ranging from 20 to 60 years old with a mean of (33.21± 9.79)

The mandibular fractures involved were fourteen isolated mandibular angle fractures.

All patients were treated by ORIF using 3D miniplates through extraoral approach and locking miniplate through intraoral approach equally, the average time of hospitalization preoperatively was from 1 to 3 days until oedema subsided, while the average time of hospitalization postoperatively was only 2 days

Immediate postoperative results

The patients were seen every 2 days for the first week. As regards oedema, it was limited only to the area adjacent to the fracture site and resolved by the seventh postoperative day.

Regarding the pain, no complaints were reported. All cases of both groups had no pain by the end of the second week.

Delayed postoperative result

All cases showed stability of the bony segments in the normal position, no mobility of the bony segments was detected.

No signs of infection or suppuration were observed except in two cases that developed pus discharge intraorally, and one case belongs to the study group but all the three cases were managed with another course of antibiotic and the infection totally resolved

All patients showed normal occlusion and intercuspal relations of the teeth with no need for selective grinding except for 2 cases those treated by single intraoral locking miniplate

Management of the teeth in the fracture line done by extraction or preservation as each case indicates

All cases were able to maintain good oral hygiene by the conventional means through tooth brushing and the use of warm normal saline as a mouthwash

The periodontal tissues appeared healthy with no areas of gingival involvement or inflammation

All cases of both groups turned to their normal maximum mouth opening by the end of the follow up period

All cases of both groups that had some sensory disturbances caused by the trauma due to the displacement of the fractured segments recovered by the 4th week postoperatively for the control group and the 6th week postoperatively for the study group.

Radiographically

Immediate postoperative panoramic X-ray, showed satisfactory reduction in all cases proper bony alignment at the lower border of the mandible without noticeable step and proper teeth alignment.

After 6 weeks the CBCT showed stable fracture segments in all cases.

After three months, the CBCT showed good healing at the fracture sites.

Regarding the pain for control group where pain intensity score scaled from 0 (No pain) to 3 (Most severe pain). It was found that:

- The pain score after through the 1st week was (1) for one case, (2) for four cases and (3) for two cases.
- The pain score through the 2nd week was (1) for five cases and (2) for two cases
- The pain score after 4th week, the 6th week and the 12th week was (0) for all cases.
- So the results for the study group were found to be statistically significant as p value ≤ 0.05 along the follow up period

Regarding the pain for the study group. It was found that:

- The pain score through the 1st week was (1) for one case, (2) for three cases and (3) for three cases
- The pain score through the 2nd week was (0) for two cases and (1) for five cases.
- The pain score by the end of the 2nd week, the 4th week, 6th week and the 12th week was (0) for all cases.
- So the results for the study group were found to be statistically significant as p value ≤ 0.05 along the follow up period

When we compared the pain intensity scores for the two groups, the results were found to be statistically insignificant

Regarding the facial edema for the control group where the facial edema valued by using 3 lines measurements along 5 fixed points. It was found that: Regarding the facial edema for the study group It was found that:

- The mean facial edema score preoperatively was (33.14) with SD \pm (4.30)

- The mean facial edema score on 2nd postoperative day was (38.29) with SD \pm (3.30)
- The mean facial edema score on 7th postoperative day was (29.57) with SD \pm (2.82)
- The results were statistically significant at p value $p_1 < 0.001^*$, $p_2 = 0.002^*$, $p_3 < 0.001$.

Regarding the facial edema for the study group. It was found that:

- The mean facial edema score preoperatively was (42.0) with SD \pm (1.29).
- The mean facial edema score on 2nd postoperative day was (45.43) with SD \pm (0.98).
- The mean facial edema score on 7th postoperative day was (37.71) with SD \pm (1.11).
- The results were statistically significant as p value ≤ 0.05 .

The facial edema had improved from preoperative to the 2nd postoperative day and from the 2nd postoperative day to the 7th postoperative day for both groups.

The results were statistically significant when we compared the two groups at p value 0.001, 0.001 and < 0.001 .

Regarding the occlusal disturbances for the control group where occlusion score scaled from 0 (No occlusal disturbance) to 1 (Occlusal disturbance) according to visual analog scale, It was found that:

- The occlusion score in all cases preoperatively was 1.
- The occlusion score in all cases after one week was 1 for 2 cases.
- The occlusion score in all cases after two weeks was 1 for 2 cases.
- The occlusion score in all cases after one month was 0.
- The occlusion score in all cases after two month was 0.
- The occlusion score in all cases after three month was 0.

The occlusion of the 2 cases treated with single locking miniplate came to normal by minimal selective grinding by the end of second week. so the results were found to be statistically insignificant from preoperative to postoperative at p value 0.063

Regarding the occlusal disturbances for the study group It was found that:

- The occlusion score in all cases preoperatively was 1.
- The occlusion score in all cases after one week was 0.
- The occlusion score in all cases after two weeks was 0.
- The occlusion score in all cases after one month was 0.
- The occlusion score in all cases after two month was 0.
- The occlusion score in all cases after three month was 0.

Occlusion disturbance was significantly came to normal in all cases across the follow up period and were found to be statistically significant from preoperative to postoperative as p value was 0.016 along the whole follow up period ($p < 0.05$).

When we compared the two groups, the results were statistically insignificant at p value 0.462

Regarding the maximal mouth opening for both groups, the maximum mouth opening scores in mm on 1st week, 2nd week, 1 month, 6th week and 3 month.

The maximum mouth opening was significantly increased in all cases of each group and the results for each group were statistically significant as p value were <0.001 ($p < 0.05$).

When we compared the results of the two groups there were no significant difference neither clinically nor statistically as the p value were 0.605, 0.653, 0.851, 0.115, 0.117 along the follow up period.

Regarding the sensory function for the control group four cases experienced sensory disturbances through the 1st week.

Through the 2nd week only one case had sensory disturbances.

By the 4th week all cases were free. The results were statistically insignificant along the follow up period at p value 0.250, 0.125, 0.125 and 0.125.

Regarding the sensory function for the study group

On the 1st week all cases had sensory disturbances.

By the 2th week 5 cases had sensory disturbances.

Through the 4th week 3 cases had sensory disturbances.

After 6 weeks only 1 case had sensory disturbances.

By the 12th week all cases were free.

The result for this group became statistically significant by the 6th and the 12th week postoperatively as p value 0.031 and 0.016.

In the comparison between the two groups, the results were statistically insignificant as p value was ≥ 0.05 .

Regarding the infection at the surgical site for the control group

Only 2 cases showed signs of infection and controlled by another course of antibiotic.

For the study group

One case showed signs of infection and bus discharge at the site of the surgical wound and this also controlled by another course of antibiotic.

When we compared the results of the two groups there was no significant difference between them.

Regarding the bone density

For the control group

The mean bone density at the fracture site was 541.70 ± 35.59 after 6 weeks.

The mean bone density at the fracture site was 593.98 ± 23.82 after 12 weeks.

For the study group

The mean bone density at the fracture site was 613.95 ± 22.95 after 6 weeks.

The mean bone density at the fracture site was 683.95 ± 20.12 after 12 weeks.

The results were statistically significant by the 6th week and the 12th week postoperatively for both groups .p value for control group (0.001) and for study group <0.001 .

When we compared the results at 6 weeks they were statistically significant at p value 0.001 and by the 12th week postoperatively it was <0.001 .

4. Discussion

Fractures of the mandibular angle are associated with the highest incidence of postoperative complications of all mandibular fractures ranging from 0 to 32%. This may be due to its thin cross-sectional bone area and the biomechanics of the mandibular function. This is the angular region where the powerful elevator muscles that are attached to the ramus transfer their forces to the body of the mandible. This creates great demands on fixation if the rigidity under a functional load is to be maintained [14].

Different treatment modalities for managing a mandibular fracture have been described. Although in the past, fractures of the mandibular body, ramus or angle were treated with closed reduction and intermaxillary fixation (IMF), currently the state of art is to stabilize these fractures by open reduction and fixation with osteosynthesis material [15] The change in surgical practice has been accompanied by a proliferation in the number and design of rigid fixation plating systems. The method of fixation proposed by Champy (1978) [16], in case of mandible angle fracture is designed to apply a miniplate at the superior border of the mandible with monocortical screws. As it is placed through an intraoral approach, facial scarring is minimized, the likelihood of damage to the facial nerve and inferior alveolar nerve is minimized. Champy recommended a single non-compression miniplate, ventral to oblique line for mandibular angle fracture [17].

However, Sagiura et al (2001) in their retrospective study concluded that adequate stability could not be obtained with a single miniplate (clinical and radiological outcomes were compared) [18]. The use of a second plate was suggested to reduce anterior-posterior separation of the fracture line as well as lateral displacement, which is frequently observed. The second miniplate theoretically establishes a second line of osteosynthesis, which protects the fracture site against torsion and bending, and provides increased stability [19,20].

More recently, 3D titanium miniplates and screws have been developed by Farmand M in 1993 [21]. Their shape is based on the principle of the quadrilateral as a geometrically stable configuration for support. As it allows more screws, it is 91 malleable, provides stability in 3 dimensions, and also provides more torsional stability. Feledy et al (2004) [22] and Alkan et al (2007) [23] compared the stability of a single 2 mm matrix miniplate and with that of two 2mm miniplates for mandibular angle fracture. They found no cases of dysocclusion, non union or plate fracture, and also confirmed that a matrix miniplate provided sufficient stability for fracture healing. Guimond et al (2005) [24] also

confirmed the advantage of these plates in mandibular angle fractures.

In this study, threadlock 3D plates with locking screws were used in comparison with the single locking miniplate placed according to Champy's principles.

Theoretically, it has been proposed that in the locking bone plate/screw system, screws are unlikely to loosen from the bone plate and there is decreased incidence of inflammatory complications associated with loosening of hardware [25]. It is also postulated that the locking plate/screw system requires less precise adaptation of plate to underlying bone and decreases the chance of screw stripping with associated inflammation.

Noncompression decreases necrosis of fracture segments and produces less stress shielding [26].

In the current study, fourteen patients were selected with isolated mandibular angle fractures as it is postulated that an additional mandibular fracture may act as a confounding variable and thus affect the treatment outcome. This is consistent with the recommendations of Barry and Kearns (2007) [27] who suggested that a second fracture may contribute to instability at fracture site, leading to impaired bone healing, predisposing to infection, or dysocclusion. Thus the isolated mandibular angle fracture allows us to establish the true complication rate for these fractures.

The fourteen patients were divided into two equal groups:

Group 1: Treated by the use of single locking miniplate through intraoral approach.

Group 2: Treated by the use of matrix miniplate through extraoral approach.

In all cases, third molars were not removed during surgical intervention unless they were also fractured, luxated or they prevented an appropriate reduction.

Several authors (Gear et al 2005, Bolourian et al 2002) [28,29] have suggested supplementing miniplate fixation with MMF to allow stabilization of the occlusion, as they felt that single miniplate fixation did not provide adequate stability and required MMF for additional stability, however this issue is still controversial. So, in this study, MMF was kept only to gain a proper occlusion prior to the plate fixation in both groups.

Postoperatively, clinical and radiographic outcomes were evaluated in both groups over a 3-months follow up period. None of the patients in either of the groups had nonunion, plate fracture, or loosening of plate and screws within the follow up period.

The results of the present study the postoperative clinical manifestation were evaluated.

Regarding the pain

All cases of both control and study groups had no pain by the end of the second week.

So no significant difference between the two plating systems in managing the mandibular angle fractures.

Regarding the facial edema

The edema at the surgical site subsided by the 7th postoperative day for both groups.

There was significant difference between the measurements preoperatively and postoperatively for each group separately. We should not consider the comparison between the measurements for the two groups as the distance between the fixed five points is not equal for all patients so this is an anatomical variant differs from an individual to another, however the results were statistically significant in these comparison.

Regarding the occlusal disturbances

There was a significant difference between the preoperative and the postoperative assessment of the occlusion for each group.

But when we compared the two groups the results were statistically insignificant. Only 2 cases that treated by using single locking miniplate had occlusal disturbances and they came to normal occlusion by minimal occlusal grinding.

For the study group all cases had no disturbances in occlusion postoperatively. This is consistent with the literature in which clinical studies investigating 3-dimensional plates showed that the occurrence of occlusal changes ranged from 0% to 20% (Guimond et al 2005, Zix et al 2007, Feledy et al 2004) [22,24,30]. This is most probably attributed to the higher 94 stability of fracture segments and consequently stable occlusion offered by the 3-dimensional plate design.

So the use of the matrix plate is superior to the use of single locking miniplate in the treatment of isolated mandibular angle fractures regarding this point.

Regarding the maximum mouth opening

The results were statistically significant along the follow up period for each group but when we compared the two groups there was no significant difference.

The patients of the two groups were instructed to do physiotherapy along the follow up period.

All cases included in this study turned to their normal mouth opening by the end of the follow up period.

The mean maximum mouth opening on the end of the follow up period for the control group was 42.14 mm, where, the maximum mouth opening for the study group was 44 mm.

Regarding the sensory function

All cases experienced sensory disturbances preoperatively as a result of their trauma. This agrees with a study on 3D plates (Guimond et al 2005) [24], which also found that the main cause of sensory deficit in mandibular angle fractures was the trauma itself. The most probable reason for intraoperative damage to the nerve is fracture manipulation, rather than drilling and screw placement close to the nerve.

For the control group this disturbances continued in 4 cases along the first week postoperatively, then 1 case had this complaint along the second and the third week, by the end of the third week postoperatively all cases are free. The results for this group were statistically insignificant.

For the study group, the results were statistically significant along the 1st, 2nd and 4th week postoperatively .it became significant by the 6th and the 12th week.

All disturbances were resolved by the 12th week postoperatively for this group. This is consistent with previous studies, which found that the incidence of persistent inferior alveolar nerve deficits is related to the degree of fracture displacement[24].

When we compared the results of both groups there was no significant difference.

It was better to assess the motor function not only the sensory function for the study group because of the iatrogenic injury of the marginal mandibular nerve associated with the submandibular approach used as an access to the fracture site in this group.

Regarding the infection at the surgical site

Two cases of the control group had some infection related to the surgical wound and controlled by antibiotics.

This was due to salivary contamination and difficulty to maintain good oral hygiene with the intraoral approach used in this group which is inaccessible.

Only one case of the study group had infection at the site of surgical wound and also controlled by the use of antibiotics.

So the results were with no statistical significance.

Regarding the bone density

In this study, cone beam CT was done postoperatively at 6 weeks and 3 months. Bone density was measured in the vicinity of the fracture line using the CBCT software. Three readings were taken each time and then the average was calculated to determine the mean bone density.

For the control group, the mean bone density by the 6th week postoperatively was 541.70 and by the 12th week it was 586.63.

For the study group, the mean bone density was 608.13 by the 6th week postoperatively and 686.70 by the 12th week.

The results of this study showed that the increase in mean bone density was statistically significant in each one of the groups from 6 weeks to 3 months, consistent with the progress of fracture bone healing.

The difference in the mean bone density between the two groups was statistically significant at 6 weeks and 3 months postoperatively, mostly due to the better fracture stability offered by the 3D plates during the healing period especially in displaced fractures.

Some studies suggested that Measuring the bone density using CBCT was not so accurate, one of them found that the use of a CBCT to evaluate the bone density of jaws is not useful when the values are taken as absolute values. In spite of the lower radiation dose and costs of CBCT, this new technique does not allow an accurate assessment of bone density[31].

Also another study evaluating the accuracy of the CBCT in measuring the bone density found that The lower radiation dose and reduced costs of CBCT make this a useful substitute for CT; however, this study has shown that, in order to more accurately define the bone density with CBCT, a conversion ratio needs to be applied to the voxel value[32].

5. Conclusion

Considering the results of the current study, it is concluded that both the single locking titanium miniplate and the 3D threadlock titanium plate are suitable for the management of displaced mandibular angle fractures. Both plating systems giving nearly the same clinical results. However the better results of the 3D threadlock plating system regarding the bone density, the single locking miniplate system is economically better.

However the use of CBCT gives less radiation dose, gives a 3D images and less expensive than CT, its use in measuring the bone density is not so accurate as CT.

References

- [1] Ogundare BO, Bonnick A, Bayley N. Pattern of mandibular fractures in an urban major trauma center. *J Oral Maxillofac Surg* 2003; 61: 713.
- [2] Sauerbier S, Shon R, Otten JE, Schmelzeisen R, Gutwald R. The development of plate osteosynthesis for the treatment of fractures of the mandibular body-A literature review. *J Craniomaxillofac Surg* 2008; 36: 251-9.
- [3] Gear AJ, Apasova E, Scimitz JP, et al. Treatment modalities for mandibular angle fractures. *J Oral Maxillofac Surg* 2005; 63: 655.
- [4] Ellis E, N Karas. Treatment of mandibular angle fracture using two dynamic compression miniplates. *J Oral Maxillofac Surg* 1994; 52:1032-6 .
- [5] Champy M, Lodde JP. Mandibular synthesis. Placement of synthesis as a function of mandibular stress. *Rev StomatolChirMaxillofac* 1976; 77: 971-6 .
- [6] M Champy, HD Pape. *The Strasbourg MiniplateOsteosynthesis*. Chicago, USA: Quintessence. 1986:19-43.
- [7] K Ikemura, Y Kouno, H Shibata. Biomechanical study on monocorticalosteosynthesis for fracture of mandible. *Int J Oral Surg*. 1984;13:307-312 .
- [8] Zix J, Lieger O, Iizuka T Use of straight and curved 3 Dimensional titanium miniplates for the fracture fixations at the mandibular angle. *Oral Maxillofac Surg* 2007; 65: 1758-63.
- [9] Dawood A, Patel S, Brown J. Cone beam CT in dental practice. *Br Dent J* 2009; 207: 23-8.
- [10] Kau CH, Bozic M, English J, Lee R, Bussa H, Ellis RK. Conebeam computed tomography of the maxillofacial

region-an update. *Int J Med Robot* 2009; 5:366-80.

- [11] Chang JD, Bird SR, Bohidar NR, King T, Analgesic efficacy of rofecoxib compared with codeine/acetaminophen using a model of acute dental pain. *Oral Surg Oral Med Oral Pathol Oral RadiolEndod* 2005; 100: E74-80.
- [12] Ustun Y, Erdogan O, Esen E, Karsli ED. Comparison of the effects of 2 doses of methylprednisolone on pain, swelling, and trismus after third molar surgery. *Oral Surg Oral Med Oral Pathol Oral RadiolEndod* 2003; 96: 535-9.
- [13] Al-Bishri A, Barghash Z, Rosenquist J, Sunzel B. Neurosensory disturbance after sagittal split and intraoral vertical ramus osteotomy: as reported in questionnaires and patients' "records. *Int. J Oral MaxillofacSurg* 2005; 34: 247-51.
- [14] Ellis E. Outcomes of patients with teeth in the line of mandibular angle fractures treated with stable internal fixation. *J Oral MaxillofacSurg* 2002; 60: 863-5.
- [15] de Matos FP, Arnez MF, Sverzut CE, Trivellato AE. A retrospective study of mandibular fracture in a 40-month period. *Int J Oral MaxillofacSurg* 2010; 39: 10-5.
- [16] Champy M, Loddè JP, Schmitt R, Jaeqer JH, Muster D. Mandibular osteosynthesis by miniature screwed plates via a buccal approach. *J MaxillofacSurg* 1978; 6: 14-21.
- [17] Assael LA. Treatment of mandibular angle fracture: plates and screws. *J Oral MaxillofacSurg* 1994; 52: 757-61.
- [18] Sagiura T, Yamamoto K, Murakami K, et al. A comparative evaluation of osteosynthesis with lag-screws, miniplates, or Kirschner wires for mandibular condylar process fractures. *J Oral MaxillofacSurg* 2001; 59: 1161-8.
- [19] Schierle HP, Schmelzeisen R, Rahn B and Pytlik C. One or two-plate fixation of mandibular angle fractures? *J CraniomaxillofacSurg* 1997; 25: 162-8.
- [20] Ellis E, Walker L. Treatment of mandibular angle fractures using two noncompression miniplates. *J Oral MaxillofacSurg* 1994; 52: 1032.
- [21] Farmand M. The 3-D plating system in maxillofacial surgery. *J Oral MaxillofacSurg* 1993; 51: 166-7.
- [22] Feledy J, Caterson EJ, Steger S, Stal S, Hollier L. Treatment of mandibular angle fracture with matrix miniplates. A preliminary report. *PlastReconstrSurg* 2004; 114: 1711-6.
- [23] Alkan A, Celebi N, Ozden B, Bas B, Inal S. Biomechanical comparison of different plating techniques in repair of mandibular angle fractures. *Oral Surg Oral Med Oral Pathol Oral RadiolEndod* 2007; 104: 752-6.
- [24] Guimond C, Johnson JV, Marchena JM. Fixation of Mandibular Angle Fractures With a 2.0-mm 3-Dimensional Curved Angle Strut Plate. *J Oral MaxillofacSurg* 2005; 63: 209-14.
- [25] Ellis E III, Graham J. Use of a 2.0-mm locking plate/screw system for mandibular fracture surgery. *J Oral MaxillofacSurg* 2002; 60: 624-45.
- [26] Haug RH, Street CC, Goltz M. Does plate adaptation affect stability? A biomechanical comparison of locking and nonlocking plates. *J Oral MaxillofacSurg* 2002; 60: 1319-26.
- [27] Barry CP, Kearns GJ. Superior border plating technique in the management of isolated mandibular angle fractures: a retrospective study of consecutive patients. *J Oral MaxillofacSurg* 2007; 65: 1544-9.
- [28] Gear AJ, Apasova E, Schmitz JP, Schubert W. Treatment modalities for Mandibular Angle Fractures. *J Oral MaxillofacSurg* 2005; 63: 655-63.

- [29] BolourianR, Lazow S, BergerJ. Transoral 2.0-mm miniplate fixation of mandibular fractures plus 2 weeks' maxillomandibular fixation: a prospective study. *J Oral MaxillofacSurg* 2002; 60: 167-70.
- [30] Zix J, Lieger O, Lizuka T. Use of Straight and Curved 3-dimensional Titanium Miniplates for Fracture Fixation at the Mandibular Angle. *J Oral MaxillofacSurg* 2007; 65: 1758-63.
- [31] Cassetta M, Stefanelli LV, Di Carlo S, Pompa G, Barbato E. European Review for Medical and Pharmacological Sciences. The accuracy of CBCT in measuring jaws bone density. Department of Oral and Maxillofacial Sciences, Sapienza University of Rome, Italy 2012; 16: 1425-9.
- [32] Cassetta M, Stefanelli LV, Pacifici A, Pacifici L, Barbato E. How accurate is CBCT in measuring bone density? A comparative CBCT-CT in vitro study. *Clin Implant Dent Relat Res* 2014;16: 471-8.

Author Profile



Wael Nagy Holaiel, received the B.D.S. In Dental and Oral Surgery from Alexandria University, Faculty of Dentistry 2007. he practiced in Ministry of Health. Since 2009 till now. During 2013-2017, he educated for M.S degree in oral and maxillofacial surgery department, Faculty of dentistry. Alexandria University.