

Hemisection: A Endo–Perio Management of a Mandibular Molar Tooth in a Young Patient

Arpit Singhi¹, Prakash Somani²

Department of Periodontics, Vyas Dental College, Kudi NH-65, Jodhpur-342005

Abstract: Hemisection is sectioning of multi-rooted teeth with its crown portion, with the loss of periodontal attachment and is performed to retain the original tooth structure and attain the fixed prosthodontic prosthesis. In this case report, a 38 year old female with an advanced Endo-Perio lesion on a mandibular first molar was successfully treated by root-canal treatment and hemisection. This procedure helps preserve the tooth structure, alveolar bone and promote cost savings over other treatment options

Keywords: Endodontic, hemisection, mandibular molar, prosthodontic periodontal, root resection

1. Introduction

Recent advances in dentistry provide the opportunity for patients to maintain a functional dentition for decades. One of the indications of extraction of a tooth is loss of alveolar bone support.

In case of mandibular molars, in some cases one of the roots will be in advanced state of periodontal disease while the other root may be salvageable. Hemisection refers to surgical separation of a multi-rooted tooth with the extraction of one root along with the overlying crown. (1)

Loss of the posterior teeth is eventful and undesirable often leading to teeth drifting, loss of masticatory function and loss of arch length, which requires prevention and maintenance measures.(2)

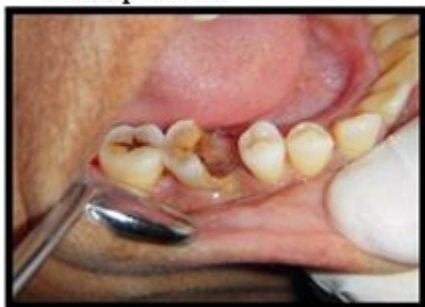Treatment strategy to retain such teeth involves periodontal, prosthodontic and endodontic assessment for appropriate selection to allow for stronger survival(3)

2. Case Report

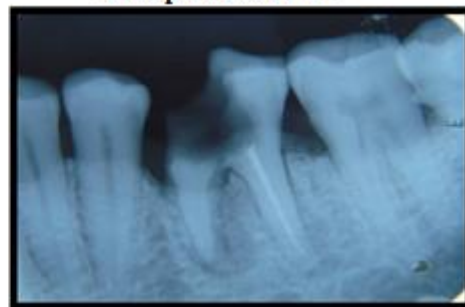A 38 year old female reported with pain in back tooth region since 15 days. On examination it was found out that tooth 46 was tender on percussion and deep caries and on mesial to 46 there was a pocket of 10 mm On radiographic examination, vertical bone loss was evident on mesial side of 46 with furcation involvement . Hemisection of mesial root was decided after the completion of endodontic treatment for the distal root

After endodontic therapy was completed hemisection was planned . under local anesthesia, full thickness flap was reflected after giving a crevicular incision from first premolar to second molar. Upon reflection of the flap, a vertical bony defect along the mesial root became quite evident. All chronic inflammatory tissue was removed with curets to expose the bone. The vertical cut method was used to resect the crown. A long shank tapered fissure carbide bur was used to make vertical cut toward the bifurcation area. A fine probe was passed through the cut to ensure separation (Fig.). The mesial root was extracted and the socket was irrigated adequately with sterile saline to remove bony chips and suture were placed and patient was recalled after 7 days.

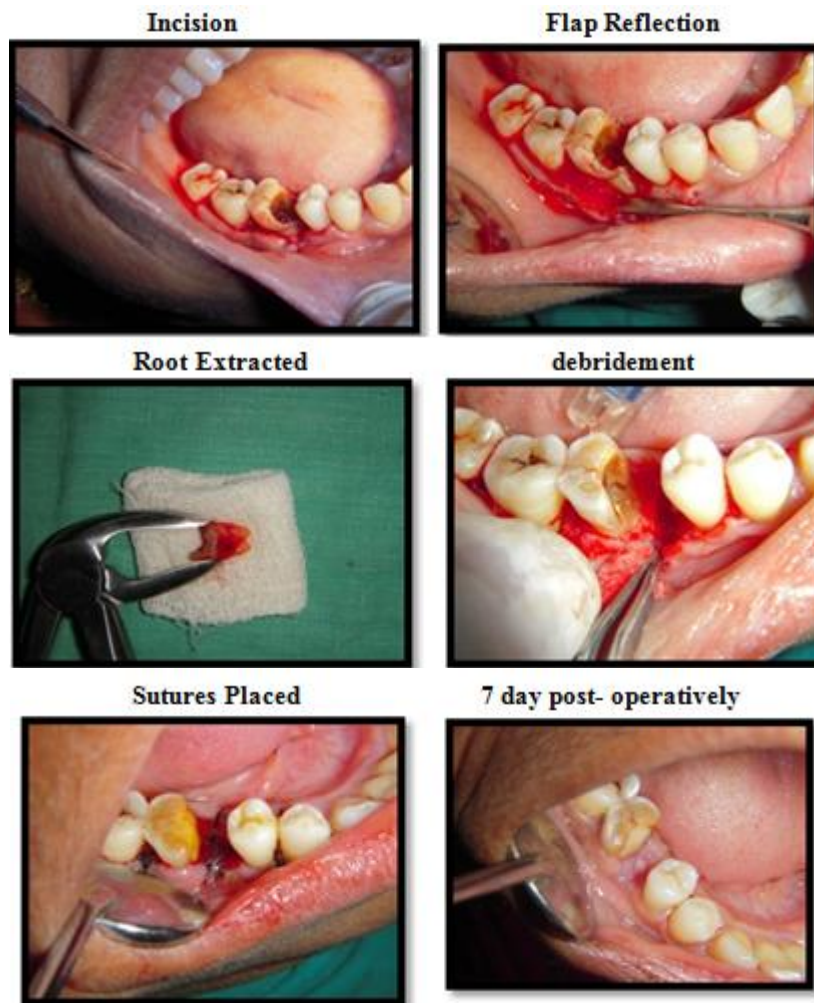
Pre-operative



Pre-operative-IOPA



Operative procedure



3. Discussion

The hemisection is a useful alternative treatment to extraction to save the multi-rooted teeth by endodontic approach, which includes the root canal treatment of the remaining roots and restoring them with suitable restorative material to splinting it with the adjacent tooth to decrease the risk of displacement followed by a fixed prosthodontic prosthesis to maintain the occlusal balance(4).

Tooth hemesection can be done in the following cases:

a) Periodontal considerations: -

- 1) Severe vertical bone loss involving only one root of a multi rooted tooth.
- 2) Through and through furcation destruction.
- 3) Proximity of roots of adjacent teeth preventing adequate maintenance of oral hygiene.
- 4) Root exposure due to dehiscence

b) Restorative and endodontic considerations:

- 1) Periodontal failure of an abutment tooth in a fixed bridge.
- 2) If one root cannot be completely instrumented due to anatomic reasons or due to iatrogenic causes.
- 3) Vertical fracture of one root.
- 4) Severe destruction of one root due to resorption, caries, trauma or perforation.[5]

The terms 'root amputation' and 'hemi-section' are known collectively as 'root resection'. According to Newell(6)

Akki S[7] reported a case with missing mandibular left first premolar and grade-I mobility of mandibular left first molar and 9mm deep periodontal pocket on the distal root. Distal root was extracted. The treated teeth were successfully used as abutments for small bridges.

Various authors have published case reports with long term follow up which points to the success of hemisection as a viable treatment option.[8]

4. Conclusion

Therapeutic strategies of teeth with furcation involvement should include the option of resective treatment. This case report shows the treatment of a periodontally compromised tooth by multidisciplinary treatment approach. The success of the hemisection procedure depends on the supporting bone, the restorative treatment plan, and the oral hygiene of the patient. Regular periodontal maintenance and sufficient coronal restoration of the root resected teeth are important preconditions for long term survival.

References

- [1] Ammons WF Jr, Harrington GW. Furcation: Involvement and treatment. Carranza's Clinical Periodontology, 10th ed., Elsevier India, Saunders (WB); 2007. P 991-1004.
- [2] Behl AB. Hemisection of a multirrooted tooth - A case report. Open Access Sci Rep. 2012;1:1-3.
- [3] Jain A, Bahuguna R, Agarwal V. Hemisection as an alternative treatment for resorbed multirrooted tooth — A case report. Asian J Oral Health Allied Sci. 2011;1:44-6.
- [4] Saad MN, Moreno J, Crawford C. Hemisection as an alternative treatment for decayed multirrooted terminal abutment: A case report. J Can Dent Assoc. 2009;75:387-90.
- [5] Parmar G, Vashi P. Hemisection: A case-report and review. Endodontol 2003;15:26-9.
- [6] Newell DH. The diagnosis and treatment of molar furcation invasions. Dent Clin North Am 1998;42:301-37
- [7] Buhler H. Evaluation of root resected teeth. Results after ten years. J Periodontol 1988;59:805-10
- [8] Blomlöf L, Jansson L, Appelgren R, Ehnevid H, Lindskog S. Prognosis and mortality of root-resected molars. Int J Periodont Restorat Dent 1997;17:191-201