

Comparison of the Image Quality of Intraoral Radiograph (IOPA) and Orthopantomograms (OPG)

Kaviena Baskaran

Saveetha Dental College, Poonamallee High Road, Vellapanchavadi

Abstract: ***Objectives:** The purpose of this study is to compare the image quality of both intraoral periapical radiographs and orthopantomograms according to the different dental regions (maxillary and mandibular incisor, canine, premolar and molar). **Materials and Methods:** The study is to be carried out on 50 patients. Intraoral periapical radiographs and orthopantomograms are to be obtained. All measurements were performed by an oral radiologist. The radiographs evaluated by 50 observers. The image quality of both intraoral periapical radiographs and orthopantomograms for each dental region were assessed. **Results:** The study shows that intraoral periapical radiographs in general have a better image quality compared orthopantomograms. **Conclusion:** The result of this study has shown that intraoral periapical radiographs in general have a better image quality compared orthopantomograms.*

Keywords: Image quality, Intraoral radiograph, Orthopantomogram

1. Introduction

Diagnosis is the process of assessing a patient's health as well as ensuing opinions formulated by clinicians. Oral diagnosis is the art of using scientific knowledge to determine the nature of oral diseases and distinguishing it from other diseases⁽¹⁾. Radiography is a well-established procedure in daily dental practice and is still the most basic and an important diagnostic tool available. Radiographs play an integral role in the assessment of periodontal diseases.

Intraoral periapical (IOPA) radiographs form the backbone of imaging for tooth and the periodontium for the general dentist. IOPA radiographs are usually the initially radiographs advised for diagnosis and follow-up of various dentofacial pathologies. The main indications for periapical radiography include detection of periapical infection or inflammation, assessment of the periodontal status, tooth and dentoalveolar fractures, to assess the presence and position of unerupted teeth, assessment of root morphology during endodontic procedures, preoperative assessment and postoperative appraisal of apical surgery and evaluation of implants postoperatively⁽²⁾.

However, a vast group of patients cannot tolerate the intra oral film/ sensor. These include developmentally disabled individuals, those with an exaggerated gag reflex, pediatric dental patients and anxious dental patients. Also, intra oral film/sensor placement may be cumbersome in others like those patients with limited mouth opening, rubber dam or those who have undergone facial trauma^(3,4). In these clinical situations, the essence of the speciality of oral and maxillo-facial radiology comes into picture which is not only about the diagnostic assessment but also equips the clinician with the ability to interpret images of maxillofacial structures. To overcome the difficulty encountered by the clinicians in these situations, Michael Newman and Seymour Friedman⁽³⁾ in 2003 developed an alternative technique which uses an extraoral film/sensor and reported that the patients tolerated the procedure well, preferring the extraoral technique to the conventional IOPA radiography. In 2007, Chia-Hui et al devised a film/sensor beam aiming device for the extra oral periapical (EOPA) radiographic technique to align the X-ray

beam directly at the film/ sensor under the guidance of the locator ring to avoid cone cuts⁽⁵⁾. Kumar et al^(6, 7) have employed the EOPA radiographic technique in various clinical situations and found the EOPA radiographs provided essential diagnostic information.

The orthopantomogram is a radiographic examination extremely useful in all dental specialities: carious lesions and endodontics, periodontology, prosthetics, maxillo-facial surgery, implantology, paediatric dentistry and orthodontics⁽⁸⁾.

The orthopantomogram is an important and complex factor in both diagnosis and prognosis, being often a surprise investigation of unexpected elements of dentomaxillary pathology⁽⁹⁾. After radiological identification of the elements of dental pathology such as presence or absence of teeth, cysts, foreign bodies, disgnation, systemic disease manifested at dentomaxillary level⁽¹⁰⁾, and calcified atheromatous plaques in the carotid artery region^(11, 12), osteonecrosis of the jaw after treatment with bisphosphonates⁽¹³⁾, the medical practitioner is obliged to inform the patient, to modify the first treatment plan established by clinical examination and to apply an appropriate dental treatment, in cooperation with other medical services, for possible therapeutic suggestions^(9,10).

The clinical situations in which orthopantomograms are recommended are the following^(14, 15, 16):

- First examination of new patients with multiple deep carious lesions, with orthodontic and periodontal problems
- Early diagnosis of dental anomalies, to check dentition and to provide a timely diagnosis of the odontogenic tumors or cysts
- Establishing the exact cause of missing teeth
- Radiographic examination of the teeth with endodontic treatment
- Odontogenic sinus disease suspicion
- Disorders of temperomandibular joint caused by malocclusion
- Facial and maxillary asymmetry
- Painful or asymptomatic swelling

Volume 6 Issue 5, May 2017

www.ijsr.net

Licensed Under Creative Commons Attribution CC BY

- Multiple dental extractions, with suspected osteomyelitis
- Examination of non-odontogenic cysts, tumors and tumor-like lesions of bone tumors
- Suspicion of invasive bone tumors or bone metastases
- Mandibular nerve paresthesia
- Unusual sensitivity of teeth, unusual eruption, spacing or migration of teeth
- Radiographic examination of the oromaxillo-facial area in systemic diseases and syndromes
- Maxillo-facial fractures and suspected post-traumatic fractures
- Before and after surgery in the oromaxillo-facial surgery.

Orthopantomogram may overcome some of the limitations of IOPA, but has certain disadvantages, such as higher radiation dose, greater cost, image magnification, reduced image resolution and limited availability in the dental offices, greater cost and often it becomes impossible to make young patient stand still for panoramic radiographs^(1, 17).

With increasing awareness of the need for radiation protection, a paradigm shift can be observed from the principle of “image quality as good as possible” to “image quality as good as needed.” The radiation dose to patients should be as low as reasonably achievable (ALARA) while still providing image quality adequate to enable an accurate diagnosis^(18, 19). ALARA does not necessarily mean the lowest radiation dose, nor, when implemented, does it result in the least desirable radiographic image⁽²⁰⁾. What, indeed, constitutes adequate image quality is still open for discussion for the various imaging tasks. There is a multitude of studies in the literature comparing the performance of one system with another “reference” system to define the amount of possible dose reduction that would still achieve an image quality equivalent to that provided by the acknowledged reference. Using this approach, it is possible to survey parameters, such as the detection of artificial lesions or the semi-quantitative assessment of subjective image impression, as a surrogate for image quality and relate these parameters to a reference of dose. To define, however, the minimum level of image quality needed to reliably make a certain type of diagnosis is much more difficult. Individually defining the minimal dose to reliably answer a specific diagnostic question in a prospective manner seems to be impossible, given the vast variety of patient-related and disease-related conditions and the workflow for radiographic examinations.

Reduction of patient dose according to the ALARA principle is not only a question of selecting the right detector, but also requires the optimisation of the whole imaging chain and the selection of appropriate imaging parameters.

To implement the ALARA principle, a number of international work groups introduced the concept of image quality classes (Table 1 and Table 2)^(18, 19, 21). Three levels of image quality (high, medium, and low) and, accordingly, three dose levels (corresponding to speed classes 400, 800, and 1600) were suggested, dependent on the demands of the diagnostic question. Such a “pre-examination” classification of required image quality would mean that existing referral

guidelines would require an additional parameter, such as “image quality class,” although it has to be clearly stated that the responsibility for such a classification should be in the hands of the radiologists. Based on the different dose efficiency of existing intraoral periapical radiographic equipment, ALARA would also mean that, for the same clinical question, different exposure parameters must be applied, dependent on the radiographic equipment used. Evaluations of phantom images showed that a “medium class image quality” provided by a film/screen image with a speed class of 400 was achievable by a storage phosphor system (CR systems using a powder storage phosphor plate with a single-sided read-out) with doses equivalent of speed 200 and 400 and a flat panel system (DR system using a CsI/TFT detector) at a dose equivalent of speed 1600 or 25% of the dose⁽²²⁾.

Table 1: Image quality classes. Examples for different levels dependent on given clinical indications

Image quality	Clinical indication
High	- Primary bone tumour
	- Non-displaced fracture
Medium	- Lumbar spine in two projections in patients with chronic back pain with no pointers to infection or neoplasm
	- Control of a known displaced fracture
Low	- Control after metal implantation for osteosynthesis
	- Follow-up of pneumonia in adults
	- Follow-up in longitudinal studies, e.g., in patients with scoliosis

Table 2: Relationship between image quality classes and dose requirements of different radiography systems

Image quality class		
High	Medium	Low
DR (400)	DR (800)	DR (1600)
CR (200/400)	CR (400)	CR (800)
Film-screen system (200)	Film-screen system (400)	Film-screen system (800)

Keywords: Image quality, Intraoral radiograph, Orthopantomogram

2. Materials and Methods

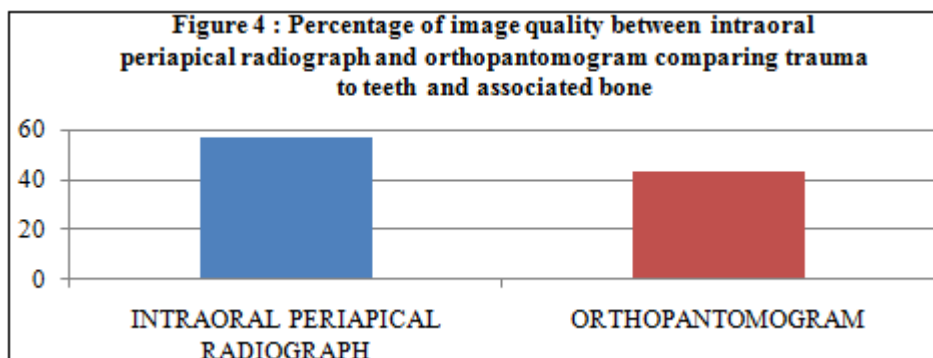
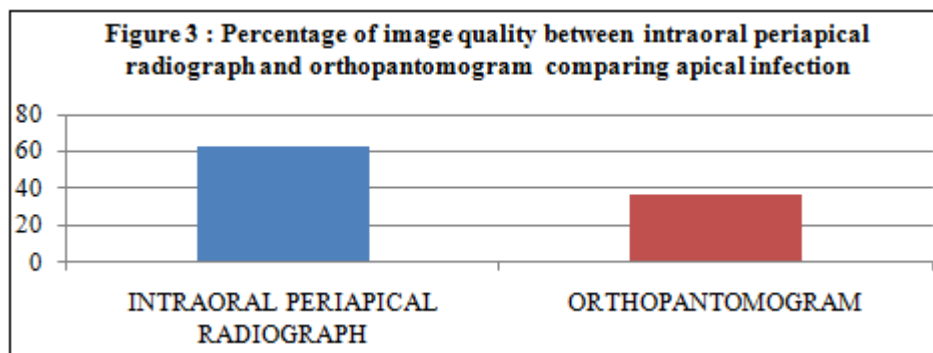
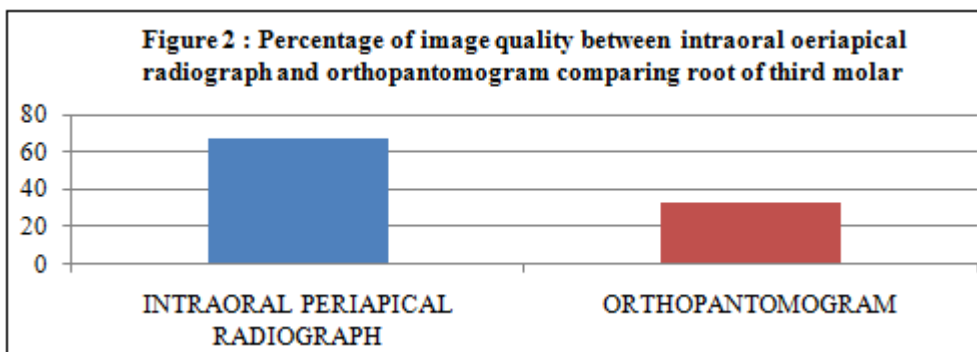
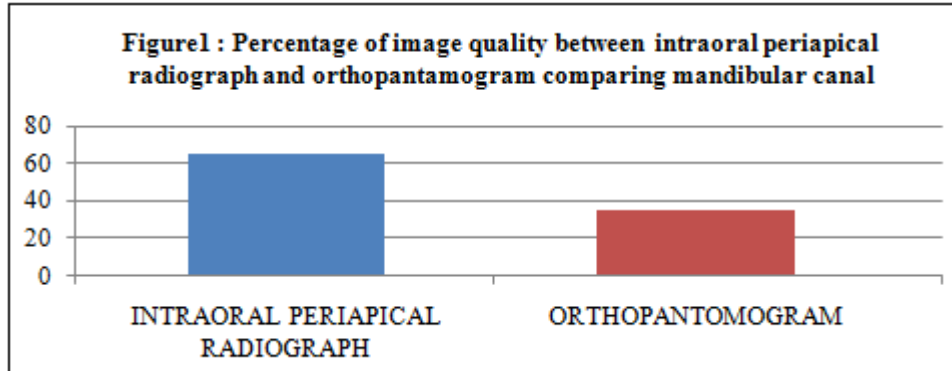
The study is to be carried out on 50 patients. Intraoral periapical radiographs and orthopantomograms are obtained. All measurements performed by an oral radiologist. Intraoral periapical radiographs were taken with the film holder provided by Kodak RVG 6100 intraoral periapical radiography system (Carestream Health[®], Rochester, NY, USA). The intraoral periapical radiographs was measured using the equipment's own software (Kodak Dental Imaging 6.1, Carestream Health[®], Rochester, NY, USA). The files are saved according to the manufacturer's specifications. An IOPA X-ray machine was used to take the radiographs at setting of 60kv-7Ma for 0.45-0.55 seconds.

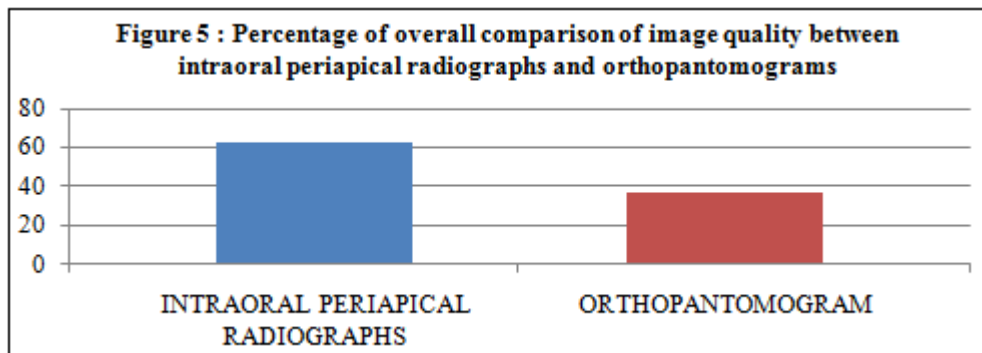
Orthopantomograms were obtained with a conventional X-ray machine (Orthoralix 9200 GENDEX, Dentsply[®], Des Plaines, USA) using Kodak T-Mat G/RA films (15 × 30 cm, Carestream Health[®], New York, USA) with their metallic cassette and intensifying screen (Kodak Lanex

Medium Extraoral Imaging Screens X-Omat). Using alignment lights, the mid sagittal plane of the mandibles was positioned perpendicularly to the ground and the occlusal plane parallel to the ground. The panoramic radiographs were taken at setting of 7 mA with a peak tube potential of 60 kV depending on the subject's jaw size.

The radiographs were evaluated by 50 observers. The image quality of both intraoral periapical radiographs and orthopantomograms for few selected dental region such as mandibular canal, root of third molar, apical infection and trauma to teeth and associated bone were assessed.

3. Results





The study shows that intraoral periapical radiographs in general have a better image quality compared orthopantomograms.

4. Discussion

The participants consisted of 50 dental students.

In the Figure 1, consist of 24 images comparing the appearance of mandibular canal, which are 12intraoral periapical radiographs and 12orthopantomograms. There was 65.2% voted for intraoral periapical radiograph have a better image than orthopantomogram. Followed by 34.8% voted for orthopantomogram has better image than intraoral periapical radiograph.

In the Figure 2, consist of 26 images comparing appearance of the root of the third molar, which are 13intraoral periapical radiographs and 13 orthopantomogram. There was 67.4% voted for intraoral periapical radiograph which has better image than orthopantomogram. 32.6% thought that orthopantomogram is better.

For all the observers, in the Figure 3, was found consist of 26 images comparing the appearance of apical infection which the 13 intraoral periapical radiographs and 13 orthopantomogram showed the result that intraoral periapical radiograph have the better image which was 63%, however there was 37% thought that orthopantomogram has better quality than intraoral periapical radiographs.

At last, in the Figure 4, 24 images comparing the appearance of trauma to teeth and associated bone between 12 intraoral periapical radiograph and 12 orthopantomogram reported that there was 56.5% observers voted for intraoral periapical radiograph has better image. However it was reported that there was 43.5% votes for orthopantomogram.

With regard to overall comparison of image quality betweenintraoral periapical radiographs and orthopantomograms, in the Figure 5 showed that intraoral periapical radiographs has the higher percentage compared to orthopantomogram which was 63.025%.

Given the present research, it is clear that intraoral periapical radiographs in general have a better image quality compared orthopantomograms.

5. Conclusion

The result of this study has shown that intraoral periapical radiographs in general have a better image quality compared orthopantomograms. Intraoral periapical radiograph is a well-accepted diagnostic tool in dental practice. Comparison between intraoral periapical radiographs and orthopantomograms for root canal length determination and measurement of endodontic files of different sizes has been previously performed and it is better to recommend the use of the intraoral periapical radiographs because of the possibility of reducing the patient's exposure to ionizing radiation. Since the intraoral periapical radiographs seems to have good image quality, it may contribute to better radio diagnosis. Intraoral periapical radiographs is an efficient technique, in both economic and diagnostic sense. However, this imaging technique, like any other, needs to be studied continuously, with the emphasis on safety of patients and diagnostic quality of the images.

References

- [1] Khocht A, Janal M, Harasty L, Chang KM; Comparison of direct digital and conventional intraoral radiographs in detecting alveolar bone loss. J Am Dent Assc, 2003; 134: 1468-1475.
- [2] Whaites E. Periapical radiography. In: Parkinson M, editor. Essentials of Dental Radiography and Radiology. 3rd ed. Philadelphia: Churchill Livingstone, An imprint of Elsevier Science Limited;2002. Pg. 161-76.
- [3] Newman ME, Friedman S. Extraoral radiographic technique: An alternative approach. J Endod. 2003;29(6):419-21.
- [4] Ingle JI, Bakland LK, Baumgartner JC. Endodontics. 6th ed. Ontario: BC Decker Inc; 2008.
- [5] Chen CH, Lin SH, Chiu HL, Lin YJ, Chen YK, Lin LM. An aiming device for an extra oral radiographic technique. J Endod. 2007;33(6): 758-60.
- [6] Kumar R, Khambete N, Priya E. Extraoral periapical radiography: an alternative approach to intraoral periapical radiography. Imaging Sci Dent. 2011;41(4):161-5.
- [7] Kumar R, Khambete N. Use of extraoral periapical radiography in Indian population: technique and case reports. Indian J Dent Res. 2013;24(2):271-3.
- [8] Login S. – Tehnic\ radiologic\ dentar\ . Ed. Univ., Buc., 2000.
- [9] MilicescuViorica – Ortopantomogramaînpracticastomatologic\, Curs postuniversitar, Buc., UNAS, iunie 2006.

- [10] Rushton Vivian, Horner K., Worthington HV. – Panoramic Radiology, Quintessence, London, 2005.
- [11] Griniatsos J, Damaskos S. sicolab. – Correlation of calcified carotid plaques detected by panoramic radiograph with risk factors for stroke development. Oral Surg Oral Med Oral Pathol Oral Radiol Endod. 2009, 13.
- [12] Masood F, Wild RC sicolab. – Presence of carotid artery calcification on panoramic radiographs of patients with chronic diseases. Gen Dent. 2009; 57(1): 39-44.
- [13] Treister N, Sheehy N sicolab. - Dental panoramic radiographic evaluation in bisphosphonate-associated osteonecrosis of the jaws. Oral Dis. 2009; 15(1): 88-92.
- [14] Farman A.G. – Panoramic Radiology-Seminars on Maxillo-facial Imaging and Interpretation, Ed. Springer, 2007.
- [15] Pasler F.A. – Color Atlas of Dental Medicine Radiology, Ed. Thieme,1993.
- [16] Whaites E. – Essential of dental radiography and radiology. Fourth Edition, Churchill Livingstone Elsevier, 2007.
- [17] Sujatha SR, Atul K, Shrilekha R, Kunal A. Clinical applications of reverse panoramic radiography. Dent Hypotheses 2011; 2:190-8.
- [18] Managing patient dose in digital radiology. ICRP Publication 93. Elsevier: ICRP; 2004.
- [19] 1990 Recommendation of the international commission on radiological protection—users’ edition. ICRP Publication 60. Oxford: ICRP: Pergamon Press; 1992.
- [20] Seibert JA. Tradeoffs between image quality and dose. PediatrRadiol 2004;34(suppl. 3):S183–95 [discussion S234–141].
- [21] Busch HP, Busch S, Decker C, Schilz C. Image quality and exposure dose in digital projection radiography. Rofo 2003;175:32–7.
- [22] Busch HP, Faulkner K. Image quality and dose management in intraoral periapical radiography: a new paradigm for optimisation. Radiat Prot Dosimetry 2005;117: 143–7.