

# Milk-Alkali Syndrome in a Child with Primary Hypoparathyroidism during Maintenance Therapy

Magbul H. Maghfuri<sup>1</sup>, Magda A. Khazbak<sup>2</sup>, Mariam A. Belail<sup>3</sup>, Alaa A. Hakami<sup>4</sup>, Musa Y. Hakami<sup>5</sup>, Fahad Y. Somili<sup>6</sup>, Fatmah Y. Gumiry<sup>7</sup>, Amal M. Daghri<sup>8</sup>, Mohammed A. Alameer<sup>9</sup>, Amnah A. Shubayli<sup>10</sup>, Sabreen M. Asiry<sup>11</sup>, Najwa A. Omara<sup>12</sup>

<sup>1</sup>Consultant Pediatric Nephrologist, Saudi Commission for Health Specialties, and Head of Pediatric Department of King Fahd Central Hospital – Jazan at KSA

<sup>2</sup>Consultant Pediatrician, Saudi Commission for Health Specialties and professor of pediatrics

<sup>3</sup>Pediatric Nephrology Specialist, Saudi Commission for Health Specialties

<sup>4-11</sup> Pediatric Program Resident, Saudi Commission for Health Specialties

<sup>12</sup>Pediatric Nephrology Hemodialysis Resident, Saudi Commission for Health Specialties  
 [All from pediatric department of King Fahd Central Hospital – Jazan, KSA]

**Abstract:** Calcium plays a critical role in neuromuscular excitement and other cellular functions. Therefore, extracellular calcium concentration is maintained within a very narrow range through interaction of calcium regulating hormones such as parathyroid hormone, calcitonin, and vitamin D in the presence of normal renal function. Special attention should be paid to patients on vitamin D and calcium supplementation in situations of dehydration and/or renal insufficiency, even though the usual dose of these supplements are unchanged over time. We report a case presenting with a triad of hypercalcemia, metabolic alkalosis and renal failure secondary to treatment of primary hypoparathyroidism.

**Keywords:** Hypercalcemia, Hypoparathyroidism, Milk –alkali syndrome, Calcium.

## 1. Background

Milk-alkali syndrome is caused by the ingestion of large amounts of calcium and absorbable alkali, with resulting

hypercalcemia [serum calcium >2.6 mmol/L] (figure 1). If untreated it can lead to metastatic calcification and renal failure.

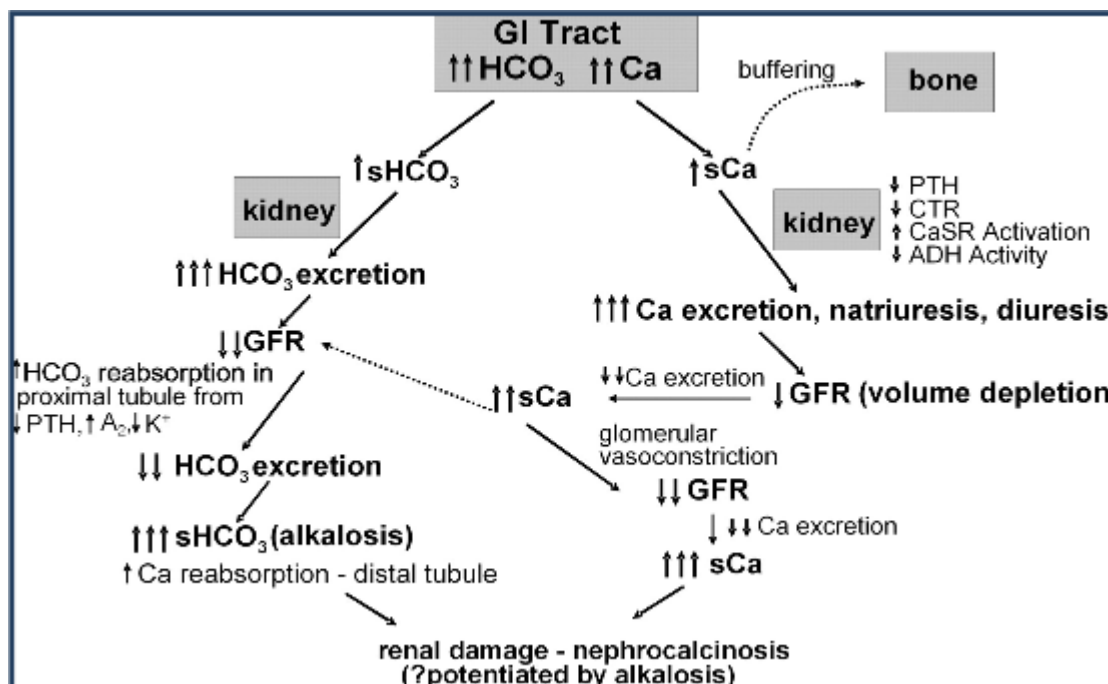


Figure 1: Pathogenesis of milk-alkali syndrome

This syndrome was initially recognized more than 100 years ago when Sippy described his regimen of treatment of peptic ulcer disease by administration of milk and bicarbonate. [1]

With the development of nonabsorbable alkali and H2 blockers for treatment of peptic ulcer disease, milk-alkali syndrome became a rare cause of hypercalcemia. [2,3].

Resurgence of this syndrome has occurred with the increased use of calcium carbonate and calcium supplements. Milk-alkali syndrome is now the third most common cause of hypercalcemia in hospitalized patients [4,5].

## 2. Case Summary

We present a 13-year-old Saudi boy, of consanguineous parents, and a family with history of renal stones and ESRD affecting his uncle. He is a known case of hypoparathyroidism, was diagnosed 2 years back when he presented with a febrile generalized tonic convulsions, associated with up-rolling of eyes and twitching of face. During this attack, his level of consciousness was preserved. He was then admitted to peripheral hospital for observation and further evaluation for 5 days. Serum electrolytes showed hypocalcemia 1.5mmol/L, and management of hypocalcemia given. On 6<sup>th</sup> day of admission he developed uncontrolled convulsions that required urgent referral to our hospital, where he was investigated and diagnosed as case of primary hypoparathyroidism.

He was discharged on supplements (oral calcium gluconate 1.437 gram POq 6 hours, magnesium oxide 1200 mg POq 6 hours, alfacalcidol 1 microgram orally twice daily) and he was referred to tertiary center for further evaluation. Case was accepted at a tertiary center in Riyadh, where he was admitted for further investigations. They diagnosed the case as hypocalcemia due to primary hypoparathyroidism, hypomagnesemia, mild nephrocalcinosis and suspected hypocalcemic hypomagnesemic hypercalciuria and they continued same management.

After 6 months of following there at the higher center as an outpatient, patient was referred to pediatric nephrology team in our hospital. Since then patient had frequent attacks of symptomatic hypocalcemia (admitted three times with tremors, numbness, hypocalcemia and hypomagnesemia), following bouts of diarrhea and/or vomiting.

Last admission to our hospital, patient presented with dehydration. Otherwise, physical examination was unremarkable apart of being underweight at 10<sup>th</sup> centile on growth chart. When investigated his serum calcium was high 3.21 mmol/L, serum magnesium was normal 0.83mmol/L, serum creatinine was high 187u MOL/L, high BUN, high to normal serum phosphorus, normal vitamin D serum level, and low parathyroid hormone. Abdominal US, CT- chest and abdomen: NAD. Case had hypercalcemia, metabolic alkalosis and acute renal failure, so diagnosed by pediatric nephrologist as milk-alkali syndrome.

## 3. Discussion

This child presented with the classical triad of hypercalcemia, metabolic alkalosis and renal impairment. This fulfills the criteria of milk-alkali syndrome [6]. In the absence of any other identifiable cause of hypercalcemia, this could be attributed to his treatment of primary hypoparathyroidism. [7]. He has been on this

treatment regularly for the last two years, with good compliance. However, he suffered bouts of manifest tetany, following each attack of recurrent gastroenteritis, and that also caused him to be admitted to hospital until his serum calcium could be raised, corrected and stabilized. Lately, he was admitted with hypercalcemia, alkalosis and renal impairment for the first time during his follow up course, while maintained on same medication, same dosage.

To the best of our knowledge, very few similar cases were described in the literature. One of them was described in Turkey from department of nephrology Cukurova University, Adana, and published in Indian J Endocrinol Metab, 2013 [8]. The other case was a Korean adult patient with post-operative hypoparathyroidism. She developed milk-alkali syndrome during her long-term maintenance therapy with calcium supplement [9].

Of note is the corrected serum calcium at 3.21 mmol/L. We excluded other causes of hypercalcemia. There was no evidence of cancer on both CT chest and abdomen [figure 2&3]. (No thiazide diuretic prescribed to the patient for any reason and no other drugs that may contribute to hypercalcemia). Excessive intake of oral calcium or vitamin D was ruled out by meticulous history taking, and during admission. Our patient was only receiving his regular dose of oral alfacalcidol and oral calcium for treatment of hypoparathyroidism.

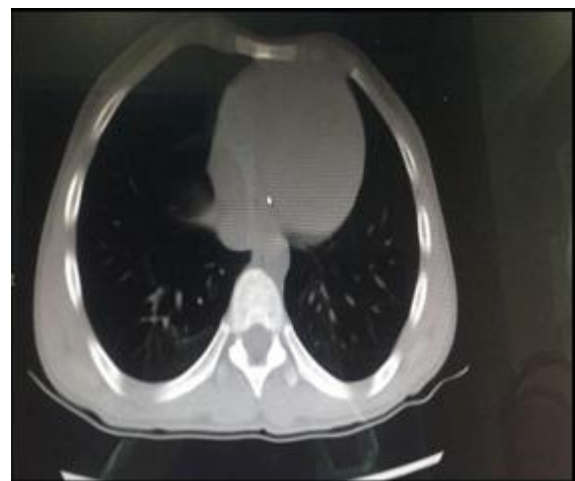

Figure 2: Patient CT-chest

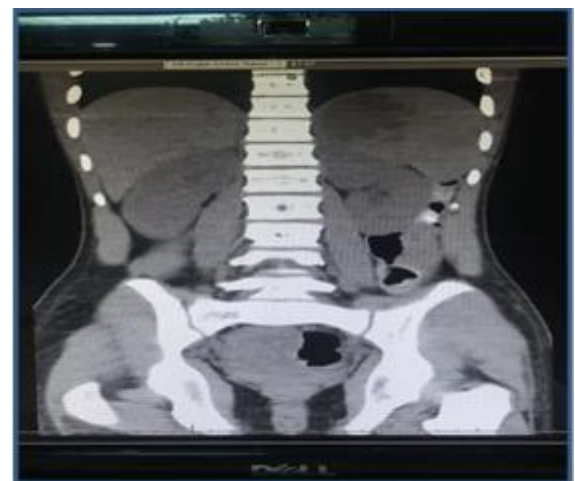


Figure 3: Patient CT- abdomen

This patient presented with recurrent diarrhea and vomiting. This gastrointestinal loss of magnesium could have attributed to his primary hypoparathyroidism which aggravated his hypocalcemia due to hypercalcuria. Each attack of manifest tetany was following a bout of gastroenteritis, which supports this assumption. In the deficiency of parathormone, bone resorption, phosphaturic effect, renal distal tubular calcium reabsorption, and 1,25-dihydroxy vitamin D-mediated dietary calcium absorption, all are deficient. Therefore, the consequence is hypocalcemia. Primary hypoparathyroidism is defined by a low concentration of PTH with a concomitant low calcium level. The measurement of serum 25-hydroxy vitamin D was normal to exclude vitamin D deficiency as a cause of hypocalcemia.[10]

Parathormone is a phosphaturic hormone. In its deficiency, phosphorus levels in the blood rise. Our patient had near-normal serum level of phosphorus most of the time.

Avid absorption of large doses of calcium leads to more suppression of parathyroid hormone which then leads to enhanced bicarbonate retention by the kidney adding more to alkalosis which leads to an increase in renal reabsorption of calcium. Hypercalcemia deteriorates renal function through dehydration due to polyuria and renal vasoconstriction resulting in decreased glomerular filtration rate. Vice versa, dehydration can raise serum calcium.[11]. So, a vicious circle ensues.

#### 4. Conclusion

A meticulous follow up of serum calcium, phosphorus, magnesium, renal function test and blood gas is mandatory for any patient with primary hypothyroidism on calcium and vitamin D therapy. His therapy could initiate milk-alkali syndrome, especially in presence of dehydration, and underlying kidney pathology.

#### References

- [1] Sippy BW. Gastric and duodenal ulcer medical care by an efficient removal of gastric juice corrosion. *JAMA*. 1915;64:1625-1630.
- [2] Ariyan CE, Sosa JA. Assessment and management of patients with abnormal calcium. *Crit Care Med*. 2004 Apr; 32(4 Suppl):S146-54.
- [3] Dent DM, Miller JL, Klaff L, Barron J. The incidence and causes of hypercalcaemia. *Postgrad Med J*. 1987 Sep; 63(743):745-50.
- [4] Edelson GW, Kleerekoper M. Hypercalcemic crisis. *Med Clin North Am*. 1995 Jan; 79(1):79-92.
- [5] Cho KC. Electrolyte & Acid-Base Disorders. Papadakis MA, McPhee SJ, Rabow MW, eds. *CURRENT Medical Diagnosis & Treatment 2013*. New York, NY: McGraw-Hill; 2013. Chapter 21.
- [6] Alpern RJ, Moe OW, Caplan M, Disorder of Calcium Metabolism. eds. *Seldin and Giebisch's The Kidney*. 5th ed. Elsevier; 2013. 2273-309.
- [7] Tal A, Powers K. Milk-alkali syndrome induced by 1,25[OH]<sub>2</sub>D in a patient with hypoparathyroidism. *J Natl Med Assoc*. 1996;88:313-4.

- [8] Altun E, Kaya B, Paydas S, and Balal M. Milk-alkali syndrome induced by calcitriol and calcium bicarbonate in a patient with hypoparathyroidism. *Indian J Endocrinol Metab*. 2013 Oct; 17[Suppl 1]:S191-S193
- [9] Kim Ch S, Kim B, Choi Y S et al. Milk-alkali syndrome in a patient with post-operative hypoparathyroidism during long-term maintenance of calcium supplementation. *Korean J Endocr Surg*. 2014 Jun; 14[2]:85-88.
- [10] Grubb M, Gaurav K, and Panda M. Milk-alkali syndrome in a middle-aged woman after ingesting large doses of calcium carbonate: A case report. *Cases Journal*. 2009; 2:8198
- [11] Bazari H., Palmer W H, Baron J M, and Armstrong K. A 66-Year-Old Man with Malaise, Weakness, and Hypercalcemia. *N Engl J Med* 2016; 375:567-574.