

Polydactyly in Two Siblings with Overwhelming Family History – 2 Case Reports

Dr Shadrack G Lungu

(BScHB, MBChB, MMed(Orth), FFCSECSA, Senior Consultant Orthopaedic & Trauma Surgeon, Private Bag (C) 2000 KCM, South Hospital, Chingola, Zambia

Abstract: Polydactyly is one of the commonest deformities in the hands and feet. It is caused by sporadic etiology, but hereditary causes especially in the Africa American racial group. It is predominantly an autosomal penetrance. The two cases presented here are from a family of four children all with a similar condition, with a unique and overwhelming family history that spans five generations.

Keywords: Polydactyly, family history, five generations

A full consent from the parents (father and mother) was obtained not only for the surgery but the publication including the pictures herein.

1. Patient 1

SM was 1 year and 11 months old. She was visiting the Orthopaedic Surgeon for the second time (follow up). This was a patient who first presented to the surgeon after the upper limb extra digits had been tied off by the attending midwives despite the fact that the extra-digits were fully formed with a definite well-formed skeleton structure. Both feet had extra-digits which had lateral syndactyly bilaterally. An elective procedure was planned in consultation with the anaesthetic team.

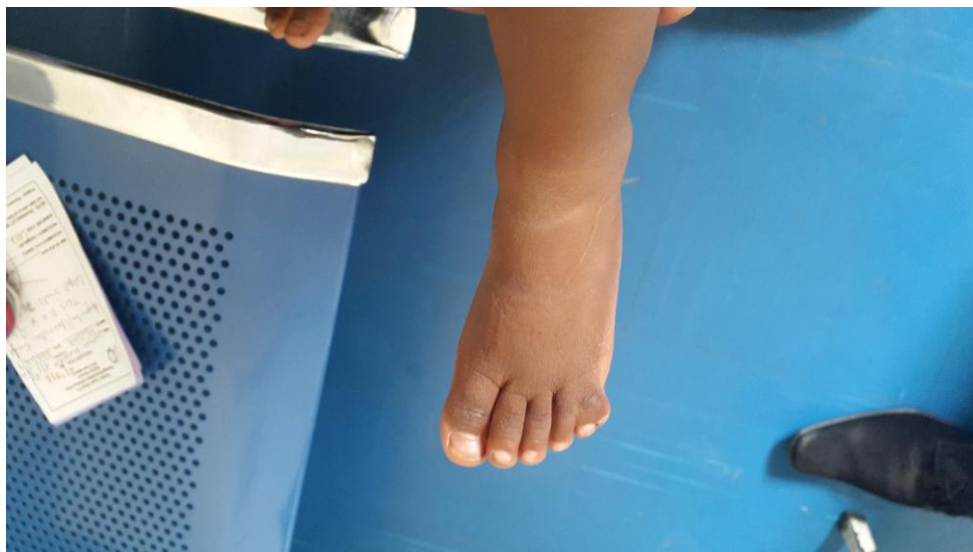The Obstetric and neonatal history was uneventful. A hospital delivery was conducted and the baby's birth weight was 3.2kg with a good APGAR score of 9/10 in the first minute. The deformities were noticed at birth by the attending midwife. The child was later referred to the

Orthopaedic Surgeon after the Paediatrician had seen the child. The past medical history was not significant but the family and social economic history were as elucidated in the Patient 2 below.

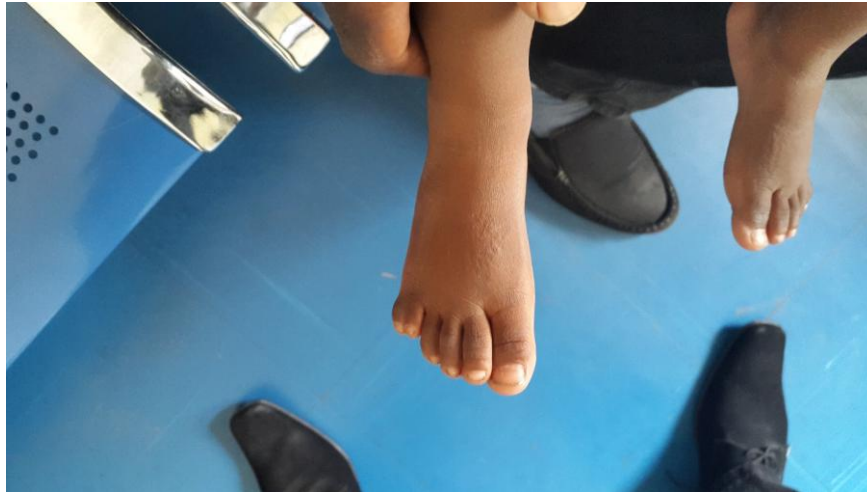The parents were planning to get the child into nursery-school the following year.

During the second visit, SM had attained normal milestones for her age and was walking without any support. Her body weight was 9.3kg and the height 79cm. Vital signs and systemic examination were normal. The local examination revealed remnant scarred stubs medially on the little fingers bilaterally. The little toes still had extra-digits with the left showing a more severe syndactyly than the right.

The blood investigations were normal while the radiological results showed and confirmed the clinical diagnosis with full skeletal formation in the extradigits. Ultrasound scan of the chest and the abdomen was not significant.



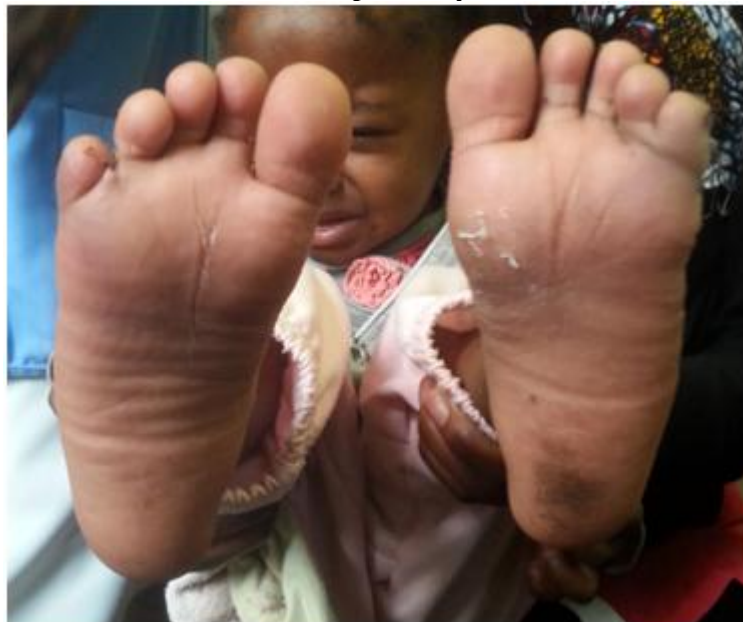Pre-op: Left foot



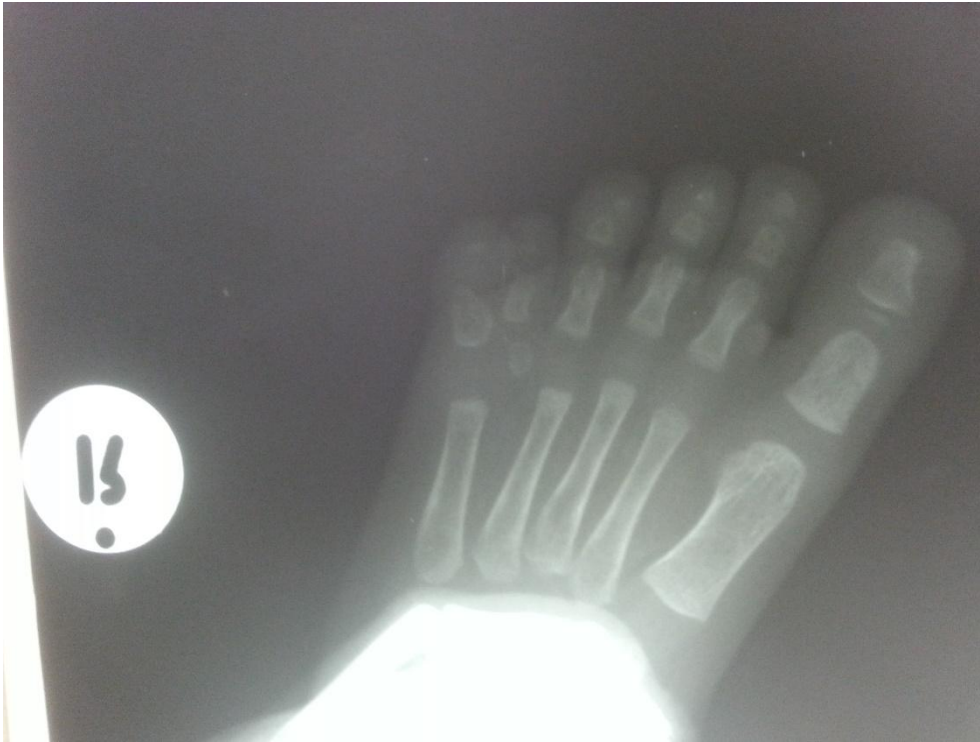Pre-op: Right foot



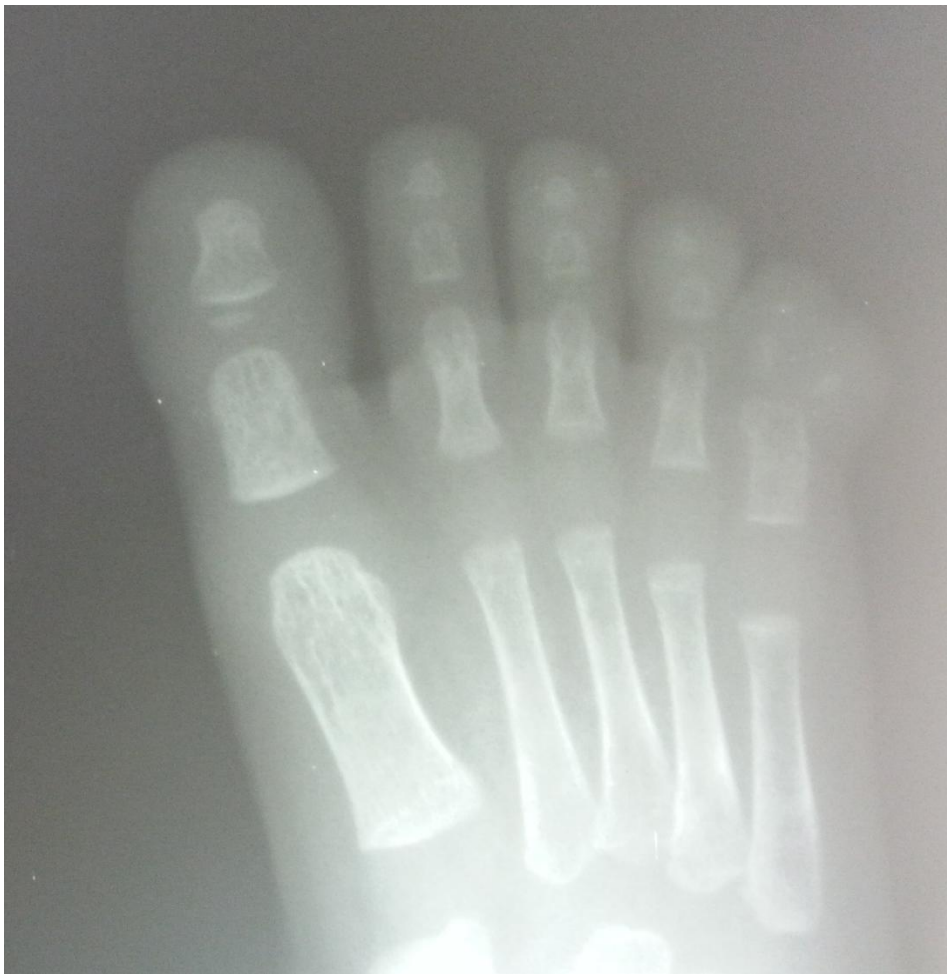Post op – 10 days



Post of – 10 days



Radiograph: Patient 1 Right side



Radiograph: Patient 1 Left side

2. Patient 2

PM, was a two months old baby who presented to our Orthopaedic specialist clinic with his mother of 29 years of age. He was a fourth born in a family of four siblings. All the children were from the same parents (father and mother). He was the only boy. The pregnancy of PM was full term and uneventful. He was delivered at the hospital and his APGAR score in the first minute was 9/10. The birth weight was 3.38kgs. He was in a good state of health and was feeding and growing well although the child had a two days history of flue (at the time of consultation).

The deformities were noticed at birth by the midwife who later referred the patient to the Paediatrician; who in turn referred the baby to the Orthopaedic Surgeon.

Systemic review was normal.

His past medical and social history were not significant except that he was born in the hospital and into average urban cost family.

3. Family History

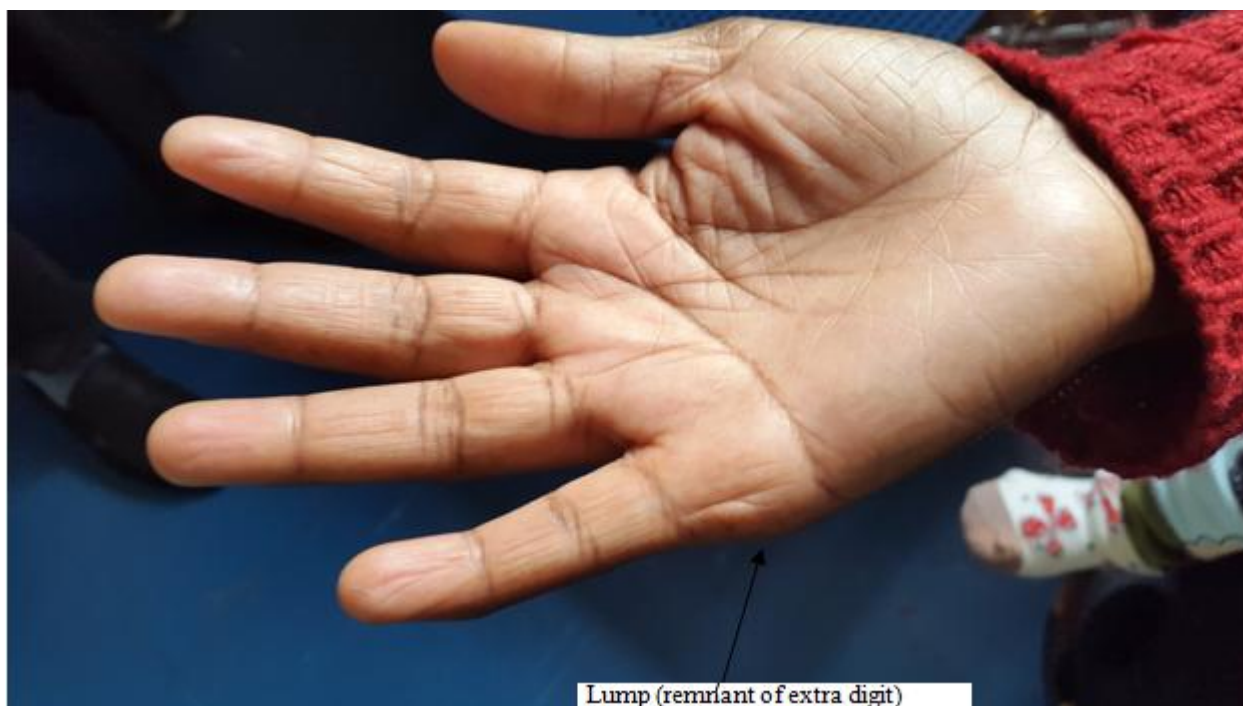There was a very strong family history of polydactyly on the maternal side. The three elder sisters to the patient suffered extra-digits in all fours. The mother too had the same condition on the medial aspects of her hands only (on the little fingers). The mother of both patients was the eldest in a family of three siblings, one of which was a man. The patient's immediate uncle did not have this abnormality. He however had a son with bilateral polydactyly on the hands (a cousin to our patients). The patient's aunt (last born in the patient's mother's family) equally had the same condition on both hands. The daughter to this auntie (patient's female cousin) equally suffered from the same condition.

The father of the above two patients, however, did not have this condition and neither was it present in his family.

The patients' maternal great-great grandfather and grand-uncles also suffered polydactyly in both upper and lower limbs. The two grand aunts suffered polydactyly on the hands only. This condition manifested itself in five generations; affecting brothers and sisters, cousins, aunts, uncles, grandfather plus grand-uncles and aunts; great-grandfather and great-great-grandfather in one family tree. On the other hand, the great-grandmother of the patients did not have the condition but her younger sister bore children with the same condition and the condition cascaded downwards to the patients' great-grand-aunts; grand aunts; aunts and cousins. This was a second family tree which span over four generations.

What was interesting was that the great grandmother lived not too far from the patients' great-grand father before their grandparents married. These two family trees still exist (live) in the same province and their villages are not too far from each other in the Luapula Province of Zambia. The grandfather to the patients was equally interrogated and what was not established from him was that he did not know whether or not there were intermarriages between the two family trees.

Those of the family members that had extra-digits on the feet had rudimentary spots on the hands that signified the failed extra digit. This was the case in the mother and many others in their family. The reverse was true for those that had the fully grown extra digits on the hands showed remnants of failed-developed extra digits on the feet. The majority however, of the sufferers in the extended family had all the limbs affected. There was evidence of remnants of the same in the patients' mother's both hands (*see picture below*).

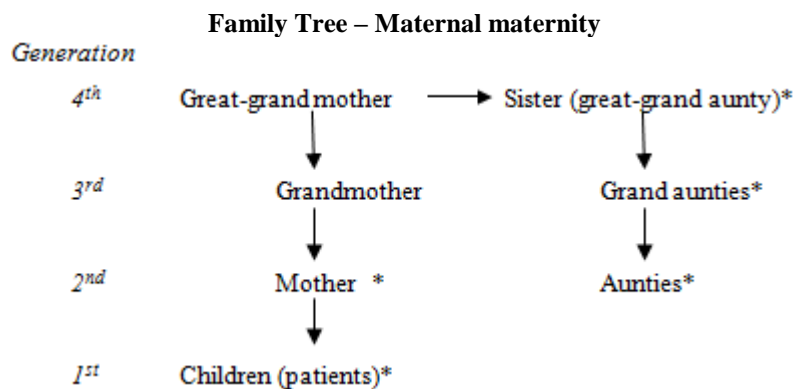
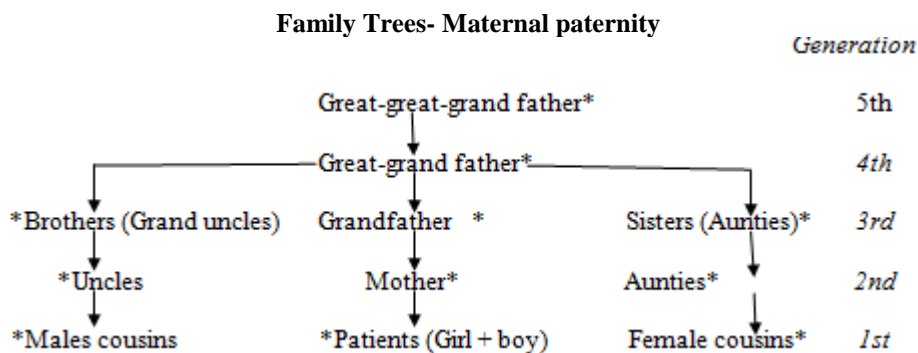


Mother's right hand (Volar aspect)



Mother's right hand (Dorsal aspect)

Lump (remnant of an extra digit)

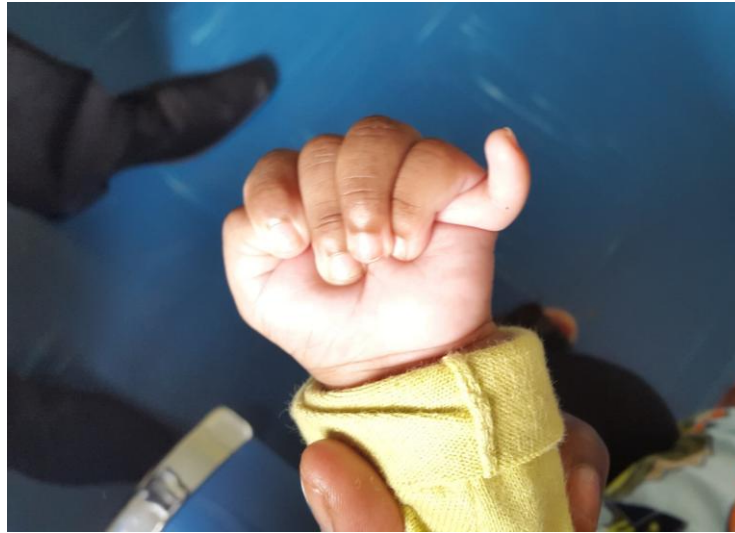

Of note, there are only females in the second family tree. There are two aunties to the patients who don't have their own children yet. The asterisk (*) indicates the sufferers in the chain or family tree.

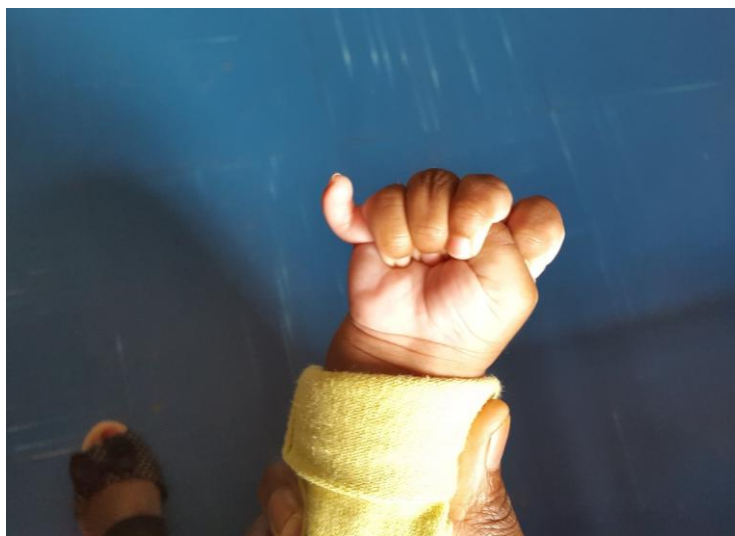On physical examination, the child did not have any other physical observable deformities anywhere else. The vital signs and general examination were within normal limits. The lips, oral cavity and the spine were normal too. His weight was 7.5kg appropriate for the age. He was not pale or jaundiced. The primitive reflexes, moro's and parachute,

were normal. The systemic examination was normal except for the local examinations of both hands and feet that revealed polydactyly on the medial (ulna ray) and lateral (fibula ray) rays respectively.

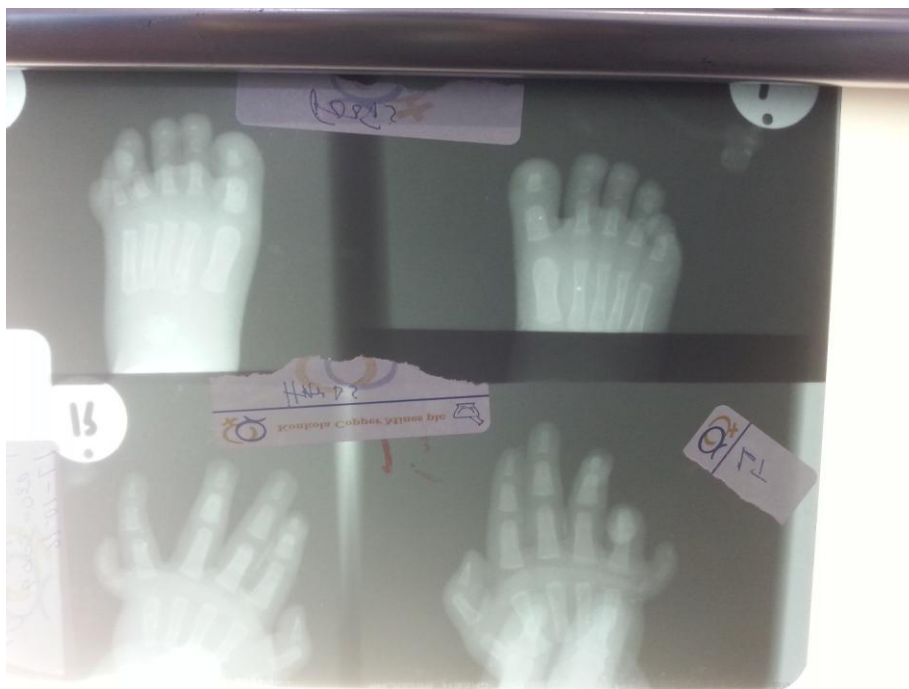The blood profile and ultrasound for the chest and abdominal organs were normal. The radiographs of the affected appendages confirmed the clinical diagnosis. The extra digits had well-formed bones.



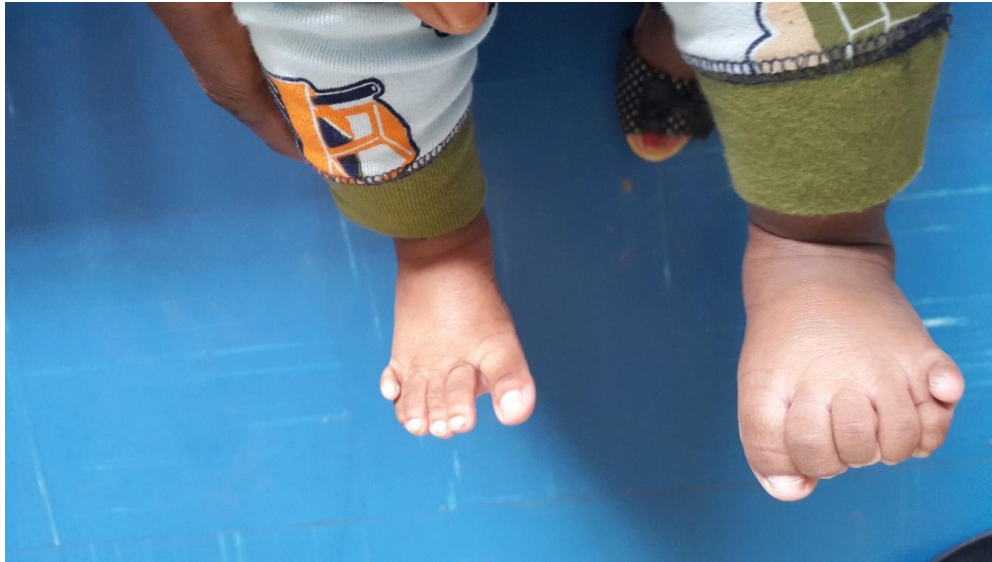Right hand



Left hand

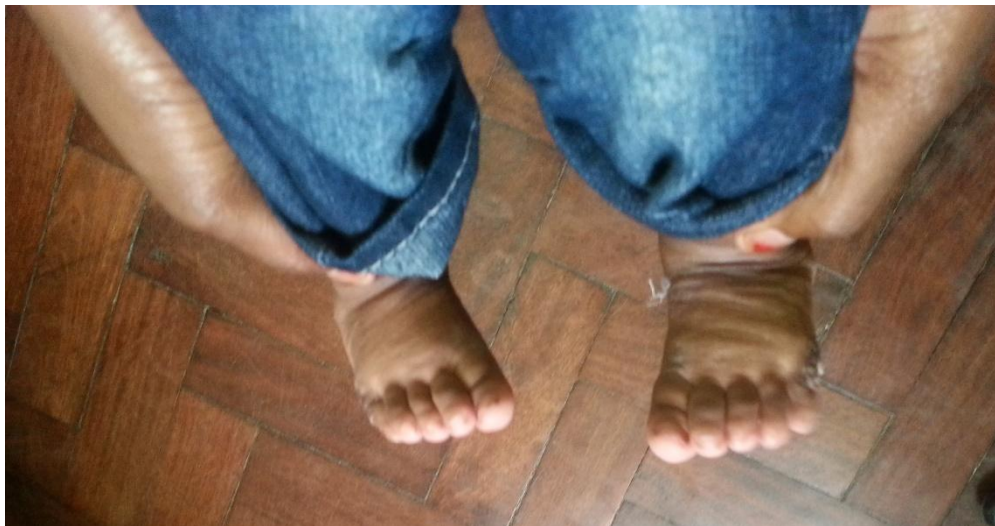

Patient 2: Pre-op Radiographs

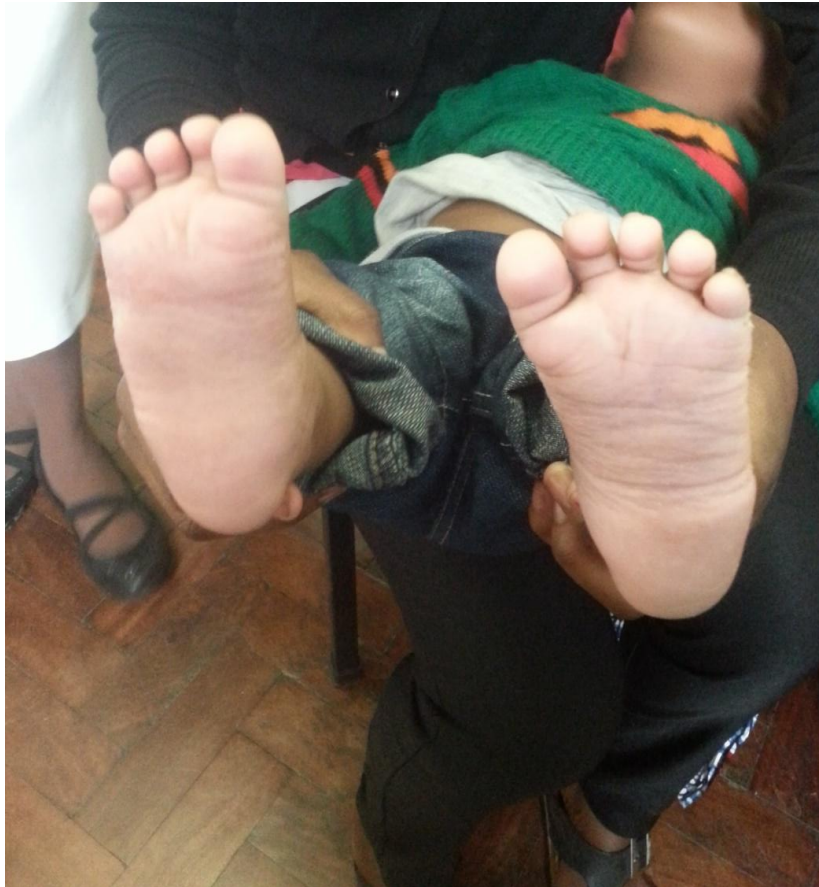

Both feet (Pre-op: Patient 2)

4. Post-operative Pictures



Dorsal view



Plantar aspect (Patient 2)

Treatment

The mother requested to have the excision of the extra-digits at the same time as the elder sister's (Patient 1)

The patients were booked for the anaesthetic clinic and subsequent surgery. Surgeries for both the patients and their recovery were uneventful. They were ultimately discharged from the clinic ten days later.

5. Literature Review

Polydactyly is having more than the normal amount of fingers or toes^{1,2,3,4,5,6}. It is the most common of hand disabilities⁶. Having an extra finger or toe is called polydactyly (pahl-ee-DAK-til-ee)^{3,4}. It can also be called polydactylia, polydactilism, or hyperdactyly⁶. Polydactyly is also called supernumerary digit. "Supernumerary" means "more than the normal number"^{1,3}. It most commonly refers to the presence of six toes on one foot, but more toes are possible². Having extra fingers or toes (6 or more) can occur on its own¹. There may not be any other symptoms or disease present¹. It most frequently occurs as an isolated trait with autosomal dominant inheritance and variable penetrance^{2,6}. Other patterns of inheritance, sporadic occurrence, and association with syndromes are also possible². Most cases are isolated and not related to any other disorder⁵. Polydactyly may be passed down in families¹. This trait involves only one gene that can cause several variations¹. Polydactyly may be associated with syndactyly². Extra digits may be poorly developed and attached by a small stalk. This most often occurs on the little finger side of the hand¹. Poorly formed digits are usually

removed¹ by simply tying a tight string around the stalk which can cause it to fall off in time if there are no bones in the digit¹. In some cases, the extra digits may be well-formed and can even function¹. Larger digits may need surgery to be removed¹.

The extra digit may range from a small, raised bump to a complete, working finger or toe³. Most of the time, it's smaller than the other digits and not well formed³. Sometimes the extra digit is only skin (a nubbin), and it connects to the hand or foot with only a narrow stalk of tissue^{1,3}. If the digit is better formed, it may have all the normal tissues - such as bone, muscles, blood vessels and nerves³. In this case, it connects to the hand or foot deep inside³.

Polydactyly may occur as an isolated trait or in conjunction with certain syndromes, and there is a positive family history in 30% of cases². Polydactyly happens because of errors to the process of fetal development⁶. The extra digits are because of genetic defects⁶. The usual causes are familial polydactyly (inherited), Ellis-van Creveld Syndrome, Carpenter Syndrome, Trisomy 13 and 21, Rubenstein-Taybi Syndrome, Smith-Lemli-Opitz, Laurence-Moon-Biedl Syndrome, and Asphyxiating Thoracic Dystrophy, Familial polydactyly and tibial hemimelia^{1,2,6}.

Adam et al observed clinical findings in 18 cases of diabetic embryopathy and preaxial hallucal polydactyly to identify the features most suggestive of diabetic embryopathy².

Errors occur during foetal development and they are caused by one of several mutations on a gene that is located on the short arm of chromosome 7⁵. The cause is genetic, in particular, mutations on a specific gene on chromosome 7, and it can occur in generations of families⁵. One gene that can cause polydactyly is GLI3, and it is one of a number of genes that are known to be involved in the patterning of tissues and organs during development of the embryo. It does this by helping to control whether specific genes are turned on or off⁵. That is because GLI3 is a transcriptional repressor, which means that it codes for a protein (in fact a DNA-binding protein) that regulates the expression of one or several genes by decreasing the rate of transcription⁵.

Mutations of the GLI3 gene during development are known to cause/contribute to two types of polydactyly⁵. These are isolated post-axial polydactyly and pre-axial polydactyly^{5,6}. Isolated post-axial polydactyly - which is more common amongst African-Americans and is where the extra digits are located on the small digit side (little finger, little toe) of the hand or foot⁵. The mutations are located in the 7p13 region of the gene. Two other locations on this gene have also been identified as housing mutations that cause polydactyly⁵.

There may be different degrees of polydactyly even within the same family and the same gene⁶.

Pre-axial polydactyly - is more common amongst Asian populations and is where the extra digits are located on the large digit side (thumb/big toe) of the hand or foot^{5,6}. The genetics here are not as clearly defined as post-axial polydactyly, but it is more likely to occur with other congenital abnormalities such as the fusion of skin between some fingers and toes^{5,6}. Other conditions that have polydactyly as a feature include Smith-Lemli-Opitz syndrome and Down syndrome⁵. Mutations in GLI3 appear to be a contributory cause of some cases of pre-axial polydactyly⁵.

According to Arnold P et al, There are several different types of post-axial and pre-axial polydactyly and their classification depends on their location, severity, and functionality. Other genes may also cause polydactyly, including LMBR1⁵. A fuller understanding of how genetic mutations cause polydactyly will be achieved when scientists have worked out all the genes that GLI3 interacts with during development, and the nature of these interactions⁵.

The condition is usually inherited as an autosomal dominant characteristic^{2,6}. This means that the gene is not sex-linked, so females and males are both able to inherit the condition equally. Because the gene is also dominant, a kid with one parent who has the trait will have a fifty percent chance of getting it^{5,6}.

Novick C et al found that proximally placed preaxial hallux polydactyly, particularly when coupled with segmentation anomalies of the spine and tibial hemimelia, is highly suggestive of diabetic embryopathy². They added that diabetes in the mothers pointed to a possible genetic

predisposition interacting with teratogenic effects of poor glycemic control².

African Americans, more than other ethnic groups, can inherit a 6th finger. In most cases, this is not caused by a genetic disease^{1,6}. The incidence of polydactyly is 1.7 cases per 1000 live births. The frequency is higher in blacks (3.6-13.9 cases per 1000 live births) than in whites (0.3-1.3 cases per 1000 live births). Polydactyly is bilateral in 50% of cases and has a slight male predilection².

African Americans inherit six fingers or more often than other ethnicities, but it doesn't show a genetic disease most of the time. However, polydactyly can happen at the same time as a genetic disease⁶. The excess digits can be undeveloped and only attached by a little stalk mostly on the small finger side of the hand or fully formed and working⁶. People with the condition may have a small extra stub or many other fingers or toes. The different ways that polydactyly can affect the hand are one, a small bump on the side of the hand, two, having more than four fingers and a thumb, three, having a finger that hangs by a small amount of skin or a stalk from the hand, and four, having a finger that widens into two fingers in which both fingers are usually smaller⁶. Also, polydactyly can happen at the same time when excess digits are fused together, which is called polysyndactyly⁶. Julia et al writes that polydactyly is thought to be common in humans as a development abnormality; it is reported in 2 out of 1,000 kids. It is an old trait, and except for a quirk in evolution, all animals living in modern times would have seven or eight digits instead of five⁶. The oldest animals with four legs had seven or eight digits, but they disappeared about 350 million years ago⁶.

Usually there's an extra digit on only one hand or one foot³. This is a fairly common condition with an extra digit on the thumb³. It happens in about 1 in 1,000 babies. It's passed down in some families (inherited)³. Often it happens to only one person in a family because of changes in their genes³. Some babies are born with an extra digit both on hands or both feet - and, less often, on both hands and both feet³. Many babies with polydactyly have no other differences in their bodies and no health problems. But this condition can happen along with other hand or foot conditions, such as syndactyly (then it's called polysyndactyly) or with other genetic conditions or syndromes³.

There are three types of polydactyly based on where the digit is^{2,3}:

- The extra digit is outside the thumb or big toe (pre-axial polydactyly)^{2,3,5,6}. When the digit is outside the thumb, it's also called radial polydactyly³. When it's outside the big toe, it's also called tibial polydactyly³.
- The extra digit is outside the little finger or little toe (post-axial polydactyly)^{2,3,5,6}. When the digit is outside the little finger, it's also called ulnar polydactyly³. When it's outside the little toe, it's also called fibular polydactyly³.

The extra digit is between other fingers or toes (central polydactyly)^{2,3}.

According to Novick C et al, in the foot, postaxial polydactyly is the most common form, occurring in 80% of cases, followed by preaxial polydactyly and then central polydactyly². The duplication may range from a well-formed articulated digit to a rudimentary digit². Abnormalities of the associated metatarsal commonly occur in polydactyly².

People with polydactyly usually have to learn to cope with the extra fingers or have them removed⁶. If someone chooses to have excess fingers removed they would usually get them removed early in life, often under age one⁶. People with this condition get their extra digits removed for a variety of reasons⁶. This includes so that they can be accepted by society and for practicality reasons; most common utensils and ordinary objects are designed for hands with five fingers⁵. People who are affected by polydactyly will not be affected by any illnesses due to the disorder⁶.

Most of the time, this condition is discovered at birth when the baby is still in the hospital¹. The health care provider will diagnose the condition based on a family history, medical history, and a physical exam¹.

Medical history questions may include¹:

- Have any other family members been born with extra fingers or toes?
- Is there a known family history of any of the disorders linked to polydactyly?
- Are there any other symptoms or problems?

For some children, polydactyly is only one feature of a more complex genetic condition or syndrome. These children will have other signs and symptoms³.

If your child is born with an extra finger or toe, the doctor will examine your child carefully. During the exam, the doctor will check for other signs to tell whether your child has a more complex condition.

According to Seattle Children's Research Hospital foundation in a paper *Bone, Joint and Muscle Conditions Polydactyly*, "Your child may need an X-ray to see if there are bones in the extra digit and to see how the extra digit connects to the rest of the hand or foot"³. If the doctor thinks your child might have other genetic problems, your child might have tests to check their chromosomes³.

In most cases, doctors remove an extra finger or toe in early childhood³. The goal of treatment is to give your child a hand or foot that works well and looks typical³. There are also practical concerns, such as removing an extra toe so your child's foot fits well into shoes³.

6. Discussion

The reason of presenting the above two cases emanated from the strong family history that the patients presented with; viz a viz a family of four children having suffered the same condition. The mother of the two patients out rightly acknowledged that the condition was familial in nature and that she propagated the gene to her off springs. She immediately revealed the raised lumps on her both little fingers.

Medical history questions may include¹:

- Have any other family members been born with extra fingers or toes?
- Is there a known family history of any of the disorders linked to polydactyly?
- Are there any other symptoms or problems?

The medical history in our patients was obvious because not only did the other siblings in the same family suffered from the same condition but the extended family too. What was evident though was that there was no other history of deformities in the family. The mother was not and did not give any history of diabetic as this condition is sometimes associated with poor glycaemic control of diabetes mellitus in the mothers².

There may not be any other symptoms or disease present¹. It most frequently occurs as an isolated trait with autosomal dominant inheritance and variable penetrance^{2,6}. Polydactyly may be passed down in families¹. Both the children were devoid of any other abnormalities both internally and externally except for the extra-digits. There was an overwhelming family history to suggest that it was an autosomal penetrance because it did not show any bias toward one sex over five generations.

The condition is usually inherited as an autosomal dominant characteristic^{2,6}. This means that the gene is not sex-linked, so females and males are both able to inherit the condition equally. Because the gene is also dominant, a kid with one parent who has the trait will have a fifty percent chance of getting it^{5,6}. In this regard, the family history was unequivocal in relation to inheritance of the deformity. This was supported from the fact that the father of the two patients did not have any family history suggestive of the same deformity in his family lineage.

This most often occurs on the little finger side of the hand¹. All the extra-digits in our patients were either on the little fingers or little toes. There are three types of polydactyly based on where the digit is^{2,3}. These are pre-axial, central and post-axial polydactyly^{2,3,5,6}. Our patients revealed the post-axial type which are sometimes called ulna or fibular polydactyly. The pre-axial affect the thumb or/and the big toe. According to Novick C et al, in the foot, postaxial polydactyly is the most common form, occurring in 80% of cases, followed by preaxial polydactyly and then central polydactyly².

Poorly formed digits are usually removed¹ by simply tying a tight string around the stalk can cause it to fall off in time if there are no bones in the digit¹. In some cases, the extra digits may be well-formed and can even function¹. Larger digits may need surgery to be removed¹. Patient 1 had the extra-digits on the hand removed soon after birth by tying them with a surgical tie. The others that were well formed required surgical removal; which was done in both patients.

The extra digit may range from a small, raised bump to a complete, working finger or toe³. Also, polydactyly can happen at the same time when excess digits are fused together, which is called polysyndactyly⁶. Both the patients had polysyndactyly in their feet bilaterally. A bump was very clear on the hands of the mother of the patients while

the children had fully formed extra-digits and “functional” toes because they were fused with the fifth toes (syndactyly).

According to literature, the frequency is higher in blacks (3.6-13.9 cases per 1000 live births) than in whites (0.3-1.3 cases per 1000 live births)^{1,6}. Our patients were two black children.

The young of the two was affected on all the four limbs while the older sister presented with the deformities on the feet notwithstanding the ones removed soon after birth. The other two older siblings had theirs operated done.

The extra digits on the hands in the older patient were tied off soon after birth, although there were fully formed. The right extra-digit was more of syndactyly than a pure extra digit. The well formed of the little toe was the 6th toe which was in line with the lateral 5th metatarsal. This necessitated the removal of the 5th toe which had the distal, middle and proximal phalanges.

According to Seattle Children’s Research Hospital foundation in a paper *Bone, Joint and Muscle Conditions Polydactyly*, “Your child may need an X-ray to see if there are bones in the extra digit and to see how the extra digit connects to the rest of the hand or foot”³. Radiographs were one of the investigative tools that were applied to assess the skeletal involvement. In the older child (patient 1) the right foot showed, on X-ray, that the fifth toe was not in line with the 5th metatarsal bone. Dependent of this finding it influenced which digit to excise (the fifth instead of the sixth).

In most cases, doctors remove an extra finger or toe in early childhood³. The goal of treatment is to give your child a hand or foot that works well and looks typical³. There are also practical concerns, such as removing an extra toe so your child's foot fits well into shoes³.

If the digit is better formed, a surgeon removes it in the operating room when your child is about 1 year old. This is done as a day surgery. Your child's surgery will be based on their exact condition³. At operation, the children were 1 year 11 months and 4 months old respectively. The plan was to operate on the old child first and the younger child when he was 1 year old. This was because they were both elective and there was no urgency. The mother, however, requested that both children be operated on, on the same day for logistical reasons. They procedures were done on a day-case basis. This was convenient for both parents to be available on the day of the operations.

The extra digits that were on the periphery of the hands and the feet were easier to remove surgically than the above stated 5th toe. Apart from the above reasons for early childhood removal of extra-digits, it is also important to excise the digits before the child enrolls in school. This is because children are damaging to each other and this may affect the child (with a deformity) to develop their self-esteem early enough due to bully from other children. Children with this deformity and their parents may also suffer stigmatization from society. Our patients’ grandparents were opposed and against the removal of the

extra-digits in their grandchildren because they had come to accept the deformity as part of their family. The grandmother said, “Leave them alone, that is part of our family fashion.”

The recovery of the patients was uneventful. The function of the hand on patient two was normal on day ten after surgery. The toes and feet in both patients were equally functional. Patient 2 was able to stand and walk on the feet upon removal of the surgical dressings.

7. Conclusion

The extra-digit as a deformity is not uncommon amongst the Africans. These two case presentations, however, were interesting because of the overwhelming family history toward the deformity.

Diagnosis of the condition is not difficulty but it is important that when a medical practitioner is confronted with such a deformity a detailed history must be obtained from the parent. This is against a backdrop that this condition may occur sporadically.

The history is important as it forms a strong basis for counselling the parents of the child about any anticipated subsequent family planning.

Detailed evaluation as regards investigations must be undertaken to rule out any other associated syndromic conditions. Radiographs remain an important tool before surgery is undertaken.

References

- [1] Kaneshiro NK. Polydactyly – Medline Plus; <https://medlineplus.gov/ency/article/003176.htm>
- [2] Novick C, Thomson DJ. Polydactyly of the Foot: Background, Pathophysiology, Etiology; emedicine.medscape.com/article/1260255-overview
- [3] Polydactyly - Bone, Joint and Muscle Conditions; Seattle Children’s Hospital Research Foundation; <http://www.seattlechildrens.org/medical-conditions/bone-joint-muscle-conditions/polydactyly/>
- [4] Leslie GB. Polydactyly Research Study. <https://www.genome.gov/27529686/polydactyly-research-study/> Last Reviewed: April 2, 2012
- [5] Arnold P. What Causes Polydactyly? <http://www.brighthub.com/science/genetics/articles/47390.aspx> Updated: 8/29/2009
- [6] Julia and Coco. Polydactyly - Genetic Disorder Pages; <https://runkle-science.wikispaces.com/>