

Hepatoprotective Activity of Ethanolic Extract of Peel of Punica Granatum

Bushra Hasan Khan¹, Farida Ahmad², Jameel Ahmad³, Syed Mobashir Yunus⁴

^{1,2,3}Department of Pharmacology, JNMC, AMU, Aligarh

⁴Department of Anatomy, JNMC, AMU, Aligarh

Abstract: **Objectives:** To study the hepatoprotective activity of ethanolic extract of peel of Punica granatum. **Materials and Methods:** Present study was conducted on adult albino Wistar rats of either sex weighing 150-200 grams. Rats were divided into five groups (n=5) and hepatotoxicity was induced by carbon tetrachloride (CCl₄) 1ml/kg dissolved in olive oil (1:1) given intraperitoneally on day 1 and day 4 of the study. Silymarin in the dose of 50mg/kg/day was administered orally as a standard drug. Test groups were given ethanolic extract of peel of Punica granatum (PEE) at doses of 200 and 400mg/kg/day orally along with CCl₄. All animals were sacrificed on the 15th day. Hepatoprotective effect of PEE was assessed by the physical parameters, histopathological examination and biochemical parameters (Aspartate aminotransferase (AST), Alanine aminotransferase (ALT), Alkaline phosphatase (ALP) and Total serum bilirubin). **Results:** The administration of PEE of Punica granatum at doses of 200mg/kg/day and 400mg/kg/day orally, exhibited a highly significant decrease in the rise of mean serum AST, ALT, ALP and total bilirubin as compared to CCl₄ treated group (p<0.001). Hepatoprotective activity of PEE of Punica granatum was seen in the form of restoration of hepatic architecture towards normal. Decrease in the extent of centrilobular necrosis and congestion of sinusoids was also observed in PEE (200mg/kg and 400mg/kg) treated rats when compared to CCl₄ treated group. **Conclusion:** The study showed hepatoprotective activity of ethanolic extract of peel of Punica granatum against carbon tetrachloride induced liver injury in rats.

Keywords: Punica granatum, silymarin, peel ethanolic extract, hepatoprotective, carbon tetrachloride

1. Introduction

Liver is a vital organ for maintaining metabolic homeostasis in the body [1]. It plays a role as a principal organ for detoxification of endogenous as well as exogenous compounds; therefore it is often exposed to a variety of xenobiotics and therapeutic agents [2]. It is an important site for the metabolism of carbohydrates, proteins and lipids. It synthesizes many regulatory enzymes, hormones and stores many nutrients necessary for the daily housekeeping functions of the body [3].

Liver is also prone to many diseases including infectious, metabolic, autoimmune and drug toxicities which are a serious cause of concern. Exposure to toxic chemicals, environmental pollutants and drugs can cause cellular injury through metabolic activation of reactive oxygen species during metabolism by the liver resulting in liver damage [4]. Drug induced liver injury occurs in 5% of all hospital admissions and 50% of all acute liver failure cases [5]. Drug induced liver injury may manifest as acute hepatitis, cholestasis and cirrhosis [6]. The progression of liver injury to cirrhosis may occur over weeks to years. India is known to possess a huge burden of viral hepatitis which affects about 400 million people globally and is responsible for 1.4 million deaths annually [7]. The Integrated Disease Surveillance Program of India's National Center for Disease Control reported 290,000 cases of acute viral hepatitis in India in 2013 [8]. Liver cirrhosis is a substantial cause of morbidity and mortality [9].

Treatment options for common liver diseases, including drug induced hepatitis are very few. These therapies become progressively less effective if chronic liver disease evolves into cirrhosis. Available pharmacotherapy offers a limited scope for providing effective cure for liver diseases and

there is a need to get new drugs capable of treating toxic liver injury [10]. Liver protective drugs have been reported to contain a variety of chemical constituents like phenols, coumarins, lignins, essential oils, flavonoids, organic acids, lipids, alkaloids and xanthenes [11]. Many herbal drugs have been subjected to scientific study for hepatoprotective activity [12-16].

CCl₄ induced liver toxicity is one of the widely used and consistent model for inducing liver injury in rats because liver damage produced by CCl₄ is histopathologically similar to acute hepatitis. Liver damage is often assessed with the help of liver function tests and histopathological examination.

Punica granatum (Pomegranate) is a medium-sized deciduous tree found throughout India, commonly known as Anar. Its stem bark, flowers, fruits, peels, leaves and stems are employed in many disease states in indigenous systems of medicine. It is commonly used in folklore medicine as carminative and antihelminthic [17]. In Ayurveda, it is employed in the treatment of diarrhea, dysentery and worm infestations. Studies have reported that bark, roots, fruits and leaves of *Punica granatum* have medicinal benefit [18-20]. Therefore, *Punica granatum* was selected in this study for evaluation of its hepatoprotective effect in albino Wistar rats.

2. Materials and Methods

Plant material and preparation of extracts

Punica granatum was obtained from an orchard at Aligarh. The specimen was identified and authenticated by Mr. M. Badruzzaman Siddiqui (Associate Professor), Department of Botany, Aligarh Muslim University, Aligarh and the voucher specimen (Vide Voucher number: 42931) was

submitted. Peels of fruits were gathered up, thoroughly washed, chopped, shade dried and powdered in an electric grinder. The powder thus obtained was extracted with absolute ethanol.

Animals

Adult albino Wistar rats of either sex weighing 150-200 grams were obtained from the Central Animal House, Jawaharlal Nehru Medical College, Aligarh Muslim University, Aligarh, Uttar Pradesh, India. Animals were housed in proper cages and standard laboratory conditions were maintained (temperature 27±3°C, 12 hour light/dark cycle) with relative humidity of 40-70% throughout the experimental period. All the animals were fed with commercial standard pellet diet and water ad libitum. They were acclimatized to the laboratory conditions for one week prior to the experiments.

Chemicals

Carbon tetrachloride (CCl₄) was from Thomas Baker Pvt. Ltd. Mumbai and Silymarin suspension was obtained from Micro Labs Ltd. Formalin, Ethanol, Xylene, Haematoxylin, Paraffin wax, Hydrochloric acid and all the other chemicals used in this study were of analytical grades.

Approval for the study protocol

The study protocol was approved by the Institutional Animal Ethics Committee of JNMC, AMU, Aligarh on 04.03.2015. All animal experiments were carried out as per the rules and regulations of CPCSEA under the 'Guidelines for Care and Use of Animals in Scientific Research'.

Experimental design

Rats were randomly divided into five groups containing five animals each (Table 1). Group I received distilled water and served as normal control; Group II was administered with CCl₄ (Negative Control); Group III, served as Positive Control (Silymarin and CCl₄); Group IV and Group V were given PEE 200mg/kg/day and PEE 400mg/kg/day of *Punica granatum* along with CCl₄ respectively.

Table 1: Treatment schedule

S.No.	Groups (n=5)	Treatment given	Dosage
1.	Normal Control	Distilled water	1ml/100g/day p.o.×14days
2.	Negative control	CCl ₄ in olive oil (1:1)	1ml/kg i.p. on day 1 and day 4
3.	Positive control	CCl ₄ Silymarin	1ml/kg i.p. on day 1 and day 4 50mg/kg/day p.o. ×14 days
4.	PEE (200)	CCl ₄ PEE	1ml/kg i.p. on day 1 and day 4 200mg/kg/day p.o. ×14 days
5.	PEE (400)	CCl ₄ PEE	1ml/kg i.p. on day 1 and day 4 400mg/kg/day p.o. ×14 days

PEE= Peel ethanolic extract; CCl₄=Carbon tetrachloride; p.o.= per orum; i.p.= intraperitoneal

Collection of samples

Rats were anesthetized by method of Wellington et al., 2013 [21]. Blood withdrawal was performed according to the procedure described by Morton et al., 1993 [22]. Blood was withdrawn from the left ventricle with the help of 5 ml syringe, and with as little pressure as possible to avoid haemolysis. Blood was centrifuged at 5000 rpm for 10

minutes and plasma was extracted. After opening the abdomen, liver was visualized in the right upper quadrant and dissected out. Liver was kept in 10% formalin for histopathological examination.

Assessment of hepatoprotective activity

Determination of serum biochemical parameters

Blood samples were collected on 15th day of study and serum was analysed for biochemical parameters [Aspartate aminotransferase (AST), Alanine aminotransferase (ALT), Alkaline phosphatase (ALP) and Total serum bilirubin].

Histopathological examination

Dissected liver was grossly examined, preserved in 10% Formalin and processed in the Post Graduate Histology laboratory, Department of Anatomy, JNMC, AMU, Aligarh.

Statistical analysis

The results were presented as Mean ± Standard Error of Mean (SEM). The different groups were compared by One way analysis of variance (ANOVA) followed by Tukey HSD test to analyze statistical significance. P-value of less than 0.05 was considered to be significant.

3. Results & Discussion

The ethanolic extract of peel (PEE) of *Punica granatum* was prepared by soxhlet extraction using absolute ethanol and the yield obtained was 44.23%. The weight of rats, weight of liver and volume of liver in all groups were recorded on day 1 and day 15 of the study.

There was a significant increase in weight of the liver as well as volume of liver in the negative control group when compared with normal control group (p<0.001). Silymarin treated rats showed a decrease in weight of liver as well as volume of liver in comparison to CCl₄ group (p<0.05) (Table 2). Ethanolic extract of peel of *Punica granatum* (PEE), 200mg/kg/day showed a decrease in weight of the liver and volume of liver as compared to the negative control group, however the decrease was not statistically significant (p= 0.772; p= 0.783). PEE in dose of 400mg/kg/day also exhibited a decrease in weight and volume of liver but the decrease was not statistically significant (p= 0.104; p= 0.247). There was no observable change in the weight of rats during the study duration.

Table 2: Effect of ethanolic extract of peel of *Punica granatum* (PEE) on weight and volume of liver of rats

S. No.	Groups (n = 5)	Weight of liver (g)	Volume of liver (ml)
1	Normal control	3.86 ± 0.16	3.86 ± 0.16
2	Negative control	5.40 ± 0.30***	5.30 ± 0.30***
3	Positive control	4.31 ± 0.08*	4.30 ± 0.05*
4	PEE (200)	4.90 ± 0.24	4.82 ± 0.23
5	PEE (400)	4.54 ± 0.25	4.58 ± 0.23

All the values are expressed as Mean±SEM. Negative control group was compared with Normal control group and all other groups were compared with Negative control group, *p< 0.05, **p<0.01 and ***p<0.001 were considered significant.

Normal control group, given only distilled water served as baseline for biochemical parameters. A highly significant

rise in serum AST, ALT, ALP and total serum bilirubin was observed in negative control group in comparison to normal control group ($p < 0.001$).

Table 3: Effect of ethanolic extract of peel of *Punica granatum* (PEE) on biochemical parameters

Groups (n = 5)	AST (IU/L)	ALT (IU/L)	ALP (KAU/dl)	Total Bilirubin (mg/dl)
Normal control	35.20 ± 4.45	32.00 ± 6.78	51.00 ± 4.04	0.27 ± 0.01
Negative control	120.00 ± 7.54***	133.60 ± 8.23***	89.40 ± 5.91***	0.42 ± 0.04***
Positive control	46.80 ± 4.75***	53.80 ± 3.53***	55.40 ± 3.12***	0.28 ± 0.01***
PEE (200)	49.00 ± 3.33***	53.60 ± 2.09***	60.60 ± 3.16***	0.28 ± 0.01***
PEE (400)	46.20 ± 3.02***	50.40 ± 2.29***	55.40 ± 3.17***	0.27 ± 0.01***

All values are expressed as Mean±SEM. Negative control group was compared with Normal control group and all other groups were compared with Negative control group, * $p < 0.05$, ** $p < 0.01$ and *** $p < 0.001$ were considered significant.

Positive control group exhibited highly significant decrease in AST, ALT, ALP and total serum bilirubin when compared with negative control group ($p < 0.001$). PEE at the doses of 200 and 400mg/kg/day showed highly significant reduction in AST, ALT, ALP and total serum bilirubin when compared to CCl_4 treated group ($p < 0.001$) (Table 3).

Table 4: Percentage of hepatoprotection of ethanolic extract of peel of *Punica granatum* (PEE)

S.No.	Groups (n = 5)	Percentage of Hepatoprotection (%)			
		AST	ALT	ALP	Total Bilirubin
1	Positive control	86.32	79.80	88.54	93.33
2	PEE (200)	83.73	78.74	75.00	93.33
3	PEE (400)	87.03	81.89	88.54	100.00

Percentage of hepatoprotection offered by PEE against CCl_4 induced liver injury was calculated [23,24]. PEE of *Punica granatum* in doses of 200 and 400mg/kg/day provided hepatoprotection against CCl_4 induced liver injury (Table 4).

Osman et al (2011) showed hepatoprotective activity of ethanolic extract of peel of *Punica granatum* by administering orally to rats in the doses of 50mg/kg/day for a period of six weeks [25]. Similar hepatoprotective effect of PEE of *Punica granatum* in doses of 200mg/kg/day and 400mg/kg/day was also observed in the present study of fourteen days duration.

Histological study of liver of normal control group showed normal hepatic architecture having cords of hepatocytes with central vein and sinusoids (S) (Figure 1) whereas the liver section of CCl_4 treated animals showed centrilobular necrosis, kupffer cells (K), damaged hepatocytes (H), with sinusoidal edema and loss of hepatic architecture (Figure 2). The section of liver tissue treated with silymarin along with CCl_4 showed normal hepatocytes with few inflammatory cells and edema (E) of sinusoids, however maintaining normal hepatic architecture (Figure 3). Similar histopathological findings in liver of silymarin with CCl_4 treated rats have also been reported previously [26-28].

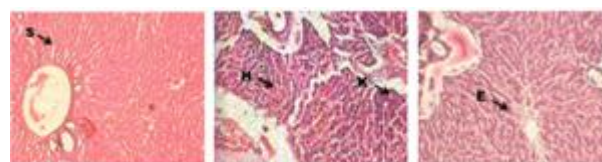

Figure 1 Figure 2 Figure 3

The animals treated with different doses of the ethanolic extract of peel (PEE) of *Punica granatum* showed decrease in sinusoidal edema, reduced number of kupffer cells, few swollen hepatocytes and less components of portal triad showing dilatation.

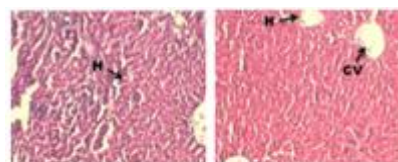


Figure 4 Figure 5

PEE 200mg/kg/day showed a moderate number of recovered hepatocytes (H) with less edema and necrosis as compared to negative control (Figure 4). Liver of animals treated with PEE 400mg/kg/day showed normal central vein (CV) and hepatic cords with few kupffer cells (K) and disrupted hepatocytes, which is comparable to the liver of rats treated with the standard drug silymarin (Figure 5). These findings are suggestive of hepatoprotective activity of ethanolic extract of peel of *Punica granatum* in doses of 200 and 400mg/kg/day which is more marked with 400mg/kg/day.

Ellagitannins including punicalin, punicalagin, pedunculagin, granatin, casuarinin, gallagylidilactone and numerous piperidine alkaloids were isolated from peels of *Punica granatum* [29-31]. Peels of *Punica granatum* have been reported to contain polyphenols including gallic acid, catechin, quercetin, rutin, flavonols, flavones, flavonones and anthocyanidins [32-34]. As antioxidants, polyphenols may provide protection against oxidative damage and therefore decrease the risk of development of diseases associated with oxidative stress [35-40]. Ethanolic extract of peel of *Punica granatum* in the doses of 200mg/kg/day and 400mg/kg/day exhibited hepatoprotective activity suggesting that peel of *Punica granatum* contains phytochemicals which are probably involved in hepatoprotection. Presence of these antioxidants in the peel of *Punica granatum* may be responsible for protection against CCl_4 induced liver injury in rats.

4. Conclusion

This study showed hepatoprotective activity of ethanolic extract of peel of *Punica granatum* against carbon tetrachloride induced hepatic injury in rats.

References

- [1] **Ramadori G**, Moriconi F, Malik I, Dudas J. Physiology and pathophysiology of liver inflammation, damage and repair. *Journal of Physiology and Pharmacology*. 2008;59(1):107-117.
- [2] **Shim JY**, Kim MH, Kim HD, Ahn JY, Yun YS, Song JY. Protective action of the immunomodulator ginsan against carbon tetrachloride-induced liver injury via control of oxidative stress and the inflammatory response. *Toxicology and Applied Pharmacology*. 2010 Feb 1;242(3):318-325.
- [3] **Yadav NP**, Pal A, Shanker K, Bawankule DU, Gupta AK, Darokar MP, et al. Synergistic effect of silymarin and standardized extract of *Phyllanthus amarus* against CCl₄-induced hepatotoxicity in *Rattus norvegicus*. *Phytomedicine*. 2008;15:1053-1061.
- [4] **Khan BH**, Ahmad F, Ahmad J, Yunus SM. Evaluation of hepatoprotective effect of ethanolic extract of root of *punica granatum* in rats. *Asian Journal of Pharmaceutical and Clinical Research*. 2017 July;10(7).
- [5] **Anandakumar P**, Vanitha MK. Drug induced hepatotoxicity- a review. *Advanced Journal of Pharmacie and Life Science Research*. 2014;2(4):39-45.
- [6] **Kosanam S**, Boyina R. Drug induced liver injury: A review. *International Journal of Pharmacological Research*. 2015 Mar 4;5(2):24-30.
- [7] **WHO**. Hepatitis [Internet]. 2016 [Cited November 2016]. <http://www.who.int/hepatitis/en/>
- [8] **Kumar T**, Shrivastava A, Kumar A, Laserson KF, Narain JP, Venkatesh S, et al. Viral Hepatitis Surveillance- India, 2011-2013. *Morbidity Mortality Weekly Report*. 2015 Jul 24;64(28):758-62.
- [9] **Mokdad AA**, Lopez AD, Shahrzaz S, Lozano R, Mokdad AH, Stanaway J, et al. Liver cirrhosis mortality in 187 countries between 1980 and 2010: a systematic analysis. *BMC medicine*. 2014 Sep 18;12(1):1.
- [10] **Chaudhary GD**, Kamboj P, Singh I, Kalia AN. Herbs as life savers: A review. *Indian Journal of Natural Products and Resources*. 2010;1(4):397-408.
- [11] **de Pascual-Teresa S**, Santos-Buelga C, Rivas-Gonzalo JC. Quantitative analysis of flavan-3-ols in Spanish foodstuffs and beverages. *Journal of Agricultural and Food Chemistry*. 2000 Nov 20;48(11):5331-5337.
- [12] **Alam S**, Khan NA, Nasiruddin M. Evaluation of Curative potential of Qurs-e-Rewand (a Unani Formulation) against CCl₄ induced hepatotoxicity in Rats. *International Journal of Basic Medicine and Clinical Research*. 2015;2(5):107-115.
- [13] **Zameer M**, Rauf A and Qasmi IA. Standardization and safety evaluation of a polyherbal formulation "Kabideen (syrup)". *International Journal of Advanced Research*. 2015;3(9):1105-1114.
- [14] **Kshirsagar AD**, Mohite R, Aggrawal AS, Suralkar UR. Hepatoprotective medicinal plants of Ayurveda—a review. *Asian Journal of Pharmaceutical and Clinical Research*. 2011;4(3):1-8.
- [15] **Huseini HF**, Alavian SM, Heshmat R, Heydari MR, Abolmaali K. The efficacy of Liv-52 on liver cirrhotic patients: a randomized, double-blind, placebo-controlled first approach. *Phytomedicine*. 2005;12(9):619-624.
- [16] **Siddiqui MMH**, Sultana A, Siddiqui MY. Effect of Kabdeen in Warm-e-Kabid Vairoosi (Viral hepatitis). *Indian Journal of Traditional Knowledge*. 2005;4(4):416-420.
- [17] **Bhanoji Rao ME**, Dama GY. Evaluation of hepatoprotective activity of *Punica granatum* leaves on carbon tetrachloride induced hepatotoxicity in rats. *International Journal of Universal Pharmacy and Life Sciences*. 2011;1(2):23-36.
- [18] **Khare CP**. *Encyclopedia of Indian medicinal plants. Rational, Western therapy, Ayurvedic and other Traditional usage, Botany*. New York:Springer-Verlag Berlin Heidelberg;2004. p.390-392.
- [19] **Ayurvedic Pharmacopoeia of India, Part I**. Government of India, Ministry of Health and Family Welfare, Department of Indian Systems of Medicine & Homoeopathy, New Delhi, 2003.
- [20] **Kumar V**, Abbas AK, Aster JC. *Robbins Basic Pathology*. 9th ed. Philadelphia:Elsevier Saunders;2013.
- [21] **Wellington D**, Mikaelian I, Singer L. Comparison of Ketamine–Xylazine and Ketamine–Dexmedetomidine anesthesia and intraperitoneal tolerance in rats. *Journal of the American Association for Laboratory Animal Science*. 2013 Jul 1;52(4):481-487.
- [22] **Morton DB**, Abbot D, Barclay R, Close BS, Ewbank R, Gask D, et al. Removal of blood from laboratory mammals and birds. *Laboratory Animals*. 1993 Jan 1;27(1):1-22.
- [23] **Syed SN**, Rizvi W, Kumar A, Khan AA, Moin S, Ahsan A. A study to evaluate antioxidant and hepatoprotective activity of aqueous extract of roots of *Valeriana wallichii* in CCl₄ induced hepatotoxicity in rats. *International Journal of Basic and Clinical Pharmacology*. 2014;3(2):354-358.
- [24] **Dasgupta BE**, Kalita JC, Chowdhury A, Kotoky JI. Hepatoprotective activity of *Nelsonia canescens* (Lam.) Spreng on acute hepatotoxicity induced by paracetamol. *International Journal of Pharmacy and Pharmaceutical Sciences*. 2012;4(1):107-112.
- [25] **Osman M**, Ahmed M, Mahfouz S, Elaby S. Biochemical studies on the hepatoprotective effects of pomegranate and guava ethanol extracts. *New York Science Journal*. 2011;4(3):27-41.
- [26] **Freitag AF**, Cardia GF, da Rocha BA, Aguiar RP, Silva-Comar FM, Spironello RA, et al. Hepatoprotective effect of silymarin (*Silybum marianum*) on hepatotoxicity induced by acetaminophen in spontaneously hypertensive rats. *Evidence Based Complementary and Alternative Medicine*. 2015 Mar 2;2015:538317.
- [27] **Salam OMEA**, Sleem AA, Omara EA, Hassan NS. Effect of Ribavirin alone or combined with silymarin on carbon tetrachloride induced hepatic damage in rats. *Drug Target Insights*. 2007;2:19–27.
- [28] **Mansour HH**, Hafez HF, Fahmy NM. Silymarin modulates cisplatin induced oxidative stress and hepatotoxicity in rats. *Journal of Biochemistry and Molecular Biology*. 2006 Nov 30;39(6):656-661.

- [29] **Rosenblat M**, Volkova N, Coleman R, Aviram M. Pomegranate byproduct administration to apolipoprotein e-deficient mice attenuates atherosclerosis development as a result of decreased macrophage oxidative stress and reduced cellular uptake of oxidized low density lipoprotein. *Journal of Agricultural and Food Chemistry*. 2006 Mar 8;54(5):1928-1935.
- [30] **Neuhof H**, Witte L, Gorunovic M, Czygan FC. Alkaloids in the bark of *Punica granatum* L. (pomegranate) from Yugoslavia. *Pharmazie*. 1993;48:389-391.
- [31] **Tanaka T**, Nonaka G, Nishioka I. Tannins and related compounds. XL: Revision of the structures of punicalin and punicalagin and isolation and characterization of 2-O-galloylpunicalin from the bark of *Punica granatum* L. *Chemical and Pharmaceutical Bulletin*. 1986;34(2):650-655.
- [32] **Zahin M**, Aqil F, Ahmad I. Broad spectrum antimutagenic activity of antioxidant active fraction of *Punica granatum* L. peel extracts. *Mutation Research/Genetic Toxicology and Environmental Mutagenesis*. 2010 Dec 21;703(2):99-107.
- [33] **Nawwar MA**, Hussein SA, Merfort I. NMR spectral analysis of polyphenols from *Punica granatum*. *Phytochemistry*. 1994;36:793-798.
- [34] **Noda Y**, Kaneyuki T, Mori A, Packer L. Antioxidant activities of pomegranate fruit extract and its anthocyanidins: delphinidin, cyanidin, and pelargonidin. *Journal of Agricultural and Food Chemistry*. 2002 Jan 2;50(1):166-171.
- [35] **Uzma N**, Kumar BS, Anees S. Red wine ameliorates CCl₄ induced acute liver injury in rats. *Australian Journal of Biomedical Science*. 2011;1(1):1-7.
- [36] **Pandey KB**, Rizvi SI. Plant polyphenols as dietary antioxidants in human health and disease. *Oxidative Medicine and Cellular Longevity*. 2009;2(5):270-278.
- [37] **Scalbert A**, Manach C, Morand C, Remesy C. Dietary polyphenols and the prevention of diseases. *Critical Reviews in Food Science and Nutrition*. 2005;45:287-306.
- [38] **Amakura Y**, Okada M, Tsuji S, Tonogai Y. Determination of phenolic acids in fruit juices by isocratic column liquid chromatography. *Journal of chromatography A*. 2000 Sep 1;891(1):183-188.
- [39] **Singh AK**, Mani H, Seth P, Gaddipati JP, Kumari R, Banuadha KK, et al. Picroliv preconditioning protects the rat liver against ischemia-reperfusion injury. *European Journal of Pharmacology*. 2000 May 3;395(3):229-239.
- [40] **Khan NA**, Nasiruddin M, Khan IA, Perveen A and Khan AA. An Experimental Study to Evaluate Hepatoprotective Activity of Herbal Formulation in Rats. *British Journal of Pharmaceutical Research*. 2015;8(2):1-7.

Dr. Jameel Ahmad, Assistant Professor (Department of Pharmacology, JNMC, AMU, Aligarh)

Dr. Syed mobashir Yunus, Professor (Department of Anatomy, JNMC, AMU, Aligarh)

Author Profile

Dr. Bushra Hasan Khan (Department of Pharmacology, JNMC, AMU, Aligarh)

Dr. Farida Ahmad, Professor (Department of Pharmacology, JNMC, AMU, Aligarh)