

Percutaneous Balloon Valvuloplasty with Inoue Balloon Catheter Technique for Pulmonary Valve Stenosis in Adolescents and Adults

Dr Bhavesh Talaviya¹, Dr P. P. Deshmukh², Dr Mukund Deshpande³, Dr Sunil Washimkar⁴,
Dr Mahendra Maske⁵

^{1, 2, 3, 4, 5}Department of Cardiology, Super Speciality Hospital & Medical College, Nagpur, Maharashtra, India

Abstract: **Background:** Percutaneous balloon pulmonary valvuloplasty is the procedure of choice for uncomplicated severe or symptomatic pulmonary stenosis. The present study describes our experience in balloon pulmonary valvuloplasty using the Inoue balloon catheter in adolescent and adult patients. **Aims:** To assess the immediate and mid-term outcomes of percutaneous balloon valvuloplasty with Inoue balloon catheter in patients with age group between 18 to 25 years. **Methods and results:** Between August 2015 and May 2017, we performed percutaneous balloon pulmonary valvuloplasty with Inoue balloon catheter in 14 patients (50% females) aged 18 to 25 years. Following the procedure, the mean right ventricular systolic pressure and the pulmonary valvular peak-to-peak systolic gradient decreased from (200 to 60 mmHg, $p = 0.001$) and (180 to 38 mmHg, $p = 0.001$), respectively. 8 patients which were available for follow-up for 1 year had a mean residual peak gradient of 10 mmHg on Doppler and mean infundibular gradient was 10 mmHg. There was no further increase in grade of pulmonary regurgitation or restenosis on mid-term follow-up. **Conclusion:** Percutaneous Inoue balloon technique is an attractive alternative with excellent mid-term results for adolescents and adults with isolated pulmonary valvular stenosis.

1. Introduction

Pulmonary valve stenosis (PS) is a relatively common disease, and may also be diagnosed in adults, with an incidence of 0.12 per 1000 adults.(1). The presentation may be mild (mostly asymptomatic), moderate (dyspnoea on exertion and fatigue), or severe (right ventricular failure and cyanosis). Since the first trans catheter balloon pulmonary valvuloplasty (BPV) by Kan et al(2), it has become the procedure of choice for children and adults with uncomplicated severe or symptomatic PS. Most of centres use various fixed size balloon catheters using a single or a double balloon technique for BPV. But there are disadvantages of using double or triple balloons such as prolonged procedural time, stretch-induced injury to vessels, balloon slippage and more frequently injuring the pulmonary valve.(3). The Inoue balloon is a unique balloon designed specifically for dilation of the mitral valve.(4). It is manufactured with two layers of latex and a fine layer of nylon mesh sandwiched between them. Inoue balloons are available in multiple sizes from 20 to 30mm varying in 2mm increments. The Inoue balloons have burst pressures from 4 atm for the 20mm diameter decreasing to 2 atm for the 30mm diameter balloon. Each catheter can be safely inflated to a maximal diameter of 1–2mm above the nominal size because of the built-in safety margin. The use of the Inoue balloon was first reported by Lau et al.(5) has advantages over the single-balloon technique. Unlike the cylindrical balloon catheter, with its stiff tip and long balloon, the Inoue balloon catheter is flexible and short, thus minimising the extent of injury to the RV outflow tract and the MPA.(5). Double balloon technique is more complex due to one balloon snagging on the other when both are positioned side by side across the annulus. Moreover, Inoue balloon due to its short and self-positioning characters, it minimises possible injury to the right ventricular (RV) infundibulum or the main pulmonary artery (PA).(6). The adjustable inflation of the Inoue balloon makes stepwise dilation possible, reducing the risk of over-dilation of the pulmonary valve. This is not possible with the

cylindrical balloon catheter as it wrinkles after inflation and loses its low profile shape. A further advantage of the Inoue balloon arises from its short inflation–deflation cycle of approximately five seconds. This takes care of haemodynamic compromise resulting from the complete obstruction of right ventricular outflow during inflation of the balloon. All these advantages of the Inoue balloon catheter make procedures simpler, safer, and faster.(5),(7).

There is scant Indian data on Inoue balloon catheter technique for PS. The present report describes our experience in BPV using the Inoue balloon catheter and its immediate and mid-term results in adolescent and adult patients.

2. Methods

2.1. Study patients

From August 2015 to May 2017, 14 consecutive adolescent or adult patients underwent BPV with an Inoue balloon catheter. Patient selection was based on symptoms and/or signs and investigations supporting significant isolated valvular PS. All patients had an electrocardiogram (ECG), chest radiograph, and transthoracic echocardiography (TTE) studies done prior to the procedure. Balloon valvotomy was planned in asymptomatic patients with echocardiographic evidence of doming of the pulmonary valve and maximum instantaneous gradient across the pulmonary valve greater than 60mmHg or mean gradient greater than 40 mmHg, and in symptomatic patients with instantaneous gradient greater than 50mmHg and mean gradient greater than 30 mmHg. Patients with grade III or more Pulmonary regurgitation were excluded from this study.

The degree of severity of the pulmonary valve stenosis as well as the pulmonary subvalvular obstruction was assessed and quantified with continuous wave Doppler. The presence and intensity of pulmonary regurgitation were assessed

through colour flow mapping. There were total 14 patients, 7 men and 7 female. There were no ASD as well as no VSD or PDA in any patients. There were no cases of any complex congenital heart disease associated.

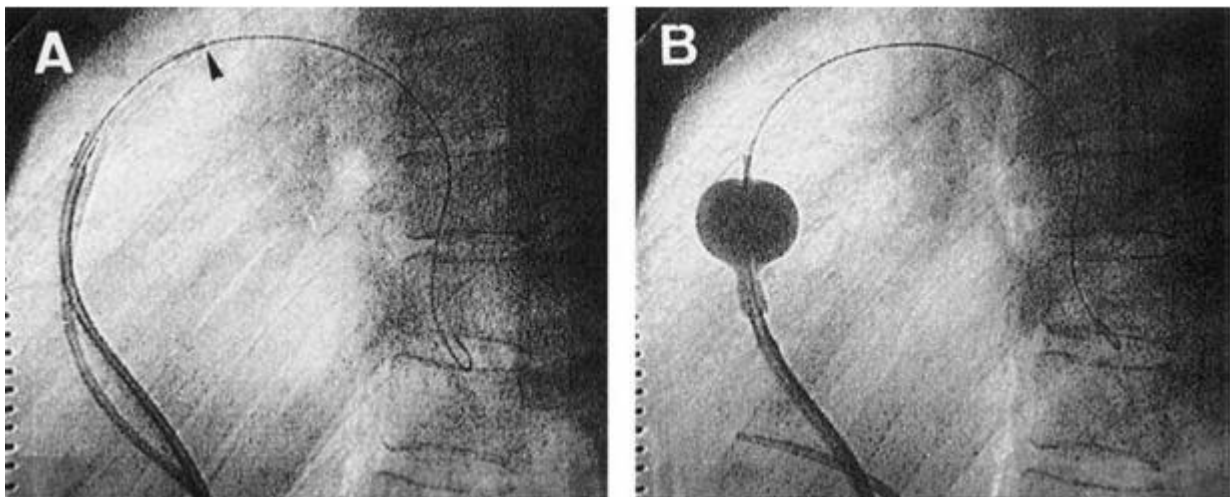
2.2. Procedure

All patients were taken for BPV with prior informed consent. After 6F right femoral vein sheath insertion, intravenous heparin was given at a total dose of 100U/kg. A 5F right femoral arterial access was taken for pressure monitoring. A diagnostic right heart catheterisation to include RV and PA pressure was performed. Right ventriculography in the left lateral view was done using an NIH catheter of appropriate size. From this cineangiogram assessment of the pulmonary annulus was done and the presence of systolic doming was confirmed. The pulmonary annulus diameter was measured during systole. Over a 0.032 "double length angled tip guide wire a 5F Judkins Right (JR) catheter was delivered into the right heart and placed distal to the stenotic pulmonary valve. The JR catheter was exchanged over the wire with an 8F Mullins dilator. A 270 cm, 0.025mm floppy-tipped stainless steel guide wire was anchored distally in the dilated PA over the Mullins dilator, then dilator was removed. Then 14F dilator was used to dilate the venous groin access for easy passage of the balloon catheter. A 12F air free Inoue balloon catheter was prepared, stretched and slenderised by insertion of 18G silver metal tube. The catheter was inserted over the guide wire into the right femoral vein and advanced into the right atrium and then into the RV. On reaching the level of RVOT, de-slenderised. The catheter balloon was then manoeuvred across the stenotic valve with slight clockwise torque to facilitate easy crossing. It was placed in the main

pulmonary artery with the guide-wire firmly held in place. The distal half of the balloon was inflated with diluted contrast agent with normal saline (dilution, 1:4). Initial inflation was performed with a balloon size 1–2mm less than its maximal capacity. Then catheter was pulled back until the middle portion of the balloon was positioned just across the pulmonic valve. The balloon was fully inflated within 4–5 s and then quickly deflated. Repeat inflations with increased balloon diameters (0.5 ml increments) were performed until the waist was abolished. The deflated balloon was then removed. Then over guidewire, a Multi-Track Angio (Bonhoeffer) catheter advanced into the distal pulmonary artery for pull-back pressure measurement. After successful dilatation, angiography revealed an increase in the systolic excursion with relief in doming of the leaflets, and an increase in the width of the jet across the valve. Following BPV, all catheters were removed and hemostasis was achieved. After the procedure, all patients were transferred to their recovery facility and given aspirin 3 mg/kg per day for six months. Transthoracic echocardiography (TTE) and electrocardiography were performed prior to discharge and patients were routinely assessed at one month after the procedure and yearly thereafter.

2.4. Statistical Analysis

All data is presented as mean standard deviation for continuous variables and as proportions for categorical variables. SPSS version 20.0 (SPSS, Inc.) was used to perform statistical analysis. Continuous variables were analysed using student t test. All p values were two sided and $p < 0.05$ was considered significant.



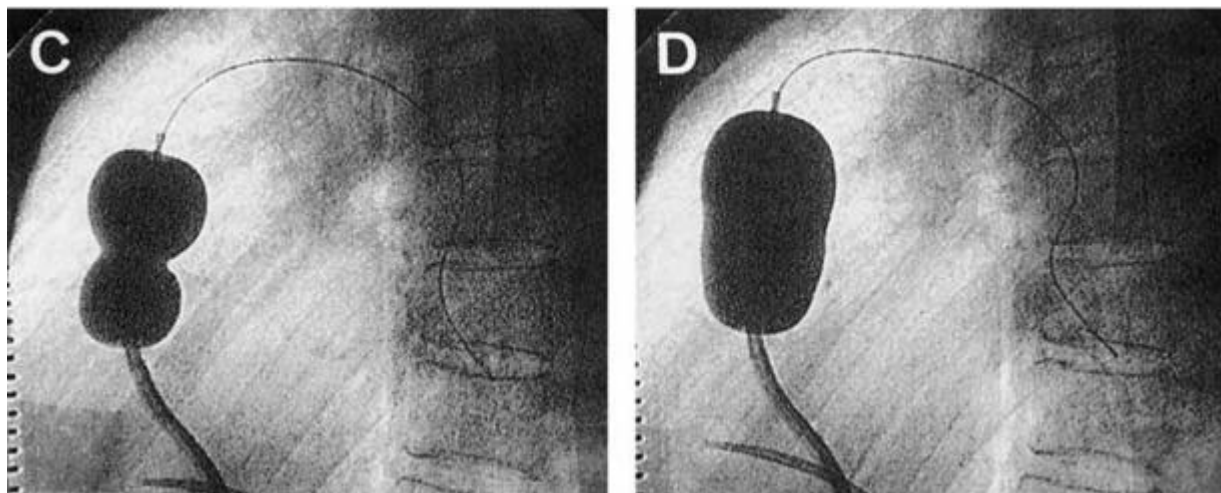


Figure 1: Sequence of pulmonary valvuloplasty using an Inoue balloon catheter in the lateral view. A: The catheter balloon (arrowhead) is placed in the main pulmonary artery over a guide wire positioned in the distal left pulmonary artery. B: After the more compliant distal balloon is inflated, the catheter is pulled back to anchor the balloon at the pulmonary valve. C: As the proximal balloon is inflated, a waist is created by the stenosed valve. D: At full inflation, the waist disappears as the valve is dilated. A Berman catheter is also seen in all frames

3. Results

3.1 Patient characteristics

14 patients aged 18–25 years underwent BPV, including 7 male and 7 female patients. The baseline characteristics of patients are summarised in table given below. In our study, most patients were symptomatic with complaints of effort intolerance or shortness of breath (78.13%). Two patients had syncopal episodes while three had symptoms of right heart failure with pedal oedema. Two patients presented with re-stenosis after prior BPV.

3.2 Haemodynamic results

The Inoue balloon catheter could be advanced with ease across the RVOT and dilatation at the orifice was achieved in all patients. All patients had typically a “dome-shaped” pulmonary valve, post-stenotic dilatation of the main pulmonary artery and marked trabeculation of RV on right ventricular angiography. The mean annular size and final balloon-to-annulus ratio was 30 mm and 0.87 respectively. The RV systolic pressure decreased by 50% from 102 ± 41 to 52 ± 19 mmHg immediately post BPV ($p = 0.001$). The pulmonary valvular peak to peak gradient was reduced by 91% from 81 ± 40 to 7 ± 7 mmHg ($p = 0.0002$) with 11 patients experiencing almost total abolition of valvular gradient of less than 10 mmHg. Immediately after BPV the infundibular peak to peak systolic gradient developed in 13 patients and increased in remaining patients from 20 to 64 mmHg, the gradient ranged from 8 to 70 mmHg (mean 29). Right atrial and pulmonary arterial pressure remains unchanged. There was, however, a trend towards a lower right ventricular diastolic pressure after BPV from 9 ± 6 to 8 ± 5 mmHg ($p = 0.09$). Of the 9 patients who received BPV at least 12

months earlier, 8 underwent repeat hemodynamic study at 6 and 12 months. After treatment all had sustained hemodynamic improvement with no e/o valvular restenosis (Table 1). The mean right ventricular systolic pressure and the mean infundibular peak to peak systolic gradient were reduced compared to immediate post BPV results (54 to 40 mmHg, $p = 0.03$, and 28 to 10 mmHg, $p = 0.03$ respectively).

Echocardiographic and electrocardiographic results:

Colour Doppler echocardiography after BPV revealed no significant pulmonary regurgitation. In 8 patients unchanged mild regurgitation in two patients and new mild regurgitation in one patient. Electrocardiographic evidence of right ventricular hypertrophy in 8 of 9 patients who had been followed up for more than 6 months, so complete regression in 4 (patients no 1, 2, 6, 9) and partial regression in other 4 (patients no 3, 4, 5, 7). Majority of regression occur in first three months.

3.3 Complications

Apart from infrequent ventricular premature beats, none of the patient experienced significant arrhythmic events. There was no episode of dizziness or syncope, stroke and hypotension during inflation. Trauma to the RV outflow tract or other cardiac structures did not occur in any patient. Post procedure, one patient developed deep venous thrombosis (DVT) extending to the common iliac vein. She was administered anticoagulation therapy and responded well with no evidence of DVT on last follow-up. All other patients were discharged the following day.

Table 1: Hemodynamic Data and Balloon-Related Data

Patient	Age		RVSP (mm Hg)			PVG (mm Hg)			IG (mm Hg)			F/U	BL	AN	BL/AN
	(years)	sex	B	A	F/U	B	A	F/U	B	A	F/U	(months)	(mm)	(mm)	Ratio
1	25	M	65	35	36	38	10		0	10	0	30	28	30	0.93
2	19	F	62	44	48	48	12	14	0	10	22	28	24	26	0.92
3	18	M	110	54	22	88	20	10	0	12	0	12	25	28	0.89
4	24	M	200	52	36	182	2	2	0	36	16	12	26	32	0.81
5	20	F	134	50	34	115	0	3	0	40	12	14	24	28	0.89
6	21	M	110	38	38	88	14	4	0	10	0	14	26	34	0.80
7	21	M	138	70	48	115	10	12	0	44	0	14	26	30	0.86
8	19	F	65	42	66	46	8	23	0	10	30	12	28	30	0.93
9	17	F	90	90		52	10	12	20	64			24	28	0.85
10	25	M	64	38		50	0		0	30			26	28	0.92
11	25	F	62	40		50	0		0	34			26	30	0.86
12	25	F	80	30		60	0		0	10			24	28	0.86
13	17	F	122	88		94	0		0	66			22	26	0.84
14	23	M	130	60		110	12		0	34			26	32	0.90
Mean	22		102	52*	41	81**	7*	10***	2	29*	10**	17	24	30	0.80
SD	10		41	19	13	40	7	8	6	21	12	8	1	2	0.03

A = post-valvuloplasty; AN = annulus size; B = pre-valvuloplasty; BL = final balloon size; BL/AN ratio = balloon-to-annulus ratio; F = female;

F/U = follow-up; IG = infundibular peak-to-peak systolic gradient; M = male; PVG = pulmonary valvular peak-to-peak systolic gradient; RVSP = right ventricular systolic pressure.

P* < 0.05 when compared with pre-valvuloplasty value; *P* < 0.05 when compared to post-valvuloplasty value; ***not significant when compared to post-valvuloplasty value.

4. Discussion

Pulmonary valve Stenosis is one of the more common forms of congenital heart disease. It needs adequate treatment. The percutaneous dilation of the pulmonary valve with a balloon is considered the therapeutic modality of choice for the treatment of pulmonary valve stenosis in all group and with any valvular morphology. There is scanty literature which describes the experience with Inoue balloon catheter technique for BPV. It is one of the attractive alternatives to fixed size balloon techniques. Our study confirmed excellent outcomes with Inoue balloon technique in adult and adolescents patients of valvular PS. The procedure was successful in all patients. The appropriate BAR helped to alleviate complications like pulmonary regurgitation.

4.1 Safety, efficacy, and mid-term results

In this study, Inoue size-adjustable balloon catheter was found to be feasible, safe, and efficacious. And also, the beneficial effects of BPV were well maintained during follow-up, for as long as 1 year after the procedure. BPV of asymptomatic patients with isolated PS was has been controversial. In developing countries like India, the chances of inadequate or late follow-up are not insignificant hence it seems prudent to perform the procedure even in asymptomatic patients with significant trans-valvular gradients. Advantage of BPV includes not only the relief of symptoms but also prevention of secondary changes in the RV and progression to more severe degrees of stenosis. Due to a regression in the infundibular obstruction, considered a dynamic process that ebbs after a variable period of time the efficacy of pulmonary balloon valvuloplasty is underestimated when only the immediate results are considered. It is not clear whether infundibular stenosis is due to subvalvular muscular hypertrophy that subsequently

resolves after successful treatment of the valvular stenosis or to infundibular spasm. Some studies recommend the use of beta-blockers for patients after valvuloplasty. We prescribed oral Propranolol routinely for three months to all patients after BPV with residual gradients deemed secondary to infundibular hypertrophy secondary to PS.

4.2. Comparison with the fixed-size balloon technique

A wide variety of balloon catheters are available in market and can be used to successfully treat pulmonary valve stenosis. The success of BPV depends on the ability of the selected balloon to achieve stable and complete inflation. (19). Rao et al. have suggested to choose a low profile balloon capable of advancing through the smallest possible vascular access in smaller patients whereas a balloon with high rated burst pressure in adults. The Tyshak series of balloons (NuMed, Hopkinton, NY) like Tyshak, Tyshak II and Tyshak mini have been designed for balloon valvuloplasty and ongoing modifications have been made in order

to reduce the profile of the balloon catheter, while maintaining the resistance to balloon rupture. In adult patients where small vascular access size is less critical, there are a wide array of balloons with higher-rated burst pressure that have been developed, including the Z-med balloon series (NuMed), Diamond, Ultrathin, and XXL balloons (Boston Scientific, Natick, MA), Maxi-LD, Opta Pro, and Powerflex (Cordis Endovascular, Warren, NJ), and Marshal balloons (Meditech, Water town, MA). The Nucleus balloon (NuMed) is designed to inflate to a "barbell" shape similar to an Inoue balloon. However, there are currently no published reports of the use of this balloon for pulmonary valve dilation. (19). Double balloon technique is used in case of larger annular size with non availability of appropriate single balloon. It decreases the risk of hypotension during

inflation due to a continuous flow between the balloons during inflation. On the other side it may prolong the procedure time and requires extra venous access. Studies have suggested an equal efficacy when comparing double balloon technique to single balloon at similar balloon/annulus ratio. (3), (20). Liu et al. (21) have shown that adults can be treated with BPV using the Inoue balloon with encouraging immediate and long-term follow-up results that are similar to those in children using the single balloon. The Inoue balloon catheter technique is being used by us both for the ease of its use and easy availability of the balloon in our setup, whereas the fixed balloon technique used in 15 subjects during the study period so far in our institute has shown the known complications of Melon seeding, balloon rupture in two cases, and prolonged procedural time due to multiple exchanges in-between serial inflation. In three patients, the procedure was switched from fixed single balloon to Inoue balloon technique as the previous method was ineffective with significant slippage distally into pulmonary artery without abolition of waist ('pingpong' or 'melon-seeding' effect). The Inoue balloon catheter can be advanced freely in a relatively simpler RV inflow and outflow anatomy. However, in patients with "difficult-to-track" RV anatomy (severe tricuspid regurgitation with right atrial enlargement), the Inoue technique is limited by the rigidity of the metal stylet and also by inadequate support of the 0.025 "guide wire for tracking the Inoue catheter across the pulmonary valve. In two such cases the Inoue catheter (without the metal stylet) was slenderised over a 0.032" Amplatz super stiff guide wire (Cook Medical, Bloomington, IN), and tracked across the pulmonary valve.

4.3. Balloon sizing and pressure

Using an appropriate ratio of balloon to pulmonary valve hinge point diameter (BAR) is shown to optimise the chance of long-term success. The currently recommended ratio is 1.2–1.25. (19). Such sizing of balloon is likely to result in good relief of pulmonary valve obstruction while at the same time may help to prevent significant pulmonary insufficiency at late follow-up. In the present study, we chose the appropriate balloon size on the basis of echo-cardiographic and angiographic measurements of the valve annulus. The appropriate BAR was central in optimising the result and preventing the occurrence of pulmonary regurgitation in the study population. In our study, the disappearance of the "waisting" of the balloon was noted even at 2 atm of pressure (mean 2.6_0.4 atm) with resultant successful valvuloplasty. Rao et al. (17) have suggested to perform valvuloplasty sequentially at 3, 4, and 5 atm of pressure inflation. Yeager et al. (22) observed that pressures much higher than those required to abolish waisting of the balloon offer no advantage as the balloons maintain a relatively uniform diameter even at high pressures. High intra-balloon pressure may increase the chance of balloon rupture with the consequent problems.

4.4. Complications

We did not encounter any sustained arrhythmia, or haemodynamic compromise during the procedure. The incidence of residual pulmonary regurgitation (PR) after

BPV in the most published series ranged from 40 to 90%. (10), (23–25). Residual PR is usually of small magnitude after successful percutaneous dilation. (26). Its occurrence after the procedure may be explained by the fact that the mechanism of valvular opening through the use of balloon catheters consists of commissural separation, rupture, or even avulsion of the leaflets. (27). The VACA study, (10) incriminated the BAR greater than 1.4, and complex valvular morphology due to a previous surgical valvotomy or the presence of valvular dysplasia for moderate pulmonary insufficiency. Rupture of the right ventricular outflow tract has been observed to be the major fatal complication of BPV occurring mostly in neonates or infants with critical pulmonary stenosis and hypoplastic pulmonary valve. (10). However, this complication seems to be extremely rare in adults. (7), (28). Previous experiences have shown that once successful dilatation is achieved, the chances of restenosis are very small. (11), (29), (30). In the present study, no patient had a pulmonary valve restenosis during the mid-term follow-up period of 1 yr.

5. Conclusions

BPV is currently considered the therapeutic modality of choice for the treatment of PS. But limited information is available on the selection of balloon techniques in adolescent and adults, particularly with regard to follow-up results. The present study confirmed excellent safety and favourable early and mid-term outcomes for BPV for isolated PS, in adolescents and adults using the Inoue balloon catheter. Thus Percutaneous Inoue balloon technique is an attractive alternative for adolescents and adults with isolated PS and large annuli when performed by operators experienced with the Inoue balloon catheter.

6. Financial Statement

No grants, contracts, and other forms of financial support received for this article.

7. Conflicts of Interest

The authors have none to declare.

References

- [1] Marelli AJ, Mackie AS, Ionescu-Ittu R, Rahme E, Pilote L. Congenital heart disease in the general population: changing prevalence and age distribution. *Circulation*. 2007;115:163–172.
- [2] Kan JS, White Jr. RI Jr., Mitchell SE, Anderson JH, Gardner TJ. Percutaneous balloon valvuloplasty: a new method for treating congenital pulmonary-valve stenosis. *N Engl J Med*. 1982;307:540–542.
- [3] Rao PS. Balloon pulmonary valvuloplasty: a review. *Clin Cardiol*. 1989;12 (2):55–74.
- [4] Inoue K, Owaki T, Nakamura T, Kitamura F, Miyamoto N. Clinical application of transvenous mitral commissurotomy by a new balloon catheter. *J Thorac Cardiovasc Surg*. 1984;87:394–402.

- [5] Lau KW, Hung JS, Wu JJ, Chem MS, Yeh KH, Fu M. Pulmonary valvuloplasty in adults using the Inoue balloon catheter. *CardiovascDiagn.* 1993;29:99–104.
- [6] Bahl VK, Chandra S, Wasir HS. Pulmonary valvuloplasty using Inoue balloon catheter. *Int J Cardiol.* 1994;45(2):141–143.
- [7] Chen CR, Cheng TO, Huang T, et al. Percutaneous balloon valvuloplasty for pulmonic stenosis in adolescents and adults. *N Engl J Med.* 1996;335:21–25.
- [8] Warnes CA, Williams RG, Bashore TM, et al. ACC/AHA 2008 guidelines for the management of adults with congenital heart disease: a report of the American College of Cardiology/American Heart Association Task Force on Practice Guidelines (writing committee to develop guidelines on the management of adults with congenital heart disease). *Circulation.* 2008;118:e714–e833.
- [9] Cooper JW, Nanda NC, Philipot EF. Evaluation of valvular regurgitation by color Doppler. *J Am SocEchocardiogr.* 1989;2:56–66.
- [10] McCrindle BW. Independent predictors of long-term results after balloon pulmonary valvuloplasty. *Circulation.* 1994;89:1751–1759 (25).
- [11] Rao PS. Long term follow up results after balloon dilatation of pulmonic stenosis, aortic stenosis, and coarctation of the aorta: a review. *ProgCardiovasc Dis.* 1999;42:59–74.
- [12] Rao PS. Indications for balloon pulmonary valvuloplasty. *Am Heart J.* 1988;116 (6 Pt 1):1661–1662.
- [13] Nadas AS. Pulmonic stenosis – indications for surgery in children and adults. *N Engl J Med.* 1972;287(23):1196–1197.
- [14] Parent JJ, Hoyer MH. Delayed success of balloon dilation for coexisting pulmonary valve stenosis and sinotubular narrowing. *Congenit Heart Dis.* 2014;9:216–220 Epub 2013 June 27.
- [15] Earing MG, Connolly HM, Dearani JA, Ammash NM, Grogan M, Warnes CA. Long-term follow-up of patients after surgical treatment for isolated pulmonary valve stenosis. *Mayo Clin Proc.* 2005;80:871–876.
- [16] Lee ML, Peng JW, Tu GJ, Chen SY, Lee JY, Chang SL. Major determinants and long-term outcomes of successful balloon dilatation for the pediatric patients with isolated native valvular pulmonary stenosis: a 10-year institutional experience. *Yonsei Med J.* 2008;49:416–421.
- [17] Khambatta HJ, Velado M, Gaffney JW, Schechter WS, Casta A. Management of right ventricular outflow tract reactivity following pulmonary valve dilatation under general anesthesia: experience of a medical mission. *PaediatrAnaesth.* 2006;16:1087–1089.
- [18] Rao PS. Percutaneous balloon pulmonary valvuloplasty: state of the art. *Catheter CardiovascInterv.* 2007;69:747–763.
- [19] Rao PS, Fawzy ME. Double balloon technique for percutaneous balloon pulmonary valvuloplasty: comparison with single balloon technique. *J Interv Cardiol.* 1988;1:257–262.
- [20] Liu S, Xu X, Liu G, Ding X, Zhao X, Qin Y. Comparison of immediate and longterm results between the single balloon and Inoue balloon techniques for percutaneous pulmonary valvuloplasty. *Heart Lung* Circ. 2015;24(January (1)):40–4510.1016/j.hlc.2014.05.020.
- [21] Yeager SB. Occlusion time and inflation pressure in pulmonary valvuloplasty (letter). *Am J Cardiol.* 1985;55:619.
- [22] Berman Jr. WJr., Fripp RR, Raiser BD, Yabek SM. Significant pulmonary valve incompetence following oversize balloon pulmonary valvuloplasty in small infants: a long-term follow-up study. *Catheter CardiovascInterv.* 1999;48:61–65.
- [23] Abu Haweleh A, Hakim F. Balloon pulmonary valvuloplasty in children: Jordanian experience. *J Saudi Heart J.* 2003;15:31–34.
- [24] Garty Y, Veldtman G, Lee K, Benson L. Late outcomes after pulmonary valve balloon dilatation in neonates, infants and children. *J Invasive Cardiol.* 2005;17:318–322.
- [25] Rao PS, Fawzy ME, Solymar L, Mardini MK. Long-term results of balloon pulmonary valvuloplasty of valvar pulmonic stenosis. *Am Heart J.* 1988;115:1291–1296.
- [26] Walls JT, Lababidi Z, Curtis JJ. Morphologic effects of percutaneous balloon pulmonary valvuloplasty. *South Med J.* 1987;80:475–478. 180 C. Lanjewar et al. / *Indian Heart Journal* 69 (2017) 176–181
- [27] Karagoz T, Asoh K, Hickey E, et al. Balloon dilation of pulmonary valve stenosis in infants less than 3 kg: a 20-year experience. *Catheter CardiovascInterv.* 2009;74:753–761.
- [28] Rao PS, Galal O, Patnana M, Buck SH, Wilson AD. Results of three to 10 year follow-up of balloon dilatation of the pulmonary valve. *Heart.* 1998;80:591–595.
- [29] Qian X, Qian Y, Zhou Y, Yang X. Percutaneous pulmonary balloon valvuloplasty provides good long-term outcomes in adults with pulmonary valve stenosis. *J Invasive Cardiol.* 2015; Epub ahead of print.
- [30] Gielen H, Daniëls O, van Lier H. Natural history of congenital pulmonary valvar stenosis: an echo and Doppler cardiographic study. *Cardiol Young.* 1999;9: 129–135.
- [31] Rowland DG, HammillWW, Allen HD, Gutgesell UP. Natural course of isolated pulmonary valve stenosis in infants and children utilizing Doppler echocardiography. *Am J Cardiol.* 1997;79:344–349.
- [32] Vermilion RP, Snider R, Bengur AR, Meliones JN. Long-term assessment of right ventricular diastolic filing in patients with pulmonic valve stenosis successfully treated in childhood. *Am J Cardiol.* 1991;68:648–652.