

Surgical Versus Medical Management of Appendicitis during Pregnancy

Harshit Agarwal¹, Saroj Chhabra Kapoor², Siddharth Jai Singh³

¹Post Graduate Resident, Department of General Surgery, MGMCH, Jaipur, India

²Assistant Professor, Department of General Surgery, MGMCH, Jaipur, India

³Post Graduate Resident, Department of General Surgery, MGMCH, Jaipur, India

Abstract: Background: Appendectomy is known as most common non-obstetrical operative procedure in a pregnant patient. Making an Early diagnosis and starting management is must to prevent complications. Aims: 1. To know better Management of Appendicitis in Pregnancy whether Surgical or Medical, reduce risk of Maternal and Fetal Mortality due to Appendicitis in Pregnancy. Material & Method: 20 pregnant patients in different Gestational age admitted to Mahatma Gandhi hospital were included in study. Result: Surgical management was successful in 85% of cases whereas Medical management was Successful in 15% cases increasing risk of maternal & fetal mortality. Conclusion: Pregnant patients with appendicitis should go through Emergency appendectomy as early as possible irrespective of gestation age.

Keywords: Pregnancy, appendicitis

1. Introduction

In 1886, Reginald Fitz¹ of Boston identified appendix as the primary cause of pain in right lower quadrant pain. He coined the term appendicitis, & recommended early removal of appendix.

It is by far the most common extra-uterine surgical emergency encountered during pregnancy²

Appendectomy is known as most common non-obstetrical operative procedure in a pregnant patient with an estimated frequency of one case of acute appendicitis per 1500 pregnancy.³

The Etiology and pathogenesis of it is not known although many theories have been proposed; including luminal obstruction, direct invasion of pathogen and inflammatory response triggered by pathogens or other stimuli.⁴

Pregnancy continues to obscure the accurate Diagnosis of acute appendicitis due to gestational physiological changes.⁵

Acute appendicitis can occur at any time during gestation but is most common in first and second trimester.

Multiple investigations or false diagnosis can delay surgery and increase the risk of appendix perforation, which is associated with higher rates of maternal morbidity and fetal mortality.⁶

The risk for pre-mature delivery is the greatest during the first week after surgery. However maternal mortality is very low⁷

Thus making an accurate diagnosis and starting management is must to prevent complications.

Complications are associated with increased risk of premature labour, abortion, maternal and fetal mortality.

2. Aims & Objective

- 1) To know better Management of Appendicitis in Pregnancy whether Surgical or Medical.
- 2) To reduce risk of premature labour, abortion, Maternal and Fetal Morbidity and Mortality due to Appendicitis in Pregnancy.

3. Materials & Methods

Source of data (sample)

20 Pregnant patients in different Gestational age admitted to Mahatma Gandhi hospital were included in study.

Method of collection of data

Pregnant females diagnosed with acute appendicitis irrespective of gravid status on the basis of detailed clinical history and a careful general physical & systemic examination with necessary investigation were included in this study.

Inclusion criteria:

1. Pregnant patients complaining of abdominal pain of new onset in Right side of abdomen were selected.
2. Well informed patients, willing to comply with the study protocol.

Exclusion criteria:

1. Differential diagnosis of appendicitis (ectopic pregnancy, pyelonephritis, cholecystitis)
2. Appendicular lump in right iliac fossa
3. Immuno-compromised patients.

4. Observation and Result

Of the total 20 patients 14 patients (70%) were managed Surgically and rest 6 patients (30%) were managed conservatively.

Patients presenting during the 1st trimester were 3(15%), during second trimester were 12(60%), during the third trimester were 5(25%).{figure1}

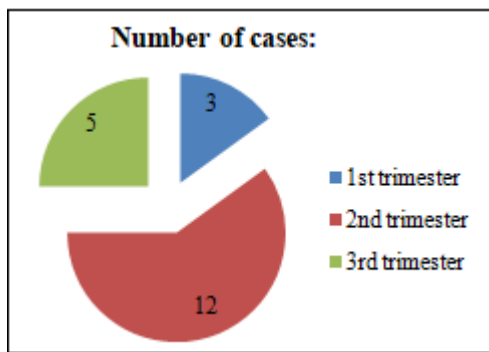


Figure1: Number of cases presenting in different trimester

Of the total 14 patients who underwent surgical management 12 patients(85%) succeeded pregnancy without maternal and fetal complications. 1 patient(7.5%) developed threatened abortion during 2nd trimester which also succeeded & 1 patient(7.5%) underwent pre-mature labour during 3rd trimester leading to premature birth, however baby was managed in NICU.{table 1}

Table 1: Fate of 14 patients who went through surgical management

	Ist trimester	2 nd trimester	3 rd trimester
Total no. Of cases	3	9	2
Abortion	-	-	-
Threatened abortion	-	1	-
Premature labour	-	-	1
No sequel	3	8	1

Of the total 6 patients who were managed conservatively 1 patient(16.6%) ended with abortion and 1 patients(16.6%) ended with threatened abortion & rest three patients ended with premature labour(50%).only 1 patient(16.6%) succeeded pregnancy.

Table 2: Fate of 6 patients who went through Medical management.

	Ist trimester	2 nd trimester	3 rd trimester
Total no. Of cases	-	3	3
Abortion	-	1	-
Threatened abortion	-	-	1
Premature labour	-	2	1
No sequel	-	-	1

Surgical management was successful in 85% of cases whereas Medical management was Successful in 15% cases increasing risk of maternal & fetal mortality.{figure2}

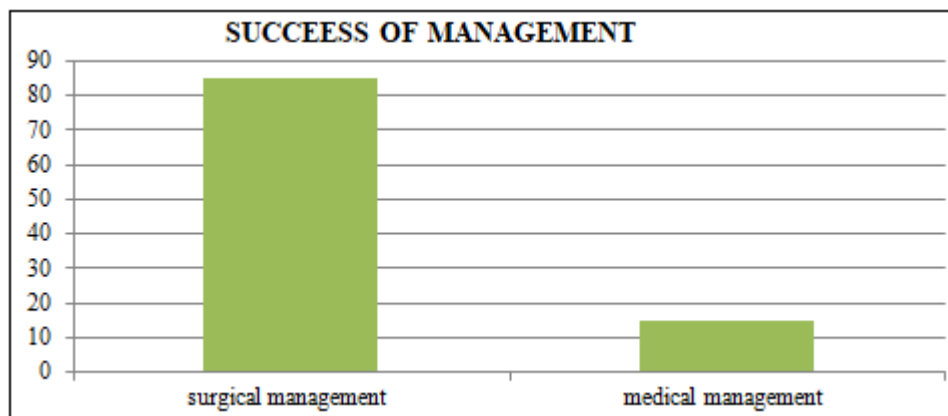


Figure 2: Comparison between Success of Surgical & Medical management

5. Discussion

Acute appendicitis can occur at any time during gestation but is most common during second trimester (45%), during 1st trimester (30%) & during third trimester around (25%).⁸.But in our study 60% cases presented during 2nd trimester & 25% presented during 3rd trimester.

The pregnant patient with Appendicitis presents unique challenges to both the surgeon & gynaecologist. First, the diagnosis of pregnancy needs confirmation at the time of presentation. Secondly, the anaemia & physiological changes that normally occur during pregnancy alter physical findings & laboratory values that are often used for diagnosing appendicitis. Thirdly, cases of appendicitis during pregnancy produce significant morbidity & mortality if not promptly identified and treated. Fourthly the treating surgeon has limitations in the use of certain diagnostic procedures because of possible teratogenicity. Finally the surgeon is treating two patients simultaneously, the mother

& foetus & must be aware of the potential effects of treatment on both patients at all times⁹

Appendicitis presents with symptoms such as nausea, vomiting, Anorexia & abdominal discomfort that are similar to those of pregnancy itself.¹⁰ Also appendix is superiorly & laterally displaced by enlarging Uterus, thus pushing it away from its usual location of right iliac fossa. The appendixes remain in Rt.ilic fossa during 1st trimester, moves to pelvic brim during 2nd trimester & reaches Rt.hypochondrium in 3rd trimester.

Rebound tenderness and guarding of the abdominal wall are less commonly seen due to laxity of abdominal muscle wall during pregnancy.

Once acute appendicitis is suspected in pregnant women a close working relationship is required between surgeon, obstetrician and anaesthesiologist to minimize maternal & fetal mortality & morbidity.¹¹

Delay of operation correlates to inflammatory changes in appendix & higher maternal & fetal mortality rate, thus requiring early surgical intervention. Studies have shown that surgery within 24 hours have a relatively lower rate of appendicular perforation.^{10,12}

Early appendectomy is the secret of success & is the treatment of choice recommended at all stages of pregnancy.¹³

Appendectomy is usually performed by a muscle splitting incision over the point of maximum tenderness in rt. Lower quadrant & modified as per point of maximum tenderness. The appendix is accessed through open Lanz incision, which is typically made through McBurney's point. This method has main advantage of better visualization of peritoneum, shorter operating time, less exposure to CO₂, less risk of pneumoperitoneum.¹⁴

Laparoscopy was initially contra-indicated in pregnancy, recent studies have shown that it is well tolerated by mother & fetus¹⁵. Open surgery is believed to be better & generally preferred over laparoscopic method in late second & third trimester.¹⁶

6. Conclusion

Appendicitis in pregnancy has been a difficult problem in comparison to non-pregnant patients. Due to risk of maternal & fetal mortality, appendicitis should be ruled out in pregnant women presenting with complaints of new abdominal pain.

Post diagnosis time should not be wasted in conservative (medical) management.

Pregnant patients with appendicitis should go through Emergency appendectomy as early as possible (within 24 hrs. of diagnosis) as it decides the fate of two lives, more the delay more the risk of abortion & complications.

References

- [1] Fitz RH. Perforating inflammation of the vermiform appendix, with special reference to its early diagnosis & treatment. *Am J Med Sci* 1886;**92**:321-346
- [2] Guttman R, Goldman RD, Koren G. Appendicitis during pregnancy. *Can Fam Physician* 2004;**50**:355-7
- [3] Mazze RI, Kallen B. Appendectomy during pregnancy. A Swedish Registry Study of 778 Cases. *Obstet Gynaecol* 1991;**77**:835-40
- [4] Anderson REB, Lambe M. Incidence of appendicitis during pregnancy. *Int J Epidemiol* 2001;**30**:1281-5.
- [5] Fallon WF, Newman JS, Fallon GL, Malangoni MA. The surgical management of intra abdominal inflammatory conditions during pregnancy. *Surg Clin North Am* 1995;**75**:15-31
- [6] Yilmaz H, Akgun Y, Bac B, Celik Y. Acute appendicitis in pregnancy – risk factors associated with principle outcomes: A Case control study. *Int J Surg*. 2007;**5**(3):192-197.
- [7] AL-Mulhim AA. Acute appendicitis in pregnancy. A review of 52 cases. *Int Surg* 1996;**81**:295-7

- [8] Firstenberg MS, Malangoni MA. Gastrointestinal surgery during pregnancy. *Gastroenterol Clin North Am* 1998;**27**:73-88
- [9] Kort B, Katz VL, Watson WJ. The effect of non-obstetric operation during pregnancy. *Surg Obstet Gynecol* 1993;**177**:371-6
- [10] Pastore PA, Loomis DM, Sauret J. Appendicitis in pregnancy. *J Am Board Fam Med* 2006;**19**:621-6
- [11] Tamir IL, Bongard F S, Klein SR. Acute appendicitis in a pregnant patient. *Am J Surg* 1990;**160**:571-6
- [12] Humes DJ, Simpson J. Acute appendicitis. *Br Med J* 2006;**333**:530-4
- [13] Calhoun BC. Gastrointestinal disorders in pregnancy. *Obstet Gynaecol Clin North Am* 1992;**19**:733-44
- [14] Borst AR. Acute appendicitis: Pregnancy complicates this diagnosis. *JAAPA* 2007;**20**:36-41
- [15] Carver TW, Antevil J, Egan JC, Brown CV. Appendectomy during early pregnancy: what is the preferred approach? *Am Surg* 2005;**71**:809-12
- [16] Melnick DM, Wahl WL, Dalton VK. Management of general surgical problems in the pregnant patient. *Am J Surg* 2004;**187**:170-80