

# Sonographic Diagnosis of Ascariasis Lumbricoides Presenting As a Case of Massive Abdominal Swelling: A Case Study

Ajadi TA<sup>1,2</sup>, Kiridi EK<sup>1,2,4</sup>, Aremu AA<sup>3</sup>, Kiridi EGE<sup>2</sup>

<sup>1</sup>Radiology Department Niger Delta University

<sup>2</sup>Silhouette Radiodiagnostic Consultants

<sup>3</sup>Radiology Department, LAUTECH Ogbomoso

<sup>4</sup>Federal Medical Centre Yenagoa

**Abstract:** *Intestinal parasitic infections are common in childhood and faecal laboratory analysis has been the mainstay of diagnosis. With advancement in technology, the diagnosis of parasitic infections with high resolution ultrasound scan is now possible. We present a case a case of ascariasis lumbricoides diagnosed on ultrasound.*

## 1. Introduction

Diagnosis of intestinal parasites has been known over the years by faecal laboratory analysis. This has been improved and played significant role over the years. The advance in technology has also play major role in the use of radiological equipment in diagnosis of these parasites and ruling out of some differentials especially in unconventional presentation of some clinical symptoms.

## 2. Case Report

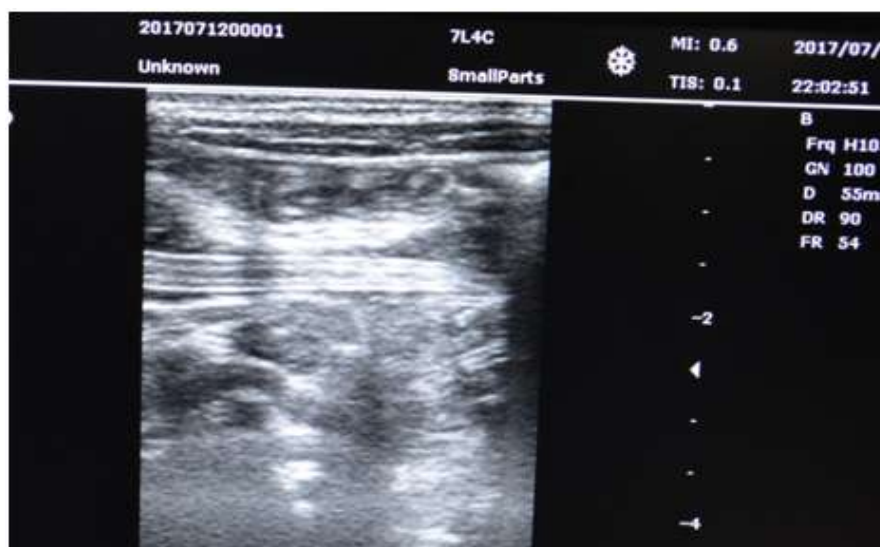
KO is a 7-year old boy who presented in the federal medical center yenagoa with a one month history of progressive abdominal swelling, weight loss, poor appetite, low grade fever and generalized weakness all of one month duration. There was no history of vomiting or frequent stooling. Both parents are unemployed and they reside in an uncompleted government building with no access to portable drinking water or toilet facility. The mother hawks oranges

while the father does brick laying in building sites. He is the 3<sup>rd</sup> of three siblings.

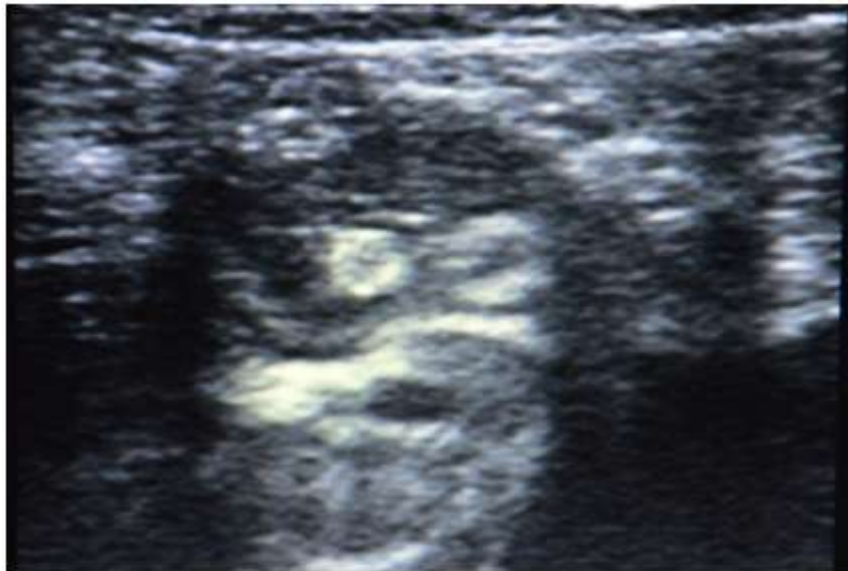Examination findings revealed moderate palour. There was no evidence of jaundice or fever. His vital signs were stable. Abdominal examination showed marked abdominal swelling with present bowel sounds. The other systems were normal.

Results of his full blood showed a reduction in haemoglobin level with a mildly elevated Erythrocyte sedimentation rate. Urinalysis, E/U/Cr were normal

High resolution scan done in our facility using a high frequency (8.0mhz- 10Mhz) linear ultrasound probe showed the classical linear echogenic structures with central hypoechoic area and assessment of intestinal parasites was made. The rest of the demonstrated bowel loops and the abdominal organs appear within normal limits. No ascites and no para-aortic lymph nodes noted



**Figure 1:** Showing the Ascariasis Lumbricoides worm in longitudinal plane. Note the well defined tissue planes of the worm



**Figure 2:** Showing Ascariasis Lumbricoides in the transverse planes the worm in traverse plane

### 3. Discussion

*Ascaris lumbricoides* is an intestinal nematode that belongs to the super family of Ascaridodea. It is one of the major causes of unwarranted surgery in the past especially in the developing countries. It is known to be endemic in the areas where there is poor hygienic standards.

Human become infested by *A lumbricoides* by ingesting water, food or soil contaminated by faeces containing the larvae. The *Ascaris* larvae in the bowel pass through the intestinal wall into the venous system, and when they get to the lungs, the larvae penetrate into the airspace and are conveyed up the trachea into the oesophagus and then swallowed. These larvae mature into the adult worms in the jejunum, where they mate and produce eggs. These eggs are excreted in the faeces and are infective to humans, thus completing the cycle [1]. Presence of the larvae and reaction in the respiratory system can produce some respiratory symptoms like cough and some form of non-specific pneumonitis. These findings were not seen in out index patient who did not present with any respiratory symptoms.

The male and female mate and many eggs are produced which are passed with the faeces [2]. Due to the large number of worms, mass-like worm lesion can be produced which can be accompany by complication like obstruction and even perforation in some cases. The worms have been noted to cause obstruction in the bile and pancreatic ducts in some instances. The presence of the worm in the system leads to the clinical symptoms and some radiological features. The migration of the larvae led to host immune reaction, and the presence of adult worm can lead to mechanical obstruction. Malaise and poor appetite on the part of patient can account for some nutritional symptoms like weight loss and weakness.

There is a high prevalence rate of ascariasis lumbricoides in the underdeveloped countries. In Nigeria, different prevalence rate is noted for different region based on difference in literacy, hygiene. The prevalence of 4intestinal

parasitism in the north-east was 80.9% [3], 28% for south-west [4] and 55.2% [5] in the south-eastern Nigeria and 67.2% [6] in the south-south Nigeria4.

The role of radiology in the present days of cutting-edge technology cannot be over-emphasized. Imaging modalities played significant role in diagnosis and follow up of the treatment and to prevent unnecessary surgical procedure if it is diagnosed in the early stage, and evaluation of complication that might arise from those that require surgery.

Imaging modalities that can be used include plain radiograph, ultrasound scanning, contrast studies, computerized tomography scan and even magnetic resonance images.

Plain radiograph has been playing significant role as far as the early stages of imaging modalities. It is cheap and readily available, The main drawback is the use of ionizing radiation. A reported case of intestinal obstruction by massive Ascariasis simulating intussusceptions by Ogunseyinde et al [7] is one of the ingenuity of using plain radiograph in the early practice of radiology in Nigeria.

The use high frequency ultrasound linear probes which is readily available has significantly improved the diagnoses of this parasite. However, the skill of the sonologist is a key factor in the usage of this modality. longitudinal scan they appear as longitudinal/tubular structure with central hypoechoic area and echogenic tubular wall (see Image 1 and 2). As seen in our patients, the muscular layers may be delineated with increasing probe frequency. Various terms were used in describing the appearance of this parasite which include 'winding highway', 'parallel lines', 'railway track' sign on longitudinal scan. 'Doughnut', 'target sign', 'bull eye's' appearances were used on transverse scan. The differential diagnosis of this appearance include nasogastric and jejunostomy feeding tubes, surgical drainage tubes, a ventriculoperitoneal shunt, or even a normal bowel during peristalsis [8]. The worm can also be seen on barium meal

and follow through, it appears as a radiolucent tubular filling defects within the bowel lumen [9].

The use of computerized tomography scan is not always encouraged in diagnosis of ascaris worm infestation in paediatric age and even in adult, except in the case of inconclusive evaluation of some lesion, where the parasites are seen as hyperdense longitudinal structure or tubular structure and can mimic a mass in their large numbers. The use of endoscopic retrograde cholangiography is for both diagnosis and therapeutic purpose.

Magnetic resonance imaging make use of non-ionizing radiation but it is not readily available in the developing countries. They are seen as hyperintense structure within the bowel loops on T2 weighted images probably due to fluid within their lumen.

#### 4. Conclusion

The prevalence of parasitic infestations is common in the underdeveloped countries. The routine use of high resolution linear probes when evaluating abdominal pathology in children is of utmost important in diagnosing and ruling out of some differential. We therefore encourage radiologists and other managing paediatric team to encourage the use of high resolution linear probes in abdominal ultrasound of the paediatric age group.

#### References

- [1] Ugwu AC, Ohagwu CC, Anakwe AC, Erondu OF. Parasitology: Appearances of *Ascaris lumbricoides*, *Colon taeniasis*, *Cystercircus cellulosae*, *Schistosoma haematobium*, *Drancuculus medinesis* and *Echinococcus granulosus* infestations. *African Journal of Biotechnology*. 2008 Dec;7(25):4732-4736.
- [2] Ukoli FMA. Introduction to Parasitology on Tropical Africa Epidemiology, prevalence and treatment of *Ascaris lumbricoides* 1991. 249-252.
- [3] Damen J G, Luka J, Biwan E I, Lugos M. Prevalence of intestinal parasites among pupils in rural North Eastern, Nigeria. *Niger Med J* 2011;52:4-6
- [4] Salako A.A. Effects of portable water availability on intestinal parasitism among rural school children with sewage disposal facilities in the Mjidum and Owutu sub-urban community of Lagos state. *Nigeria Medical practioner* 2001; 39: 3-4.
- [5] Agwu N. A., Incidence of intestinal helminthiasis in school children in Aba urban city, Abia state, Nigeria, *International Journal, Environmental Health and Human Development*. 2001; 1: 47-51.
- [6] Meremikwu M.M., Antia-Obong O.E., Asindi A.A., Ejezie G.C. Prevalence and Intensity of intestinal Helminthiasis in Pre-School children of peasant farmers in Calabar, Nigeria. *Nigerian Journal of Medicine*. 1995; 2: 40-44
- [7] Ogunseyinde AO, Shonubi AMO, Akingbehin N. Intestinal obstruction by massive Ascariasis simulating intussusceptions. *Nigerian Journal of Paediatrics*. 1987;14:31
- [8] Peck RJ. Ultrasonography of intestinal ascariasis. *J Clin Ultrasound* 1990;18:741-743.

- [9] Ankur G, Shivanand G, Jaganathan S. Tube within Tube: *Ascaris* in Bowel and Biliary-Tract. *Am J Trop Med Hyg*. 2010 Nov;83(5):962.