

A Rare Presentation of Glomus Tumor as Acute Paronychia: Case Report

Dr Mazharuddin Ali Khan¹, Dr. Mohammed Aman-Ul-Haq Qureshi², Dr. Wasif Ishaqui³

¹Department of Orthopedics, Professor and Head of Department, Owaisi Hospital and Research Centre, Deccan College of Medical Sciences

²Department of Orthopedics, Assistant Professor, Owaisi Hospital and Research Centre, Deccan College of Medical Sciences

³Department of Orthopedics, Post-Graduate, MS Orthopedics, Owaisi Hospital and Research Centre, Deccan College of Medical Sciences

Abstract: A glomus tumor is a benign vascular tumor derived from the modified smooth muscle cells of the glomus body. The lesions develop as small blue-red nodules that are usually located in the deep dermis or subcutis of the upper or lower extremity. The single most common site is the subungual region of the finger, but other common sites include the palm, wrist, forearm and foot. In the present study, we report the case of a 38-year-old female patient diagnosed with digital glomus tumor of Right-hand middle finger for 10 years misdiagnosed as Acute Paronychia, which on further evaluation diagnosed to be Glomus tumor, later treated with Local Excision. Histopathological examination revealed that the tumor was a well-circumscribed nodule with focal invagination of tumor cells into the adjacent upper dermis. The tumor was composed of solid sheets of cells interrupted by vessels of varying size. The majority of glomus tumors may be treated adequately by the correct diagnosis and simple excision.

Keywords: glomus tumor, finger, paronychia, chronic pain

1. Introduction

Glomus tumors constitute 1.6% of all soft tissue tumors and are distinctive neoplasms that resemble the Sucquet-Hoyer canal of the normal glomus body, located in the subcutaneous tissue, which is responsible for the regulation of temperature and blood pressure (1–3). These tumors are usually solitary, deep blue to purple in color, and accompanied by the classic triad of pain, cold sensitivity and point tenderness (2). The glomus tumor was originally considered to be a form of angiosarcoma until the findings demonstrated by Masson (4) in 1924 (3). Masson compared the tumors with the normal glomus body and suggested that the lesion represented hyperplasia or overgrowth of this structure (3). The most common site for these tumors is the distal extremities, particularly in the subungual digital areas, although tumors have been identified in extradigital sites including the bone, tongue, stomach, rectum, mesentery, lung, mediastinum, sacrum, coccyx, and the head and neck (5,6).

2. Case report

A 38-yr. old female patient, resident of Kurmaguda, Hyderabad, Telangana, India is a housewife came to Orthopedic Outpatient department with the **Chief Complaints** of:

Pain in right hand middle finger nail pulp since 10 yrs.
Paresthesia's and hypersensitivity to cold since 10 yrs.

3. History of Present Illness

Patient was apparently asymptomatic 10 yrs. ago, from then she developed pain in right hand middle finger nail pulp, with gradual onset, progressive, the pain was so severe that she was unable to sleep at night, she complained of almost

incessant pain and paresthesia from the right side of neck, and along his entire right upper limb.

Patient has recent Dermatologist opinion where she was diagnosed as Acute Recurrent Paronychia and? Glomus tumor, and was prescribed Antibiotics and Analgesics and Anti-Inflammatory for a week period but the symptoms does not subside.

Later patient has General surgeon opinion where her condition – (pain in the right-hand middle finger pain), Diagnosed as Glomus tumor where surgical removal was done, but after a brief period of time, the symptoms reappear and this time a small non blanchable purplish swelling appeared at the affected area.

Patient consulted to Ortho OPD for the non-subsiding lesion and pain at right hand middle finger, and diagnosed to be recurrent Glomus tumor, for which she was advised X-Ray, and MRI of right hand. There is no history of DM, HTN, HYPOTHYROIDISM, ASTHMA, EPILEPSY. There is no history of previous Surgeries.

On clinical examination,

Love test and the Hildreth sign are positive. To perform the Love test, a fine instrument, such as a pin or a toothpick, is used to elicit point tenderness in the affected region; this maneuver elicits no pain in the area immediately adjacent to the pinpoint area. The Hildreth sign is the disappearance of pain after a tourniquet is placed on the extremity proximal to the lesion. The vascular nature of the tumor is probably the reason why the pain resolves

Local Examination: Right Hand Middle Finger (Figure-1)

- Erythematous tender inflamed lesion which bluish in color and it is non blanchable.
- Local soft-tissue tenderness and thickening is present.
- Rest of the fingers of same hand and other hand are normal.
- Peripheral pulses are normally felt.
- No scars, no sinuses, or discharges or deformity noted
- Severe excruciating and sharp pain present on palpation, out of proportion to its size.

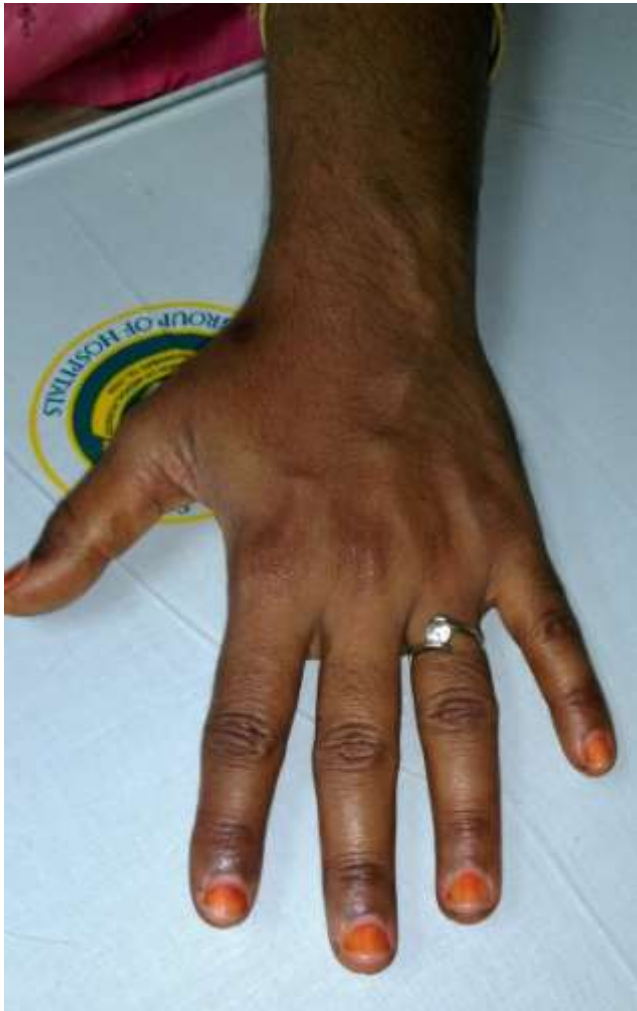

Figure 1

Differential Diagnosis

- 1) Epidermal inclusion cyst
- 2) Enchondroma
- 3) Osteoid osteoma

- 4) Ingrown toenail
- 5) Chronic osteomyelitis
- 6) Entrapment neuropathy
- 7) Clinical depression/Chronic Regional Pain Syndrome
- 8) Metastatic tumor

Investigations

Results of plain radiography (**X-RAY**) are often unremarkable, but radiographs may show a well-circumscribed osteolytic lesion with a sclerotic border or a soft-tissue mass causing bone erosion. (**Figure-2**)

Computed tomography (CT) is indicated for accurately assessing tiny abnormalities of the cortex of the distal phalanx. CT scans demonstrate a nonspecific nodule or mass, either in the soft tissue or within the bone.

For the initial workup, color Doppler ultrasonography (US) is an appropriate first test. US may be helpful for depicting a cystic or a vascular component of a tumor. US and Doppler study yield better visualization of the tumors than standard radiology does; however, these sonographic methods are highly operator-dependent.

Magnetic resonance imaging (MRI) offers whole imaging of the soft parts of the nail unit and the underlying bone. MRI may be performed to localize the tumor before surgery. On T1-weighted images, a glomus tumor appears as a dark, well-delineated mass. T2-weighted images are best for visualizing glomus tumors, which appear as bright and well-delineated masses. Because the lesion is richly vascularized, it demonstrates marked contrast enhancement on MRI performed after an intravenous injection of gadolinium-based contrast material. (**Figure-3**)

Treatment

Treatment of glomus tumors is by surgical excision under local anesthesia and should be accurately localized by marking the lesion just before surgery. (**Figure-4**)

Post-Operative Images. (**Figure-5, Figure-6**)

Meticulous and complete excision of the usually well encapsulated lesions is curative although reoperation rates of 12% to 24% have been reported.

Biopsy report (**Figure-7, Figure-8**)

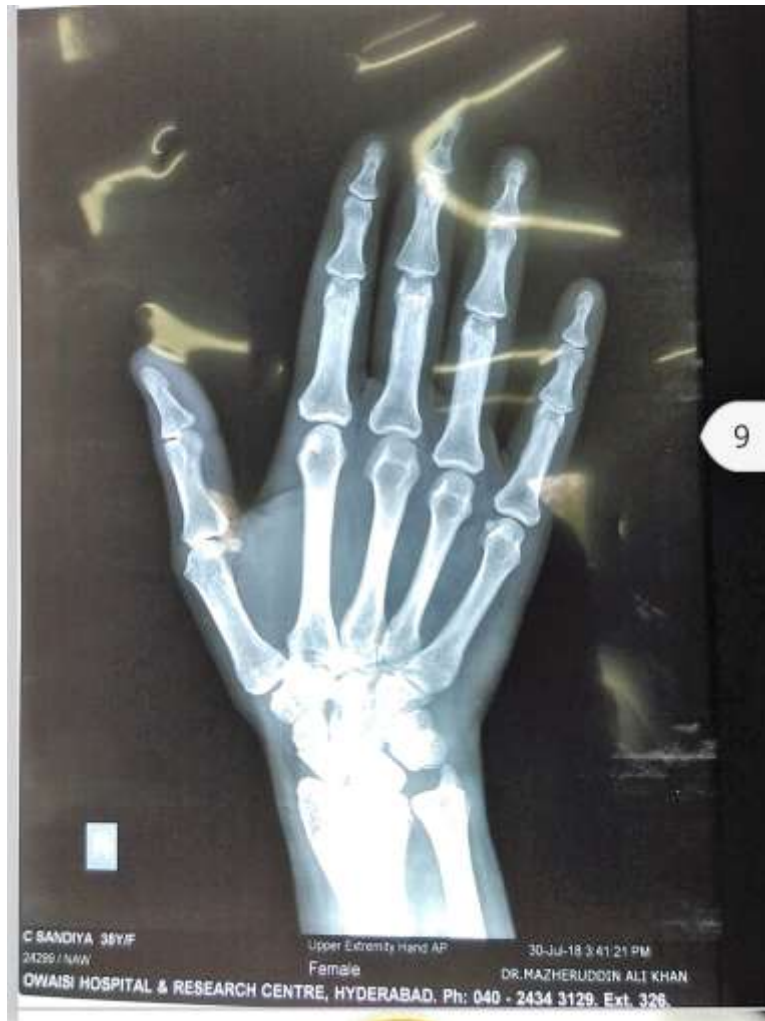

Figure 2

OWAISI HOSPITAL & RESEARCH CENTRE
1000 BEDDED MULTI SPECIALITY HOSPITAL WITH AFFORDABLE CHARGES
D.M.R.L.K. Road, Sarfoosh Nagar, Kancharbagh, Hyderabad - 500 058. T.S. INDIA
Tel: 24343129, 24340669, 24341757, 24340244, Adm: 24340244, Ext: 306, RMO Ext: 333
DECCAN COLLEGE OF MEDICAL SCIENCES

M. R. I.

NAME: C. SANDHYA DATE: 31/07/18
AGE: 38Y SEX: FEMALE MRI NO: 0718

MRI RIGHT HAND

TECHNIQUE:
T1 and PD FS FSE Axial
T1, T2, T2 Medico, PD FS FSE Coronal
T1, PD FS FSE Sag

FINDINGS:

- STIR T2 lobulated Hyperintense area over dorsal aspect of distal middle finger causing erosion of distal phalanx (about 10x9mm) -? glomus tumour.
- STIR Hyperintense areas in soft tissues and proximal phalanges ring & middle fingers -Likely edema.
- Visualized tendons appear normal.
- Bone marrow signal morphology is normal.
- Soft tissue edema visualized.

For further evaluation / HPE correlation.

DR. V. MAHENDER
RADIOLOGIST

We Care for your Health round the clock
• Ambulance Services • All Emergency with Traumacare • 24 Hour Pharmacy • Diagnosis

Figure 3

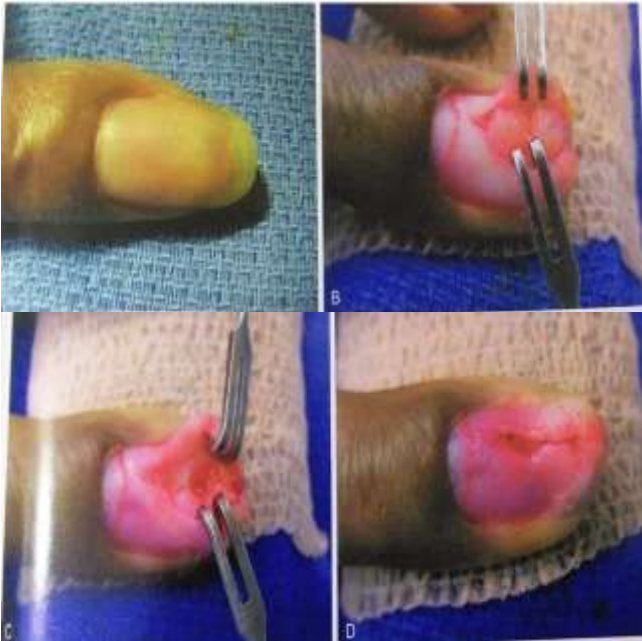

Figure 4: A. Subungual glomus tumor with bluish discoloration. B. Nail removed and nail bed incised to expose under glomus tumor. C. Glomus tumor excised with preservation of nail bed. D. Nail bed sutured.

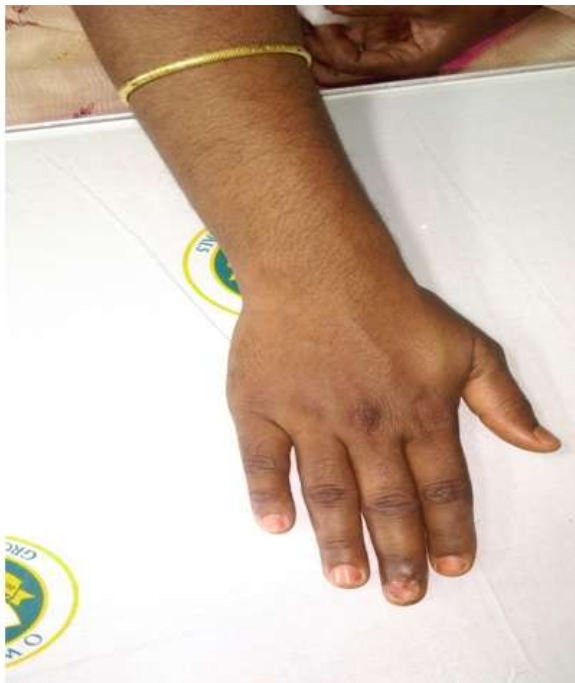

Figure 5

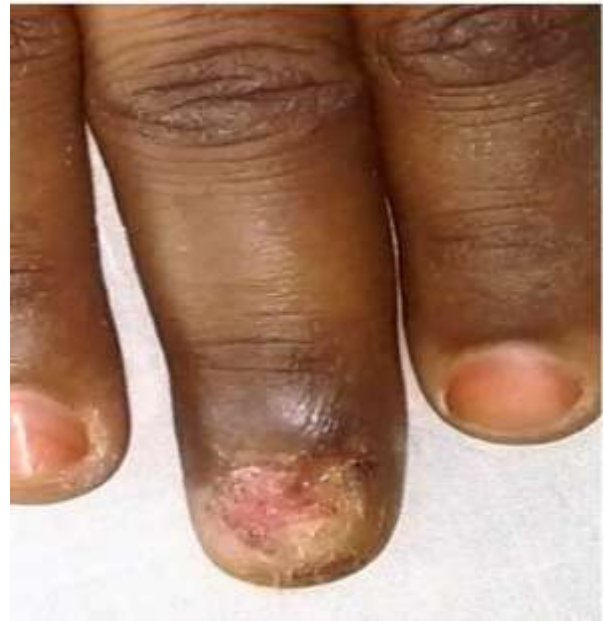

Figure 6

OWAISI HOSPITAL & RESEARCH CENTRE	
1050 BEDED MULTI SUPER SPECIALITY HOSPITAL WITH AFFORDABLE CHARGES D.M.R.L.X Road, Santosh Nagar, Kanchanbagh, Hyderabad - 500 058, T.S. INDIA Tel : 24343129, 24340889, 24341737, 24340244, Administrator - Ext : 356, RMO Ext. : 333 DECCAN COLLEGE OF MEDICAL SCIENCES	
DEPARTMENT OF PATHOLOGY INVESTIGATION REPORT	
PATIENT NAME: Sandhya	Date: 11/11/18
AGE: 35	Sex: (M / F) F
T.P. / O.P. NO: 009579	BILL No.:
NAME OF THE INVESTIGATION:	LAB No.:
HPE / 1997/18	
Spec: Received 2 soft tissue bits att together mfs 1x0.5cm G/W to Grey brown in color.	
Microscopic features:- Multiple sections studied reveal proliferating reticular mesh work, trabeculae & nests of polygonal to spindle cells with round hyperchromatic nuclei, moderate eosinophilic cytoplasm, inconspicuous nucleolar & cellular borders along with herringbone pattern of small enlarged vascular channels besides hyalinizing fibrocollagenous tissue architecture.	
Imp: Suggestive of benign small vascular neoplasia - Glomus tumor	
Adv: Immunohistochemistry with SMA, NSE, NF, CO34, for further evaluation as clinical correlation / follow up	
Signature: <i>[Signature]</i> Head of the Department	

Figure 7

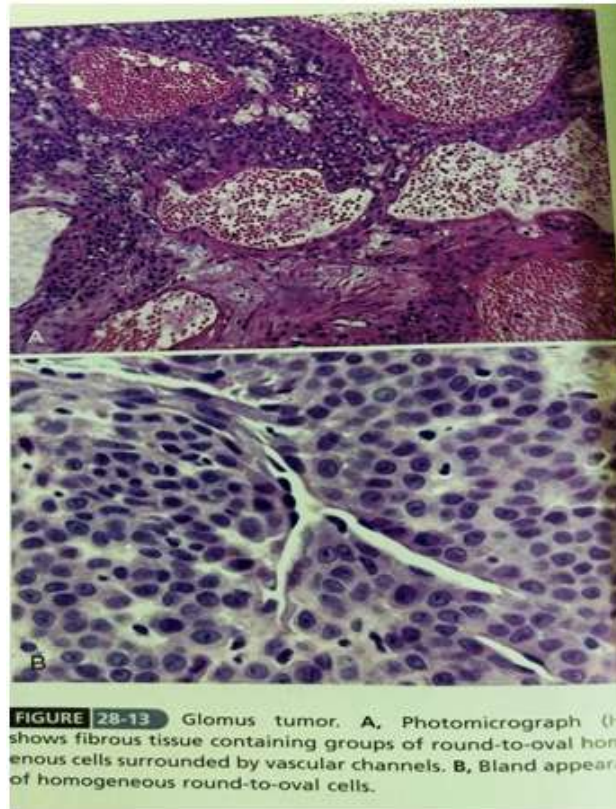


Figure 8

Typical histological features of glomus tumor included well-circumscribed subcutaneous or soft tissue tumor nodules in a prominent perivascular distribution composed of small, uniform round cells with round to oval nuclei (Figure 7, 8, 9).

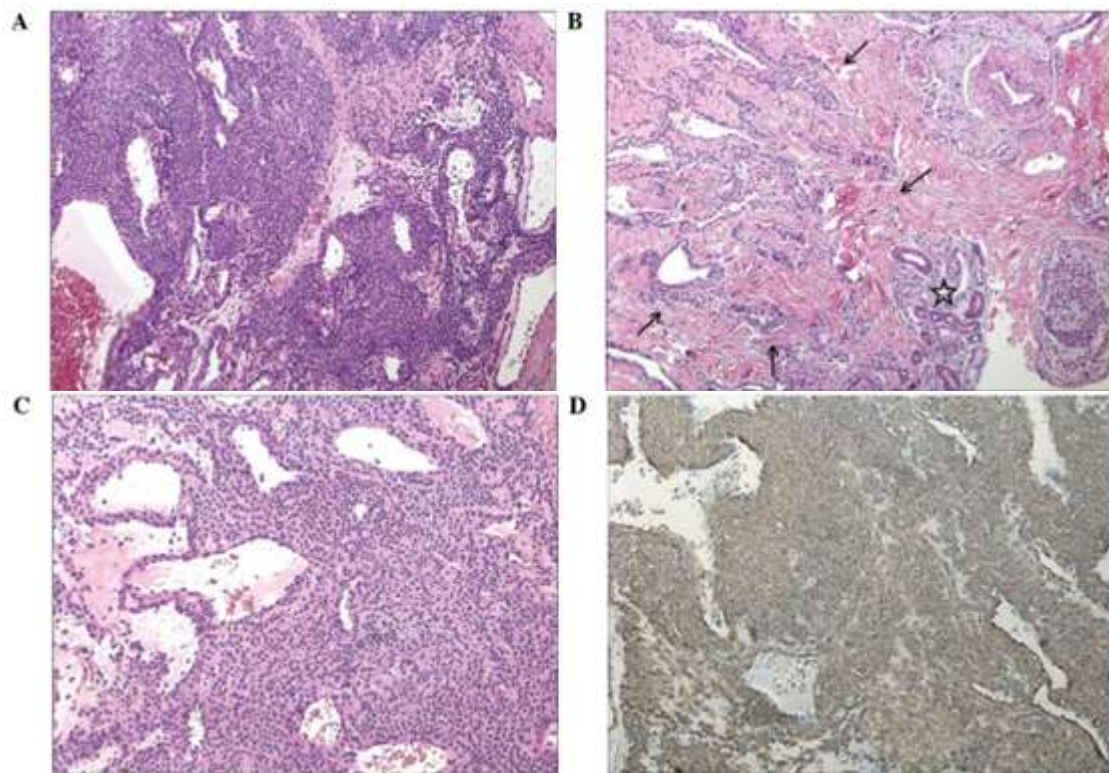


Figure 9

4. Discussion

The presence of glomus tumors in sites other than the hand makes an early and accurate diagnosis difficult. However,

following the correct diagnosis, the treatment involves complete surgical excision (7). Diagnosis of a glomus tumor is primarily clinical as imaging techniques, such as plain radiography, magnetic resonance imaging, ultrasonography

and angiography, do not yield a specific image of the tumor as they may only show the precise location and size of the tumor (8).

Beaton *et al* (9) suggested that the frequency of extradigital cases varied from 11 to 65% and may be more common in males than females. Lee *et al* demonstrated that extradigital glomus tumors are more common in males, whereas digital tumors are more frequent in females (2). The most prominent sites of extradigital glomus tumors have been reported to be the hands, followed by the feet and forearms (10). Other atypical locations where glomus tumors occurred and were excised include the lower lip (11), mediastinum (12), shoulder (13) and upper back (13). Folpet *et al* (14) examined 52 atypical glomus tumors located on thigh, calf and ankle, foot, buttock, trunk and abdomen, arm, lung, stomach and L3 vertebra.

Symptoms of glomus tumors are typical and often out of proportion to the size of the neoplasm. Paroxysms of pain radiating away from the lesion are the most common complaint (3). These episodes may be elicited by changes in temperature, particularly by exposure to the cold, and tactile stimulation even to a minor degree (3). The mechanism of pain production requires further elucidation, however, identification of nerve fibers containing immunoreactive substance P (SP) in glomus tumors suggests pain mediation through the release of this substance (3). SP is a pain-related peptide that acts as the main afferent pain transmitter in glomus tumors (15,16). McKamy suggested that thermosensitive afferents express ion channels of the transient receptor potential (TRP) family, which respond at distinct temperature thresholds, thus establishing a molecular basis for thermosensation (17). TRPV1 is a capsaicin receptor that acts through the release of SP. Furthermore, SP and TRPV1 correlate closely, although the exact association remains unclear (2).

Accurate diagnosis followed by complete excision is regarded as curative for patients with solitary lesions, and recurrence rates for solitary tumors have been found to range from 12 to 33% (18,19). It is rare for malignant glomus tumors to occur. Refined criteria have been suggested to define malignant lesions (14), including deep location and a size of >2 cm, or atypical mitotic figures, or moderate to high nuclear grade and ≥ 5 mitotic figures per 50 high-power field (14). Lesions with marked nuclear atypia but no other malignant features are termed symplastic. Glomus tumors of uncertain malignant potential are defined as lesions that lack criteria for the diagnosis of malignant or symptomatic glomus tumors but have high mitotic activity and superficial location, large size only or deep location only (14).

In conclusion, we reported the case of an extradigital glomus tumor arising in the subcutaneous tissue of the elbow. Unusual tumor sites and differing clinical symptoms occasionally interfere with the diagnosis and treatment of patients with extradigital tumors. Therefore, it is important to include the glomus tumor in the differential diagnosis of patients with extradigital painful or asymptomatic lesions that are purple in color.

References

- [1] Rath KR, Jena J, Dash BM, Mitra D, Patnaik PK, Basu AR. Extradigital glomus tumor as a cause of chronic perianal pain. *Indian J Pathol Microbiol.* 2009;52:414–416. [PubMed]
- [2] Lee DW, Yang JH, Chang S, Won CH, Lee MW, Choi JH, Moon KC. Clinical and pathological characteristics of extradigital and digital glomus tumors: a retrospective comparative study. *J Eur Acad Dermatol Venereol.* 2011;25:1392–1397. [PubMed]
- [3] Weiss SW, Goldblum JR, editors. *Enzinger and Weiss's Soft tissue tumors.* 5th edition. Mosby; Maryland Heights, MO: 2007. Perivascular tumors; pp. 751–756.
- [4] Masson P. Le glomus neuromyoarterial des regions tactile et ses tumors. *Lyon Chir.* 1924;21:257.
- [5] Kale SS, Rao VK, Bentz ML. Glomus tumor of the index finger. *J Craniofac Surg.* 2006;17:801–804. [PubMed]
- [6] Enzinger FM, Weiss SW, editors. *Enzinger and Weiss's Soft tissue tumors.* 4th edition. Mosby; Maryland Heights, MO: 2001. Perivascular tumors; pp. 985–1035.
- [7] Tomak Y, Dabak N, Ozcan H. Extradigital glomus tumor of the triceps tendon as a cause of elbow pain: a case report. *J Shoulder Elbow Surg.* 2003;12:401–402. [PubMed]
- [8] González-Llanos F, López-Barea F, Isla A, Fernández-Prieto A, Zubillaga A, Alvarez F. Periosteal glomus tumor of the femur; a case report. *Clin Orthop Relat Res.* 2000;380:199–203. [PubMed]
- [9] Beaton LI, Davis L. Glomus tumor: report of three cases and analysis of 271 recorded cases. *Q Bull Northwest Univ Med School.* 1941;15:245–273.
- [10] Calonje E. *Lever's Histopathology of the Skin.* 10th edition. Lippincott Williams and Wilkins; Philadelphia, PA: 2009. Vascular tumors: tumors and tumor-like conditions of blood vessels and lymphatics; pp. 1047–1049.
- [11] Lanza A, Moscariello A, Villani R, Colella G. Glomus tumor of the lower lip. A case report. *Minerva Stomatol.* 2005;54:687–690. [PubMed]
- [12] Gaertner EM, Steinberg DM, Huber M, Hayashi T, Tsuda N, Askin FB, et al. Pulmonary and mediastinal glomus tumors - Report of five cases including a pulmonary glomangiosarcoma: a clinicopathologic study with literature review. *Am J Surg Pathol.* 2000;24:1105–1114. [PubMed]
- [13] Takei TR, Nalebuff EA. Extradigital glomus tumour. *J Hand Surg Br.* 1995;20:409–412. [PubMed]
- [14] Folpe AL, Fanburg-Smith JC, Miettinen M, Weiss SW. Atypical and malignant glomus tumors: analysis of 52 cases, with a proposal for the reclassification of glomus tumors. *Am J Surg Pathol.* 2001;25:1–12. [PubMed]
- [15] Kishimoto S, Nagatani H, Miyashita A, Kobayashi K. Immunohistochemical demonstration of substance P-containing nerve fibres in glomus tumors. *Br J Dermatol.* 1985;113:213–218. [PubMed]
- [16] Wu JS, Huang ZJ, Zhou JF, Lin M, Fang MR, Pang ZJ, Yan HD. Expression and significance of substance P, neurofilament-H in glomus tumors with chronic pain. *Zhonghua Wai Ke Za Zhi.* 2003;41:935–939. (In Chinese) [PubMed]

- [17] McKemy DD. How cold is it? TRPM8 and TRPA1 in the molecular logic of cold sensation. *Mole Pain*. 2005;1:16. [PMC free article] [PubMed]
- [18] Rettig AC, Strickland JW. Glomus tumor of the digits. *J Hand Surg Am*. 1977;2:261–5. [PubMed]
- [19] Strahan J, Bailie HW. Glomus tumour. A review of 15 clinical cases. *Br J Surg*. 1972;59:91–3.[PubMed]