

Study of Subchronic Effect of *Myristicafragrans* Houtt. On Histopathology of Testes of Swiss Albino Mice

Rupali Vaity

Assistant Professor, Department of Zoology, SIES College of Arts, Science & Commerce, Mumbai, India

Abstract: Plants and plant materials are consumed as condiments and spices, which not only enhance the flavors of food but also show preservative and medicinal properties. The spice Nutmeg- *Myristicafragrans*Houtt.has several medicinal properties. However it may prove to be toxic if consumed in larger quantities over a longer time period. Hence present paper aims at studying the sub-chronic effect of aqueous and methanolic extracts of Nutmeg on histopathology of testes of Swiss Albino Mice. Marked degenerative changes in the seminiferous tubules were observed in the sections of testis treated with both aqueous and methanolic extracts of Nutmeg

Keywords: *Myristicafragrans*Houtt.,Subchronic effect, Histopathology, Swiss Albino Mice

1. Introduction

Nature has gifted human population with wide range of plant resources. Most of these plant resources have medicinal values and hence play key role in human health care. World Health Organization (WHO) survey indicated that about 70-80% of the world's population rely on non-conventional medicine, mainly of herbal source in their primary health care (1).

Some of these plants and plant materials are consumed as condiments and spices, which not only enhance the flavors of food but also show preservative and medicinal properties. Traditionally, there is a myth that herbs have been considered to be nontoxic and even harmless, mainly because of their natural origin. Though medicinal plant are nontoxic, it may prove to be toxic if consumed in large quantities or in an inappropriate portion. Nutmeg seeds - *Myristicafragrans*Houttis used for various medicinal properties. The fruit, leaves and seed extract show various activities like hepatoprotective activity (2), antioxidant activity (3), memory enhancing activity (4), anticancer activity (5), antidiabetic activity, hypolipidaemic activity (6), antibacterial activity (7), and anti-inflammatory activity (8). Even though *Myristicafragrans* is an excellent source of medicinally active compounds and has diverse pharmacological effects, its consumption as a house hold remedy is not regulated. Since it is a potent aphrodisiac (9) it is consumed by males in larger doses and that too for a longer time span. The amount of nutmeg given to children to induce sleep or as an anti diarrhoeal agent (10) is never fixed or standardized. Hence present study aims at investigating the subchronic effect of aqueous and methanolic extracts of nutmeg on histopathology of testis of Swiss Albino Mice.

2. Materials and Methods

Preparation of plant extracts: Nutmeg seeds were procured from local market in Mumbai. Both Aqueous and Methanolic extracts of nutmeg were prepared by maceration technique (11, 12).

Animals: The animals used in the study, Swiss Albino mice *Musmusculusalbinus*(20-30g), were purchased from the Haffkins Institute, and maintained in the Animal house of RamnaraianRuia College, Matunga, Mumbai. The animals were housed in groups of 5 in stainless steel cages (34×47×18 cm) with soft wood shavings as bedding, fed with normal commercial pellet diet (Lipton), given water *ad libitum*. All the experimental procedures and protocols used in this study were reviewed and approved by the Institutional Animal Care and Use Committee of RamnaraianRuia College, Matunga, India.

Experimental design

The study was conducted on 20 animals as per the Guidelines No. 407 of OECD (13).The animals were divided into 4 groups. The animals were feed by oral gavage. The aqueous control groups were feed with 1mL of distilled water, whereas aqueous treated groups were feed with 1000mg/kg body weight of Aqueous extract of nutmeg. The methanol control groups were feed with 1 mL of olive oil whereas the methanol experimental groups were feed with 200 mg/kg body weight of Methanolic extract of nutmeg. The animals were grouped as follows:

Group I- Aqueous Control Male (ACM),
Group II-Aqueous Treated Male (ATM)
Group III- Methanol Control Male (MCF),
Group VI- Methanol Treated Male (MTM)

The animals were feed with the respective extracts for 28thdays. On 29th day of the study, the animals were sacrificed by using high dose of ether anaesthesia, they were dissected open and the testes were harvested for histopathology study.

3. Results

Histological examination of testis of control group, both aqueous control and methanolic control revealed normal cyto-architecture. Seminiferous tubules were closely arranged with filled lumen. The epithelial layers in seminiferous tubules were highly organized including

different stages of germ cells. Figure A and B illustrate the histological sections of testis of control groups.

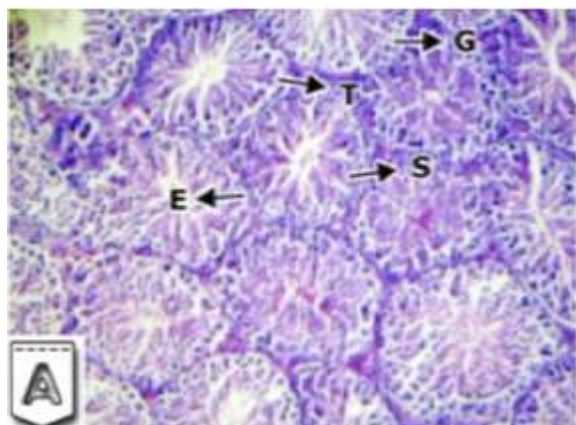


Figure A: Illustrating histology of testis of ANE control group treated with distilled water for 28 days. The section shows compactly arranged seminiferous tubules, with filled lumen (T), organized epithelium (E) and different stages of germ cells – spermatids (G), Sertoli cells (S). H & E Stain

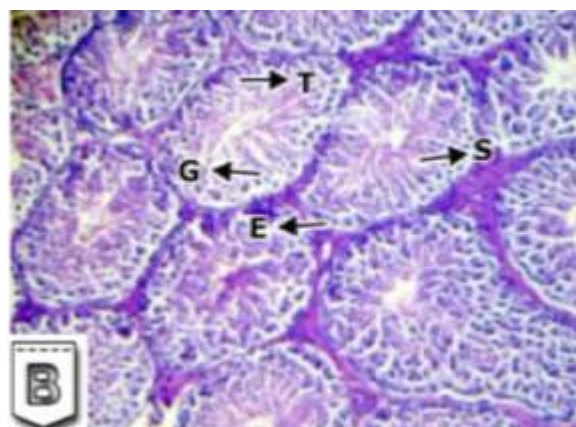


Figure B: Illustrating histology of testis of MNE control group treated with olive oil for 28 days. The section shows compactly arranged seminiferous tubules, with filled lumen (T), organized epithelium (E) and different stages of germ cells – spermatids (G), Sertoli cells (S). H & E Stain

However marked degenerative changes of seminiferous tubules were observed in the sections of testes treated with aqueous and methanolic extracts of nutmeg. Histological section of testis treated with 1000mg/kg body weight of aqueous extract revealed disorganization and vacuolation of seminiferous epithelium. The germinal epithelium of affected tubules were disrupted, there was disturbance of spermatogenic layers in many tubules. The Sertoli cells were scattered and atrophied. Sloughing in the epithelial layer was also observed and the germ cells were shed into the lumina. The tubular diameter was reduced and interstitial space was increased and degenerated. Figure C illustrates the histology of testis of Aqueous extract treated group.

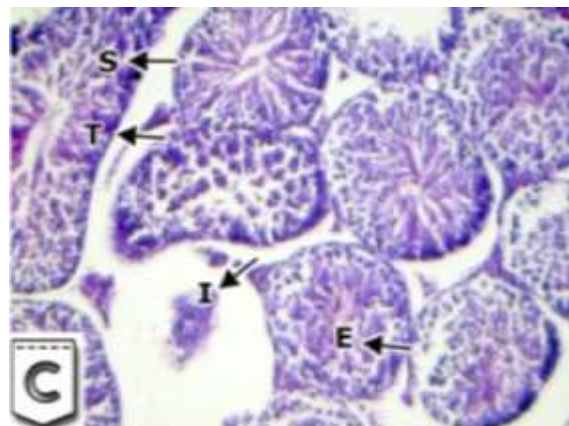


Figure C: Illustrating histology of testis of Aqueous extract treated animals for 28 days. The section reveals disorganized seminiferous epithelium (T), vacuolations (Black arrow), sloughing of germinal epithelial layer (E), atrophied Sertoli cells (S) and increased interstitial space (I). H & E Stain.

Histological section of testis treated with 200 mg/kg body weight of methanolic extract revealed that the germinal epithelium of affected tubules appeared disorganized, disrupted and showed shedding of germ cells into the lumina. A reduced volume of mature spermatozoa was noticeable and there was increase in the luminal space. There was loss of cell cohesion and exfoliation of cells in others. Wide gaps in between the spermatogenic cells were also observed. Figure D illustrates the histology of testis of methanolic extract treated group.

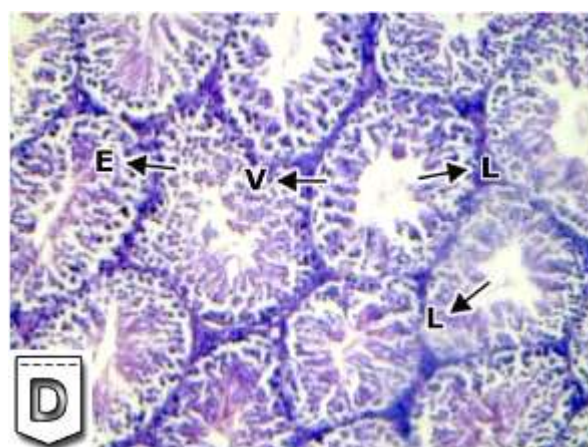


Figure D: Illustrating histology of testis of MNE treated animals for 28 days. The section reveals vacuolations (V), sloughing of germinal epithelial layer into the lumina (E), Increased luminal space (L) H & E Stain.

4. Discussion

There is wide acceptance of plants to be used as agents in aiding fertility in folklore medicines. Plants that could be used as contraceptives, emmenagogues and abortifacients have been recorded by the medical historians. As far as the safety of the herbal drugs are concerned, the population feels more assured may be due to their widespread usage and their familiarity with plants. However the safety of many of these herbal drugs is only relative. Several plants are reported to enhance reproductive processes but, on the other hand, they also hinder testicular functions.

Due to the antispermatogenic and/or antisteroidogenic properties of one or more active ingredients of the plants, several commonly used plants have been reported to adversely affect male reproductive functions in wildlife and humans.

Study revealed that 50% ethanolic extracts of Nutmeg and Clove can significantly enhance male sexual activity in animal models like mice. It was observed that the sexual behaviour of male mice with Nutmeg was greater than Clove. The study also revealed that the 50% ethanolic extracts of these drugs were devoid of any general conspicuous short term toxicity. Nutmeg and Clove are considered to be nervous stimulant, hence the action of these drugs as sexual invigorators may be due to their nervine stimulating property. Moreover it is also reported that the enhanced sexual behavior of mice after the treatment of nutmeg extract in comparison to clove extract can be attributed to the fact that nutmeg is known to increase blood circulation in the body. The study suggested short term use of this drug can be apparently safe.(9)

Hence present investigation aimed at studying the toxic effect of aqueous and methanolic nutmeg extracts on histopathology of testes of Swiss Albino Mice.

Present study demonstrated testes with normal general architecture with numerous seminiferous tubules with spermatogenic series at different levels of maturation in animals of control groups. However when animals were treated with aqueous extract of nutmeg, it was observed that there was disorganization and vacuolation of seminiferous epithelium. The germinal epithelium of affected tubules were disrupted, there was disturbance of spermatogenic layers in many tubules. The sertoli cells were scattered and atrophied. Sloughing in the epithelial layer was also observed and the germ cells were shed into the lumina. The tubular diameter was reduced and interstitial space was increased and degenerated. Histological section of testis treated with methanolic extract of nutmeg revealed that the germinal epithelium of affected tubules appeared disorganized, disrupted and showed shedding of germ cells into the lumina. A reduced volume of mature spermatozoa was noticeable and there was increase in the luminal space. There was loss of cell cohesion and exfoliation of cells in others. Wide gaps in between the spermatogenic cells were also observed. The damage to the seminiferous tubules of the testes treated with methanolic extract was almost same as that of animals treated with aqueous extract.

In the study of effect of methanolic extract of *Sphenocentrumjollyanum* root on albino rats, increase in the serum level of testosterone at a low dose was reported, indicating its use in traditional medicine as an aphrodisiac agent. However at higher concentrations of 100mg/kg of body weight and 150mg/kg of body weight, the methanolic extract showed testicular degeneration. The toxic effect of *Sphenocentrumjollyanum* some aspects of male reproduction might be attributed to isoquinoline, which is one of the alkaloid present in the plant extract (14).

The study on inhibitory effect of crude garlic on adult male mice indicated dose dependent increase in the percentage of

empty seminiferous tubules. It was reported that crude garlic consumption affects testicular function and altered spermatogenesis (15). The histopathological abnormalities may be due to long term consumption of crude garlic at higher concentration (16).

When rats were treated with garlic fraction precipitated with ethanol, the seminiferous tubules deprived of spermatozoa were observed (17). In addition the authors stated that the garlic fraction induced apoptosis in germ cells and decreased seminiferous tubules DNA concentration. The reason for this finding was attributed to the product (ethanol) used for making extract (16).

The rhizome extract of *Curcuma longa* at a dose of 600 mg per kg body weight for 56 and 84days caused a reduction in the diameter of seminiferoustubules, loosening of the germinal epithelium, intraperitonealvacuolation and mixing of spermatids at different stages of spermatogenesis in male Wistar rats, with the effects being reversible following cessation of treatment for 56 days (18).

Histopathological changes observed in our study may be attributed to the long term consumption of the extracts. As mentioned by Chris (16), the changes might also be to some extent due the solvent used in the extract that is methanol. However when the extract was prepared care was taken that the methanol used in extract preparation was totally evaporated and there were no traces of methanol in the extract. Even if methanol could have been the contributory factor in bringing about histopathological changes in testes the study was carried out using aqueous extract of nutmeg which gave almost similar results, indicating that solvent (methanol) used for extraction may not be absolutely responsible for bringing about histological changes in the testes.

The phytochemical screening of the extracts indicated the presence of alkaloids, phenols, tannins, flavonoids, glycosides, steroids, saponins in both the extracts. Any one of these phytochemical components or their combinations may be responsible to bring about degenerative changes in the testes. Most of the time the alkaloids have been implicated in abnormal sperm morphology even in human adults (19). Quassin, the bioactive component of *Quassiaamara* plant has been reported to decrease sperm count, sperm motility, normal sperm morphology, and male fertility index. Hence we can claim that the phytochemicals present in the extracts may be responsible for degenerative changes in testes (20).

The exact mechanism by which the degenerative changes are brought about due to aqueous and methanolic extract is beyond the scope of our research work however based on the study of other plant extracts in previous research work it is indicated that aqueous and methanolic extracts of nutmeg might be responsible for apoptosis of the cells in the seminiferous tubules.

5. Conclusion

Nutmeg is considered to be a very good spice with respect to its flavoring capacity and medicinal properties. However it

is suggested that long term consumption of nutmeg in larger doses may cause toxic effect on various physiological processes. The toxic effect of nutmeg can be attributed to the phytochemicals that are present in the extract.

References

- [1] Chan, K.2003. Some aspects of toxic contaminants in herbal medicines. *Chemosphere*, 52: 1361-1371.
- [2] Tatsuya Morita, KeikaJinno, HirokazuKawagishi, Yasushi Arimoto, Hiroyuki Suganuma,TakahiroInakuma, Kimio Sugiyama.2003. Hepatoprotective effect of Myristicin from Nutmeg (*Myristicafragrans*) on lipopolysaccharide/D-Galactosamine-induced liverinjury. *J. Agric. Food Chem.*, 51, 1560-1565.
- [3] M.T. Olaleye, Afolabi C. Akinmoladun and A.A.Akindahunsi. 2006. Antioxidant properties of *Myristicafragrans*(Houtt) and its effect on selected organs of albino rats. *African Journal of Biotechnology*, Vol. 5 (13), pp. 1274-1278.
- [4] Jissa, G.,Sai-Sailesh, K., and Mukkadan, J. K. 2014. Oral administration of Nutmeg on memory boosting and regaining in Wistar Albino Rats.*Bali Medical Journal*, Volume 3, Number 1: 3-10.
- [5] EktaPrakash, Dwijendra.K.Gupta. 2013. Cytotoxic activity of ethanolic extract of *MyristicaFragrans* (Houtt) against seven human cancer cell lines.*Universal Journal of Food and Nutrition Science* 1(1): 1-3.
- [6] D.K. Arulmozhi, R. Kurian, A. Veeranjaneyulu& S.L. Bodhankar. 2007. Antidiabetic and antihyperlipidemic effects of *Myristicafragrans*.in animal models. *Pharmaceutical Biology*, Vol. 45, No. 1, pp. 64–68.
- [7] SarifahNurjanah, Indira LantiPutri, and DwiPrettiSugiarti. 2017. Antibacterial activity of Nutmeg oil. *ICSAFS Conference Proceedings 2nd International Conference on Sustainable Agriculture and Food Security: A Comprehensive Approach*. Volume 2017.
- [8] Prerna Jain, V. Vishnu Priya, R. Gayathri. 2017. Anti-inflammatory activity of *Myristicafragrans*(Nutmeg) using HRBC membrane stabilising method. *Int. J. Pharm. Sci. Rev. Res.*, 44(1), Pages: 40-42.
- [9] Tajuddin, Shamsad Ahmad, Abdul Latif and Iqbal Ahmad Qasmi. 2003. Aphrodisiac activity of 50% ethanolic extracts of *Myristicafragrans*Houtt. (nutmeg) and *Syzygiumaromaticum*(L) Merr. & Perry. (clove) in male mice: a comparative study. *BMC Complementary and Alternative Medicine*, 3:6.
- [10] Prashant B. Shamkuwar, Deepak P. Pawar. 2012. Significance of nutmeg in diarrhea. *Der Pharmacia Lettre*,4 (6):1874-1877.
- [11]Mohammed Abdul Kareem1, Saayi Krushna Gadhamsetty, Althaf HussainShaik, E. Maruthi Prasad, Lakshmi Devi Kodidhela. 2013. Protective effect of nutmeg aqueous extract against experimentally-induced hepatotoxicity and oxidative stress in rats. *Journal of Ayurveda & Integrative Medicine*, Vol 4 Issue 4.
- [12]Monik Thakur, AnuragPaul,SnigdhaChawla. 2014. Qualitative phytochemical screening, total phenolic content and antioxidant activity in methanolic extracts of *Myristicafragrans*Houtt. (Mace). *Food Science Research Journal*, Volume 5 Issue 2 135-138.
- [13]<https://ntp.niehs.nih.gov/iccvm/suppdocs/fedddocs/oced/ocedtg407-2008.pdf>
- [14]YinusaRaji, Olayemi O. Fadare, Rahmat A., Adisa and Shakiru A Salami. 2006. Comprehensive assessment of the effect of *Sphenocentrumjollyanum* root extract on male reproductive activity in albino rats. *Reproductive Medicine and Biology*, 5: 283–292.
- [15]ImenHammami, AfefNahdi, Claire Mauduit, Mohamed Benahmed, Mohamed Amri, Awatef Ben Amar SemyZekri, Ahmed El May, Michele Veronique El May. 2008. The inhibitory effects on adult male reproductive functions of crude garlic (*Allium sativum*) feeding. *Asian Journal of Andrology Banner*, Volume 10 Issue 4.
- [16]Chris-ozoko L.E, NaihoA.O ,Okeke Faith. 2016. Histological effect of aqueous Garlic (*Allium Sativum*) extract on the testis and ovary of an adult wistar rat. *IOSR Journal of Dental and Medical Science*, Volume 15, Issue 1 Ver. IV PP 38-45.
- [17]Hammami, ImenNahdi, AfefKouidhi, WidedAtig, FatmaAmri, Mohamed Mokni, MeherziaZammeli, Zakia;El May, Ahmed, El May, Michele.2013. Effects of garlic fractions consumption on male reproductive functions..*Journal of medicinal food*,2011.0335.
- [18]Mishra R K, Singh SK. 2009. Reversible antifertility effect of aqueous rhizome extract of *Curcuma longa* L. in male laboratory mice. *Contraception*, 79(6):479-87.
- [19]D. E. Ejebe, J. O. T. Emudainohwo, R. Akonoghre, C. C. Olise , C. N. Amadi, I. M. Siminialayi, I. Onyesom, S. I. Ovuakporaye, and A. E. Ojieh. 2008. Effects of Ethanol Extract of Leaves of *Helianthus Annuus* on the Reproductive System of Male Wistar Rats: Testicular Histology, Epididymal Sperm Properties and Blood Levels of Reproductive Hormones. *Biomedical and Pharmacology Journal*,1(1).
- [20]Obembe O., Raji Y. 2017. Morphometric variables of offspring of *Quassiaamara* treated male rats. *Res. J. of Health Sci*, Vol 5 (2).