

# Spectrum of Lesions in Lower Gastro-Intestinal Tract Mucosal Biopsies with Endoscopic and Clinical Correlation

Dr. Himanshu Joshi<sup>1</sup>, Dr. Rashmi Chauhan<sup>2</sup>, Dr. Ashutosh Kumar<sup>3</sup>, Dr. Shyamoli Dutta<sup>4</sup>

<sup>1,2</sup>Assistant Professor, Department Of Pathology, Teerthanker Mahaveer Medical College, Moradabad

<sup>3</sup>Associate Professor, Department Of Pathology, Teerthanker Mahaveer Medical College, Moradabad

<sup>4</sup>Professor and HOD, Department Of Pathology, Teerthanker Mahaveer Medical College, Moradabad

**Abstract:** *Introduction:* Endoscopy of the gastro intestinal tract is a simple safe and well tolerated procedure and in combination with biopsy plays an important role in the early diagnosis of whole GI tract neoplasms. This study was done to determine the histopathologic spectrum of Lower Gastrointestinal Tract (LGIT) Mucosal Biopsies. *Materials and Methods:* A retrospective study of lower GI endoscopic biopsy was carried out in our tertiary care hospital over a span of two year in which about 74 mucosal biopsies were evaluated by histopathological examination. *Result:* Of the 74 patients, 50 (67.6%) were male and 24 (32.4%) were female, giving a male to female ratio of 2.1:1. The 3 most common sites of biopsy were colon > rectum > multiple sites. Of the pathological lesions diagnosed, inflammatory lesions were the most common followed in order by polyps, IBD, malignancy and miscellaneous. 16.2% of biopsies showed normal histology. *Conclusion:* The combination of clinical data, endoscopy and histopathology allows for accurate classification of the lesions of lower gastro-intestinal tract in the majority of cases.

**Keywords:** Lower gastro-intestinal tract (LGIT), Colon rectal cancer (CRC)

## 1. Introduction

Globally, colorectal cancer is the 4th most common cancer after breast, prostate, and lung cancer, with an incidence rate of 9.8% and estimated 1.24 million new cases diagnosed in 2008.<sup>[1,2]</sup> Colorectal cancer alone accounts for the death of at least 609,051 persons yearly.<sup>[1]</sup> Worldwide, a total of 663,000 cases were diagnosed yearly in males, with an incidence rate of 10%, while in women, 571,000 cases were diagnosed, with an incidence rate of 9.4%.<sup>[1,2]</sup>

Regular bowel cancer screening has been shown to reduce the risk of dying from bowel cancer by as much as 16%. It has been shown that targeted prevention and early detection programs by use of endoscopy could help reverse the increasing trend of colorectal cancer in most developing countries.

Endoscopy as a diagnostic and therapeutic tool has grown in recent years. Lower GI endoscopy together with biopsy plays an important role in the early diagnosis of neoplasms and provides an opportunity for early treatment options as well as potential for possible cure. Endoscopic biopsy examination followed by histopathologic assessment is current gold standard for accurate objective assessment of patients. The objective of our study is retrospective analysis of the histopathologic diagnosis of lower gastrointestinal endoscopic biopsies.

## 2. Materials and Methods

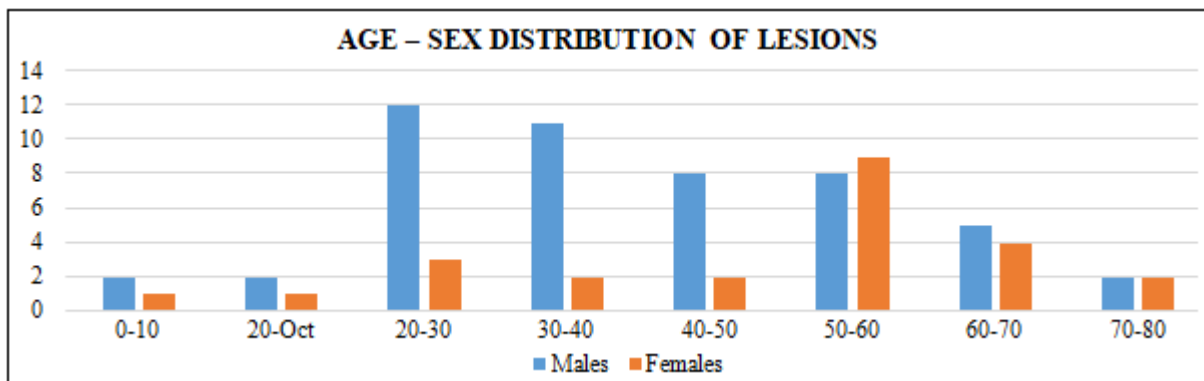
Present retrospective study was done to analyze the endoscopic biopsies from lower GI tract from patients

attending the department of gastroenterology at TeerthankerMahaveer Medical College and Research Centre (TMMC&RC), Moradabad from 1<sup>st</sup> Jan,2016 till 30<sup>th</sup> Nov,2017 . Total 74 cases of endoscopic mucosal biopsies were evaluated. Biopsy specimens were fixed in 10% buffered formal formalin, followed by automated tissue processing & embedded in paraffin. Serial sections, 3-5  $\mu$  thick were prepared and then stained with routine H & E stain. Additional sections were stained with Per-iodic Acid Schiff (PAS) stain, wherever necessary.

## 3. Results

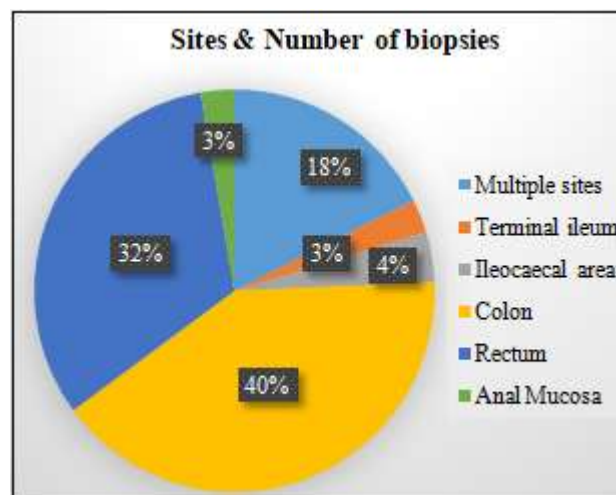
In our study, 74 LGE biopsy specimen records were retrospectively analyzed. On histological evaluation, 62 (83.8%) of the endoscopic biopsies had a pathologic diagnosis while 12 (16.2%) of them were normal colonic mucosa. Of the 74 patients, 50 (67.6%) were male and 24 (32.4%) were female, giving a male to female ratio of 2.1:1. The age ranged from 5 months to 78 years, with a mean of 41.5 years. The median age was 45 years.

Age Group	Males	Females	Total
0-10	2	1	3
20-Oct	2	1	3
20-30	12	3	15
30-40	11	2	13
40-50	8	2	10
50-60	8	9	17
60-70	5	4	9
70-80	2	2	4
<u>TOTAL</u>	50	24	74



The 3 most common sites of biopsy were in the following order colon > rectum > multiple sites, followed by ileocaecal area, with 2 biopsies each from terminal ileum and anal mucosa.

Site	Number Of Biopsies
Multiple Sites	13
Terminal Ileum	2
Ileocaecal Area	3
Colon	30
Rectum	24
Anal Mucosa	2
<b>Total</b>	<b>74</b>



Of the pathological lesions diagnosed, inflammatory lesions were the most common (27%) followed in order by polyps (20.2%), IBD (17.6%), malignancy (12.2%) and miscellaneous (6.8%). 16.2% of the biopsies showed normal histology.

Lesion	Number of Cases	Endoscopic Appearance
<b><u>Inflammatory Lesions</u></b>	<b>27%</b>	<b>Inflamed mucosa, multiple ulcers</b>
Chronic non-specific colitis/proctitis	11	
Focal active colitis	9	
<b><u>INFLAMMATORY BOWEL DISEASE</u></b>	<b>17.6%</b>	<b>Mucosal ulcerations, granularity and erosions, strictures</b>
Ulcerative Colitis	7	
Cohn's Disease	6	
<b><u>POLYPS</u></b>	<b>20.2%</b>	<b>Polypoidal growth, mucosal polyp</b>
Adenoma (tubulo villous)	1	
Adenomatous polyp	5	
Retention Polyp	5	
Hyperplastic polyp	1	
Inflammatory Polyp	3	
<b><u>MALIGNANCY</u></b>	<b>12.2%</b>	<b>Ulceroproliferative growth, friable growth +/- stricture across which scope couldn't be negotiated</b>
Colon Adenocarcinoma	3	
Rectum Adenocarcinoma	4	
Anal Mucosa Adenocarcinoma	1	
D3 - Suspicious For Adenocarcinoma	1	
<b><u>MISCELLANEOUS</u></b>	<b>5</b>	<b>6.8%</b>
<b><u>UNREMARKABLE/NORMAL HISTOLOGY</u></b>	<b>12</b>	<b>16.2%</b>
<b>TOTAL</b>	<b>74</b>	<b>100%</b>

Miscellaneous cases consisted of 1 case each of Hirschsprung disease, collagenous colitis with eosinophilic gastro-enterocolitis, early evolving collagenous colitis and 2

cases of perforation. Indication of colonoscopy varied from case to case and consisted of following signs and symptoms - abdominal pain, bleeding per rectum, constipation and

diarrhea. Some cases presented with abnormal tests reports such as abdominal mass on USG/CT/MRI, positive stool occult blood and suspicious findings on barium enema studies.

#### 4. Discussion

Sahu et al. in India had only 8.3% (32) cases of malignancy.<sup>[3]</sup>, which is quite close to our study's finding of 12.2%, this difference may be attributed to the difference in sample size of the two populations of study.

The male to female ratio of patients with colorectal and anal mucosa adenocarcinoma in our study is 1.3:1 and is in the same range as that seen by Abdulkareem et al., who had a male to female ratio of 1.35:1.<sup>[4]</sup> The male to female ratio in this study is similar to that seen in the Western world.<sup>[5]</sup>

The predominant type of colorectal cancer was the invasive adenocarcinoma which was also the predominant pattern seen in several other studies.<sup>[4,6,7]</sup>

The anatomical location of the adenocarcinoma in our study is rectum concurs to what was seen in both local and international studies done in Southwestern Nigeria, Benin City, Jos, Ilorin, Ghana, and Amsterdam, in which a majority of them were located in the rectum<sup>[4,6,8]</sup>

#### 5. Conclusion

Biopsy sampling of LGIT mucosa at diagnostic endoscopy provides useful information. A variety of non-neoplastic and neoplastic lesions were found in our study across a wide range of age and site distribution. We conclude that biopsy of lower gastrointestinal lesions helps in accurate assessment of mucosal lesions and diagnosis of the carcinomas at early stage leading to appropriate and early clinical management. Endoscopy is incomplete without biopsy and so the combination of methods together with clinical details provides a powerful diagnostic tool for better patient management.

#### References

- [1] Ferlay J, Shin HR, Bray F, Forman D, Mathers C, Parkin DM. GLOBOCAN 2008; Cancer Incidence and Mortality. Worldwide: IARC Cancer Base No. 10. Lyon, France: International Agency for Research on Cancer; 2010. Available from: <http://www.globocan.iarc.fr>. [Last accessed on 2012 May 08].
- [2] Cancer Research UK, Bowel (Colorectal) Cancer-UK IncidenceStatistics. Available from: <http://www.cancerresearchuk.org/health-professional/cancer-statistics/statistics-by-cancer-type/bowel-cancer/incidence#heading-Zero>, [Last accessed on 2012 Mar 05].
- [3] Sahu SK, Husain M, Sachan PK. Clinical spectrum and diagnostic yield of lower gastrointestinal endoscopy at a tertiary centre. *Internet J Surg* 2009;18:1-6.
- [4] Abdulkareem FB, Faduyile FA, Daramola AO, Rotimi O, Banjo AA, Elesha SO, et al. Malignant gastrointestinal

- tumours in South Western Nigeria: A histopathologic analysis of 713 cases. *West Afr J Med* 2009;28:173-6.
- [5] Cancer Research UK, Bowel (Colorectal) Cancer-UK IncidenceStatistics. Available from: <http://www.cancerresearchuk.org/health-professional/cancer-statistics/statistics-by-cancer-type/bowel-cancer/incidence#heading-Zero>, [Last accessed on 2012 Mar 05].
- [6] Abdulkareem FB, Abudu EK, Awolola NA, Elesha SO, Rotimi O, Akinde OR, et al. Colorectal carcinoma in Lagos and Sagamu, Southwest Nigeria: A histopathological review. *World J Gastroenterol* 2008;14:6531-5.
- [7] Eze GI, Igbe AP, Obaseki DE, Akhiwu WO, Aligbe JU, Akang EE, et al. Presentation of colorectal cancers in Benin city, Nigeria. *Sahel Med J* 2010;13:24-8.
- [8] Ibrahim KO, Anjorin AS, Afolayan AE, Badmos KB. Morphology of colorectal carcinoma among Nigerians: A 30-year review. *Niger J ClinPract* 2011;14:432-5.