

Adenosquamous Carcinoma of Gall Bladder: A Case Report

Irmeen Manzoor^{1*}, Meera Mahajan²

¹Senior Resident, Department of Pathology, MGM Medical College & Research Centre, Aurangabad, Maharashtra, India
drirmeenm[at]gmail.com

²Assistant Professor, Department of Pathology, MGM Medical College & Research Centre, Aurangabad, Maharashtra, India
meeramahajan12[at]gmail.com

Abstract: *Objective: Study Design: In this case report we present a male of age 30 years with complaints of pain in right hypochondriac region since 9 months and history of anorexia and weight loss. Diagnostic tools included were USG and CT scan which showed a mass in the right hypochondrium. Radical cholecystectomy was done. On gross examination, gall bladder was of size 8x6x5cm. On cut section it showed a tumor mass of size 6x2.5cm which was grayish-white in color. Tumor was firm in consistency and showed complete involvement of wall on one side of gall bladder. The microscopic examination from gall bladder along with tumor mass revealed round to polyhedral cells with hyperchromatic and pleomorphic nuclei. Cells were arranged in groups and sheets and at places showed glandular arrangement. Keratin pearls were also present. The tumor cells were seen invading the muscular wall of the gall bladder. Results: A final diagnosis of adenosquamous carcinoma of gall bladder.*

Keywords: Adenosquamous, carcinoma, gall bladder, squamous

1. Introduction

Carcinoma of gall bladder develops so insidiously that its presence is not often suspected until the growth is well established. Adenosquamous cell carcinoma of the gall bladder generally has been considered a lethal disease.(2)

2. Case Report

A 30 year old male presented with pain in right hypochondriac region since 9 months with history of anorexia and weight loss. USG and CT scan showed a mass in the right hypochondrium. Radical cholecystectomy was done.

3. Pathological Findings

Gross: Gall bladder was of size 8x6x5cms. On cutting open showed tumor mass of size 6x2.5cm. Tumor was grayish-white in color, firm in consistency and showed complete involvement of wall on one side of gall bladder.

Microscopy: Section from gall bladder along with tumor mass studied showed round to polyhedral cells with hyperchromatic and pleomorphic nuclei arranged in groups and sheets and at places showed glandular arrangement. Keratin pearls were also evident. There were large areas of necrosis. The tumor cells were seen invading the muscular wall of gall bladder.

4. Discussion

Adenosquamous cell carcinoma accounts for less than 3.5% of gall bladder carcinomas, and is characterized by invasive growth, a reduced tendency for lymph node metastasis, an increased tendency for hepatic infiltration or liver metastasis, and a poorer prognosis than adenocarcinoma. (3) Pain is probably the most common presenting symptom, jaundice, right upper-quadrant mass,

nausea; vomiting, anorexia and weight loss can also be present.

Adenosquamous cell carcinoma is composed of a mixture of glandular and squamous elements. The histological differentiation of both elements in these tumors tends to be of a moderate degree, rather than anaplastic or poorly differentiated. The squamous portion can be dominant requiring multiple sections to demonstrate glandular element. The pure type of squamous cell carcinoma often arises in association with squamous metaplasia. The tumor may arise from few areas of squamous metaplasia. Intraepithelial neoplasia can be found in the metaplastic squamous mucosa. Adenosquamous carcinoma of the gall bladder is relatively rare. Its biological behaviour and optimal surgical procedure are still controversial (5).

References

- [1] David J. B. Ashley, Evan's histological appearances of tumours, 4th edition, chapter 6, page 697.
- [2] Oohashi Y, Shirai Y, Wakai T, Nagakura S, Watanabe H, Hatakeyama K. Adenosquamous carcinoma of the gall bladder warrants resection only if curative resection is feasible. *Cancer*. 2002 Jun 1;94(11):3000-5.
- [3] Akcali, Ozyilkan O, Sakalli H, Bal N, Noyan T. Gall bladder adenosquamous cell carcinoma: report of two cases. *Acta Gastroenterol Belg*. 2005 Oct-Dec.
- [4] Christopher D.M. Fetcher 3rd edition, vol I, chapter 10, page 445.
- [5] Kondo M, Dono K, Sakon M, Shimizu J, Nagano H, Nakamori H, Umeshita K, Wakasa K, Monden M. *Hepatogastroenterology*. 2002 Sep-Oct;49(47):1230-4

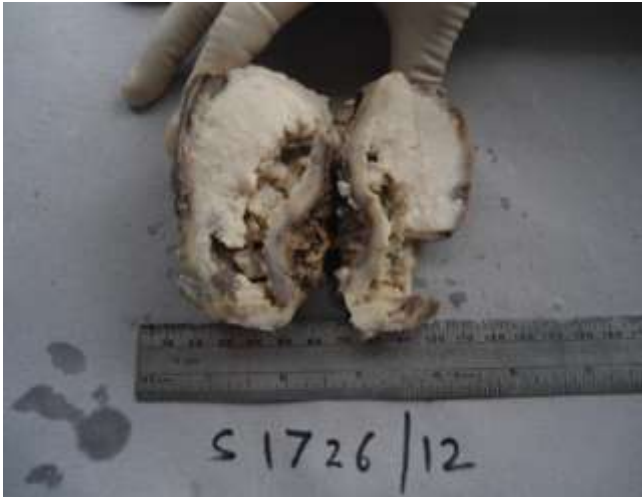

Figure 1: Specimen of Adenosquamous Carcinoma of Gall Bladder

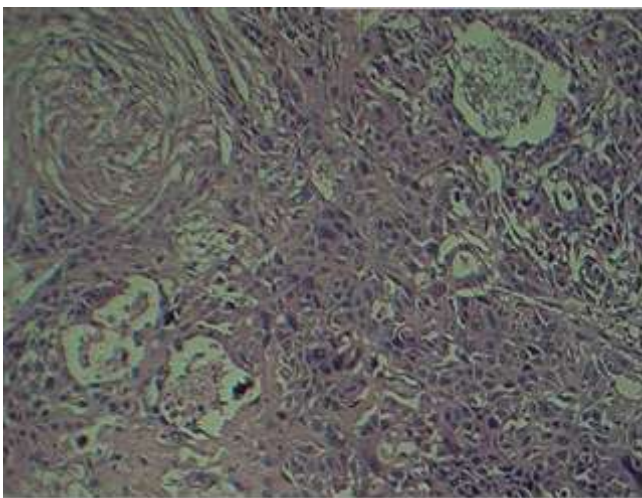


Figure 2: H & E x100. Microscopy: Presence of mixture of glandular and squamous elements

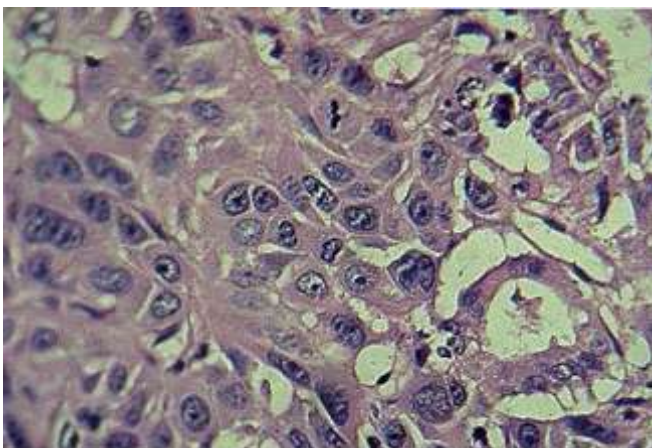


Figure 3: H & E x. Microscopy: Presence of cells with hyperchromatic pleomorphic nuclei