

Nasal Bone Reduction under Local Anesthesia: A Case Series

Dibin R¹, Sibi Joseph², Sreejith S³, Muhammad Ali T⁴

¹Senior Resident, Department of OMFS, Govt Dental College, Kottayam, Kerala. Pincode 686008

²Junior Resident, Department of OMFS, Govt Dental College, Kottayam, Kerala. Pincode 686008

³Junior Resident, Department of OMFS, Govt Dental College, Kottayam, Kerala. Pincode 686008

⁴Senior Resident, Department of OMFS, Govt Dental College, Kottayam, Kerala. Pincode 686008

Abstract: *The nasal bone is the most commonly fractured bone in the face. The initial assessment and evaluation of nasal injuries is very important factor as undiagnosed or untreated nasal injuries account for a high percentage of septoplasty or rhinoplasty procedures performed months to years after the initial trauma. Management of nasal bone fractures can be largely divided into open and closed reductions. Of the two, closed reduction under local anesthesia is the treatment of choice in most cases because of the relatively short operation time, minimal scars, tissue damage, and shorter recovery time. Reports from literature show that manipulation of the nasal bones under local anesthesia was acceptable to almost all patients and yielded cosmetic and functional results as good as manipulation under general anesthesia. This paper reports two cases of nasal bone fracture reduced under local anesthesia with good cosmetic results.*

Keywords: nasal bone fracture, nasociliary block, local anesthesia

1. Introduction

The nose is very susceptible to trauma and fractures due to its prominent position on the face, and 39% of all facial fractures are nasal fracture (1). The incidence of nasal fractures exhibits bimodal distribution; in young adults following assaults and sporting injuries and in the elderly following falls (2). Fracture is usually associated with the depression or displacement of nasal bones, edema of nose, epistaxis, crepitus on palpation, nasal obstruction symptoms and local pain. The purpose of correction of nasal fractures is often aesthetic or functional. The surgical treatment varies significantly according to the type of fracture associated, treatment plan and the type of anesthesia employed. Some authors recommend nasal fracture reduction under general anesthesia, although local anesthesia is also preferred mainly due to the technical ease and good results (3). Nasal fractures can be manipulated through the “closed” or “open” surgical procedure. An ‘open reduction’ involves a formal operative procedure with incisions and open manipulation of the nasal bones and septum(4) and the closed reduction is indicated in cases of unilateral and bilateral fractures with deviation less than half the depth of the nasal tip(5). Despite evidence for the benefit of local anesthesia (6), nasal fractures are still most commonly reduced under GA. Many factors contribute to this, including lack of familiarity with nasal LA and a lack of trained practitioners. Many surgeons also prefer GA because of the large forces needed for fracture reduction.

2. Case Report – 1 (Fig 1-3)

46year old male patient with history of road traffic accident reported at Casualty with epistaxis and abrasions over the face. No history of loss of consciousness, vomiting or seizures noted. Tenderness and deviation noted on the nasal

bone (fig 1). No septal hematoma present. CT Brain, Chest radiograph were taken to rule out head injury and other medical emergencies.

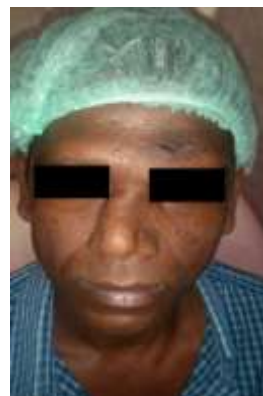

Figure 1: Pre Operative image showing fractured nasal bone

CT facial (Fig 2) bone showed bilateral nasal bone fracture. Procedure was delayed for four days in order to reduce edema and post-traumatic stress.

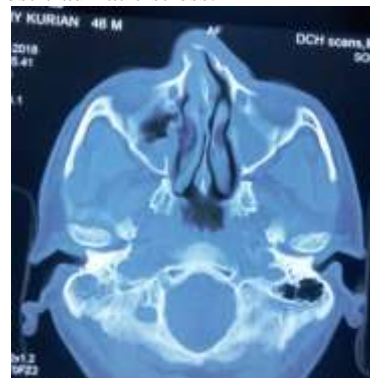


Figure 2: Axial CT showing bilateral nasal bone fracture

Anaesthesia of the region is achieved using

- 1) Two puffs of lignocaine + phenylephrine spray to each nostril and one cotton ball soaked is applied into each nostril
- 2) Bilateral infraorbital nerve block given with 2ml of 2% lignocaine with 1:1 lakh adrenaline
- 3) Bilateral nasociliary nerve block by injecting 1 mL of 2% lignocaine with 1:1 lakh adrenaline to half way between the medial canthus and the glabella on each side down to the periosteum. It is this nerve block that enables reduction under LA to be possible.

Reduction of nasal bone was done with digital manipulation (fig 3) and there was no post nasal bleeding or septal hematoma. Patient was well tolerant to the procedure and was kept on a regular follow up. There was no post reduction deformities noted in this patient on 3 months follow up.

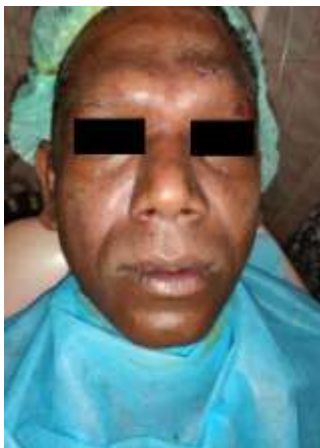

Figure 3: Post Operative image

3. Case report -2 (Fig 4-5)

48 year old male patient with an alleged history of fall from height, CT facial bone showed minimally displaced right nasal bone fracture(figure 4 and 5)

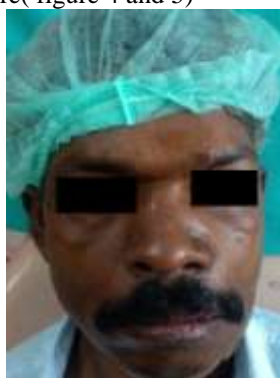

Figure 4: Pre Operative image showing right nasal bone fracture

Closed reduction was done with digital manipulation under local anesthesia (fig 6). Patient was put on 3 months follow up



Figure 5: Axial CT scan showing fractured nasal bone

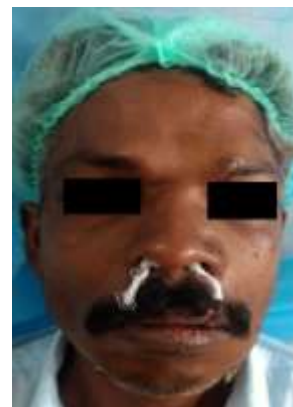

Figure 6: Post Operative image

4. Discussion

Nasal bone fractures are the most common among facial fractures, and reduction of these fractures are delayed until the edema has subsided. Delaying nasal fracture reduction for at least 3 days after the traumatic event could be beneficial due to less pain and less bleeding. It is believed that this finding is due to the fact that patients are under less stress 3 days following the traumatic event, in addition to the partial recovery of edema and ecchymosis. In general, pain in the procedure was well tolerated with a low rate on a VAS. In cases of nasal bone fractures, there are 3 major aspects to consider to insure the best treatment: the timing of treatment, the choice of anesthetic (local or general), and surgical technique (open or closed reduction). Murray and Maran, in a prospective study of 756 patients treated by closed reduction, found that 59% had no residual nasal deformity (7) However, Rajapakse et al fared better, averaging functional and aesthetic satisfaction in 86% and 84% of patients after closed reduction with both general and local anesthesia, respectively. They concluded that from the point of view of the patient, both types of anesthesia are acceptable. In this study, 69% of patients accepted the procedure under local anesthesia (4). Waldron et al found acceptance of this type of anesthesia in 92% of patients (8). In 1988, Watson et al [9], in a randomized, prospective, single blind study, compared the outcome of local and general anesthetic procedures in 40 patients with recent nasal fractures requiring manipulation. The results showed that manipulation of the nasal bones under local anesthesia was acceptable to almost all patients and yielded cosmetic and functional results as good as manipulation under general anesthesia. Moreover, this procedure offered the most

advantageous combination of safety, cost, and outcome. . The incidence of post reduction nasal deformities requiring subsequent rhinoplasty or septorhinoplasty ranges from 14% to 50% (10). All previous studies have shown that LA techniques are safe, effective and comparable to GA in manipulation of nasal bone fractures, but there was no evidence to support or refute the superiority of one technique over another. In addition to providing comparable efficacy to GA, LA offers more safety, lower cost, the use of fewer hospital resources and less time in the hospital.

Therefore, LA is appropriate for cooperative adults with simple nasal fractures that do not require open reduction of the septum. Certainly GA can also be used in such cases, but it's better to advice GA for non-cooperative or young patients, those with severely displaced fractures and those who require extensive septal work.

References

- [1] Illum P, Kristensen S, Jørgensen K, Brahe Pedersen C. Role offixation in the treatment of nasal fractures. *Clin Otolaryngol Allied Sci* 1983;8(3):191–195
- [2] Muraoka M, Nakai Y, Shimada K, Nakaki Y. Ten-year statistics and observation of facial bone fracture. *Acta Otolaryngol. Suppl.*1991; 486: 217–23.
- [3] Cook JA, McRae RD, Irving RM, Dowie LN. A randomized comparison of manipulation of the fractured nose under local and general anaesthesia. *Clin Otolaryngol Allied Sci* 1990;15(4): 343–346
- [4] Rajapakse Y, Courtney M, Bialostocki A, Duncan G, Morrissey G. Nasal fractures: a study comparing local and general anaesthesia techniques. *ANZ J Surg* 2003;73(6):396–399
- [5] Bailey BJ. *Head and Neck Surgery-Otolaryngology*. Vol. 1. Philadelphia: Lippincott; 2001
- [6] Watson DJ, Parker AJ, Slack RW, Griffiths MV. Local versus general anaesthetic in the management of the fractured nose. *Clin. Otolaryngol.* 1988; 13 (6): 491–4.
- [7] Murray JAM, Maran AGD. The treatment of nasal injuries by manipulation. *J Laryngol Otol* 1980;94(12):1405–1410
- [8] Waldron J, Mitchell DB, Ford G. Reduction of fractured nasal bones; local versus general anaesthesia. *Clin Otolaryngol Allied Sci* 1989;14(4):357–359
- [9] Watson DJ, Parker AJ, Slack RW, et al. Local versus general anaesthetic in the management of the fractured nose. *Clin Otolaryngol* 1988;13:491 - 4.
- [10] Rohrich RJ, Adams WP Jr. Nasal fracture management: minimizing secondary nasal deformities. *Plast Reconstr Surg* 2000;106:266–273.