

Comparative Study of Two Different Telescopic Crown Materials Retaining Lower Partial Overdenture

Ayman H. Amin¹, Gehan Fikry², Fardos N. Rizk³, Amr B. Ismail⁴

¹Assistant Lecturer British University in Egypt

²Professor Removable Prosthodontic department Minia University

³Vice Dean and Professor Removable Prosthodontic department British University in Egypt

⁴Assistant Professor Removable Prosthodontic department Minia University

Abstract: ***Purpose:** This study was conducted to measure the difference between Chrome Cobalt telescopic crowns and Poly ether ether ketone[PEEK] telescopic crowns retaining implant retained partial overdenture regarding implant stability, crestal bone height changes and periodontal pocket depths. **Materials and Methods:** This study was made on fourteen lower kennedy class I partially edentulous patients. All patients received posterior implant in the second molar area in each side. The patients were divided into 2 groups, the first group received chrome cobalt telescopic crown and the second group received poly ether ether ketone telescopic crowns over the implants. Partial overdenture was constructed for all the patients in the two groups. Patients were followed up clinically to measure crestal bone height changes using cone beam ct, implant stability test using osstell and periodontal pocket depths. **Results:** Both groups showed increase in implant stability, periodontal pocket depths and decrease in crestal bone height, however the difference between the two groups were non-significant except in the periodontal pocket depth, the chrome cobalt group showed increased pocket depths than the PEEK group. **Conclusions:** From the results of this study the, the following conclusions could be obtained. There was almost no difference in crestal bone height resorption between the CrCo and the PEEK telescopic crowns, the difference between implant stability in both groups were non-significant, at the end of the follow up period, the PEEK telescopic crown group showed lesser periodontal pocket depths than the CrCo group which suggests that the PEEK is more biocompatible than the metallic crowns.*

Keywords: Overdenture, Telescopic crowns, Implants, PEEK, chromecobalt

1. Introduction

Posterior free end saddle edentulous patients are the most prevalent among the population. The absence of posterior abutments may affect the support, retention and stability and consequently the prognosis of the prosthesis is affected. Loss of posterior teeth may result in loss of neuromuscular stability of the mandible, reduced masticatory efficiency, loss of vertical dimension of occlusion and attrition of the anterior teeth[1, 2].

Due to the great difference in the resiliency between the soft tissues and the teeth, the resultant forces will have a damaging effect on the remaining abutment teeth. In addition unfavorable movements will occur leading to compromised masticatory efficiency with subsequent patient dissatisfaction[3, 4].

The rehabilitation of partially edentulous patients with missing mandibular premolars and molars with implant supported overdentures showed successful results. In addition it was found that implants placed in the distal edentulous ridge prevent the displacement of the distal extension denture bases regardless the length of the supporting areas of the denture base[5].

Implant supported telescopic prosthesis is a reliable method of treatment of atrophied arches that ensures better

masticatory function, esthetics, oral hygiene in addition to improved retention and stability[6].

The placement of implants in partially edentulous patients to retain tooth-implant telescopic prosthesis proved to be a successful line of treatment with few technical and biological complications[7].

Metal-free restorations are becoming increasingly important in dentistry due to factors such as the increased aesthetic demands of the patient, legislation in some countries and possible material incompatibility[8].

Peek has been utilized in orthopedic surgeries, joint substitution, fixation devices and maxillofacial surgeries. In dentistry, Peek can be utilized in the construction of CAD/CAM removable and fixed prosthesis. It was proposed to be used as dental implants as well because of its high esthetic qualities and its low modulus of elasticity that is close to that of human bone[9-15].

PEEK can be used as fixed crowns after its surface is etched to create a more wetttable surface and to facilitate its bonding with hydrophobic resin composites. Many studies suggested the use of PEEK as a coping material and it would be more advantageous than alloy and ceramic restorations because of its mechanical properties that is close to enamel and dentin[14, 16-19].

CBCT imaging is accomplished by employing a rotating gantry to which an x-ray source and detector are fixed. A divergent pyramidal or conical supply of radiation is directed through the middle of the realm of interest onto a region x-ray detector on the alternative side. The x-ray supply and detector rotate around a rotation pin mounted within the middle of the region of interest. Throughout the rotation, multiple [from one hundred fifty to over six hundred] consecutive coplanar projection pictures of the field of view are collected in a very complete, or generally partial arc[20].

The number one advantage of cone beam computed tomography is that it produces unique pictures demonstrating options in 3D that intraoral, panoramic and cephalometric pictures cannot. CBCT unit reconstruct the projection data to produce interrelational pictures in 3 orthogonal planes [axial, sagittal and coronal]. Additionally, as a result of the reconstruction of CBCT, data is performed natively employing a computer, information are often reoriented so that the patient anatomic features are realigned. Basic enhancements include zoom or magnification, window\level and the ability to add annotation. Cursor-driven measuring algorithms give the dental surgeon with associate interactive capability for real-time dimensional assessment. Onscreen measurements give dimensions free from distortion and magnification[20].

Implant success greatly depends on the primary stability and the osseo-integration during the healing period. Because of these two factors, dentists agreed that the status of implant bone interface must be verified before and even after the prosthetic phase[21].

Because of the need for a nondestructive and noninvasive gadget to assess the implant– bone interface status in vivo, another device [Osstell] which uses resonance frequency analysis [RFA] was produced. This device uses a transducer that is directly connected to the implant body or to the abutment on the implant. The resonance frequency analysis values give us information about implant stability, implant failure and bone crestal dimensions of the implants[22, 23].

Osstell system turned out to be more accurate contrasted with Periotest system in estimating dental implant stability in hard and in soft tissues[24].

2. Aim of the study

This study was conducted to measure the difference between Chrome Cobalt telescopic crowns and Poly ether ether ketone [PEEK] telescopic crowns retaining implant retained partial overdenture regarding implant stability, crestal bone height changes and periodontal pocket depths.

3. Materials and Methods

Fourteen patients having Kennedy class I in the lower arch with first premolar being the last standing abutment were selected. Figure(1)

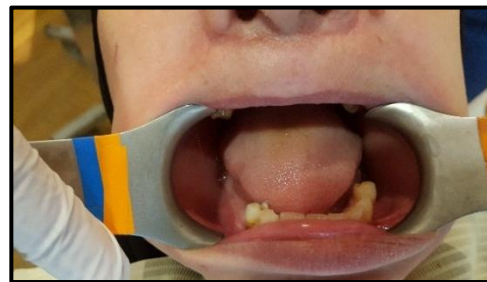

Figure 1: Kennedy class I patient

Patients were carefully informed about the treatment procedure and agreed to take part in the study for a period of one year. A cone beam computed tomography [CBCT] was taken for the patients preoperatively to evaluate the bone height, width and density in the area of interest. It was performed also to ensure that the patients are free from any pathological lesions. Figure(2)

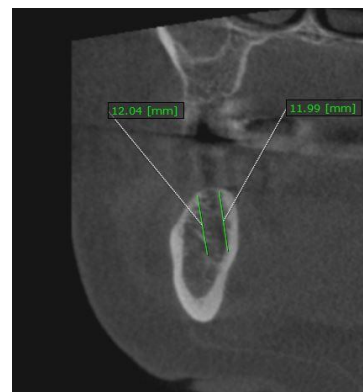


Figure 2: Preoperative cone beam CT

All the patients received the same kind of implants [Neobiotech IS II Active Fixture, Korea], so that we ensure the same outcome. Two implants were placed in each patient in the posterior mandible area [estimate in the lower 7 region]. Flap was raised and implants were placed using free hand technique. Figure(3)

After implants were placed. They were covered by the cover screw and the flap was sutured. The same technique was done for all the fourteen patients.

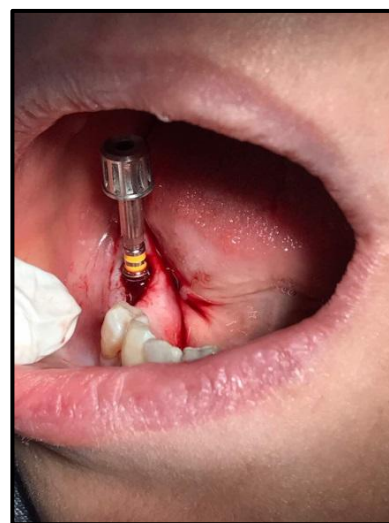

Figure 3: Implant Placement

After four months, all the implants were exposed, and healing collars were placed for each patient for one week to allow soft tissue healing. After one week the healing collars were removed and the abutments were placed in position to start the prosthetic phase.

Patients were divided randomly into two equal groups; each group consists of seven patients. The first group received partial overdenture covering chrome cobalt telescopic crowns over the implants. The second group received partial overdenture covering polyetherether ketone telescopic crowns over the implants.

Primary impressions were taken for every patient to prepare for a special tray. Then secondary impressions were taken for the fabrication of the telescopic crowns using open tray technique. Telescopic crowns were fabricated and cemented over the implant abutments. Figure(4,5)

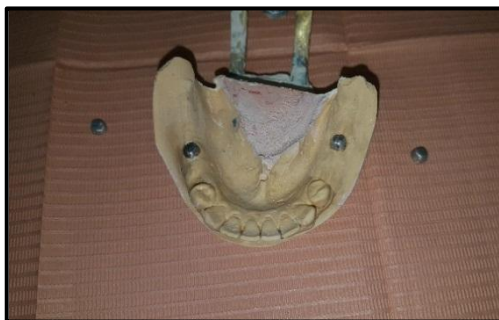

Figure 4:CrCo. Telescopic crown

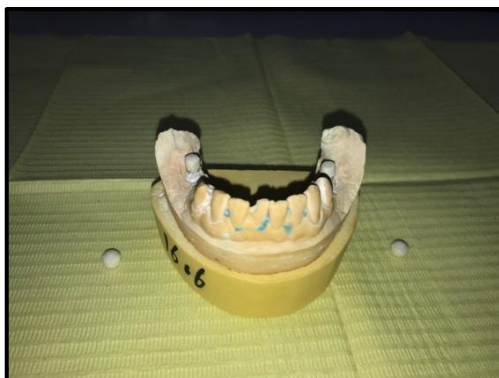

Figure 5: Peek Telescopic crown

Custom made perforated acrylic resin tray was constructed and preliminary surveying of the lower study cast was carried out to establish a suitable path of insertion and removal, and the needed mouth preparation. Inside the patient's mouth, mesial occlusal rest seat and distal guiding plane were prepared on the first premolar bilaterally. Final impression was taken and poured into improved dental stone to obtain master cast. Secondary surveying was done for master casts before duplication. The partial denture framework was casted in cobalt-chromium alloy.

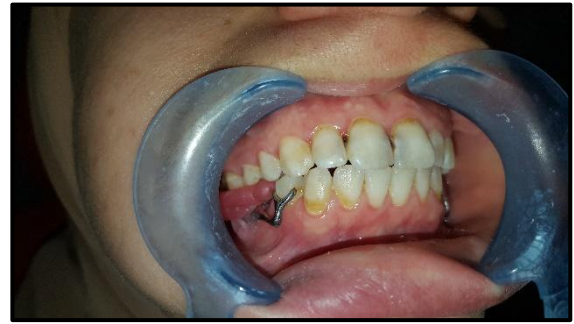

Figure 6: Metal Framework try in

Metal framework try in was done to ensure proper seating of the partial denture without any interferences. Bite registration were done. Figure(6)

Waxed partial dentures were then tried inside patient's mouth, and then processed using heat cured acrylic resin [Acrostone Dental Factory, Cairo, Egypt], finished and polished, and the denture was delivered to the patient. Figure(7)

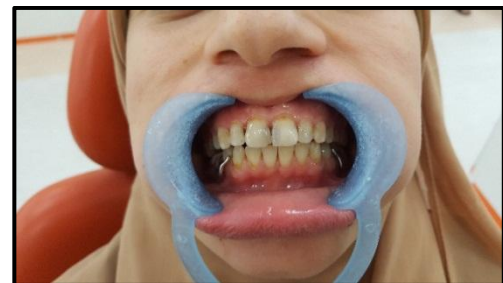

Figure 7: Finished denture

Clinical follow up

Cone beam computed tomography was used to detect changes in crestal bone height at denture insertion, after six and twelve months follow up period.

On each follow up visit, mesial and distal crestal bone levels were calculated from the reconstructed corrected sagittal views by drawing a line parallel to the implant serration extending from the crestal bone to the apical end of the implant. Similarly, buccal and lingual bone levels were calculated by using cross-sectional views. Average readings of the four sides at each interval were calculated and tabulated for statistical analysis.

Implant stability was measured using resonance frequency analysis (Osstell® Integration Diagnostics AB, Gothenburg, Sweden) at denture insertion, six and twelve months follow up period.

Periodontal pocket depths was measured using graduated periodontal probe, the probe was gently inserted at each surface [Mesial, Distal, Buccal and Lingual] parallel to the long axis of the implant and then the average of all four sides were taken and tabulated for statistical analysis. The measurements were made at denture insertion; six and twelve months follow up period.

4. Results

A. Crestal Bone Height:

Comparison of crestal bone height [mm] between CrCo and PEEK telescopic crowns at each follow-up period:

At overdenture insertion, the mean crestal bone height was significantly higher in PEEK group than in CrCo group (P=0.000). After 6 months, PEEK group yielded significantly higher mean values than CrCo group (P=0.003). At 12 months, the crestal bone height was also significantly higher in PEEK group than CrCo group (P=0.018).

Table 1: Mean ± Standard Deviation [SD] and P-value for the comparison of crestal bone height [mm] between CrCo and PEEK telescopic crowns at each follow-up period.

	CrCo	PEEK	P-value
At insertion	8.63 ± 0.68	9.58 ± 0.52	0.000*
6 months	8.22 ± 0.71	9.03 ± 0.57	0.003*
12 months	7.6 ± 0.62	8.43 ± 0.54	0.018*

*: Significant at P ≤ 0.05

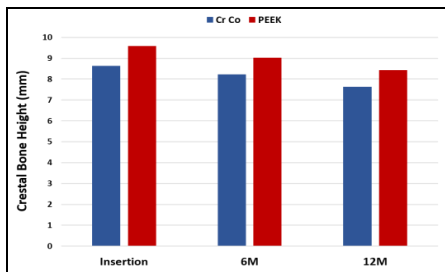


Figure 4: Bar chart showing crestal bone height [mm] in CrCo and PEEK telescopic crowns groups at each follow-up period.

B. Implant Stability

Comparison of implant stability quotient values [ISQ] between CrCo and PEEK telescopic crowns at each follow-up period:

At each follow-up period, there were no statistically significant differences in Osstell readings between CrCo and PEEK groups (P=0.256, P=0.588 and P=0.504; at insertion, 6 months and 12 months respectively).

Table 2: Mean ± Standard Deviation [SD] and P-value for the comparison of implant stability quotient values [ISQ] between CrCo and PEEK telescopic crowns at each follow-up period

	CrCo	PEEK	P-value
At insertion	70.4 ± 1.03	71.01 ± 1.66	0.256NS
6 months	72.37 ± 0.87	72.64 ± 1.62	0.588NS
12 months	72.46 ± 0.85	72.78 ± 1.55	0.504NS

NS: not significant

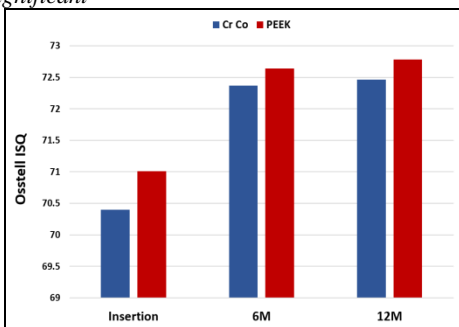


Figure 5: Bar chart showing ISQ values in CrCo and PEEK telescopic crowns groups at each follow-up period.

C. Periodontal Pocket Depth

Comparison of pocket depth [mm] between CrCo and PEEK telescopic crowns at each follow-up period:

There were no statistically significant differences between pocket depth mean values between CrCo and PEEK groups at overdenture insertion [P=0.902] and 6 months [P=0.168]. While CrCo group displayed significantly higher mean pocket depth than PEEK group [P=0.001].

Table 3: Mean ± Standard Deviation [SD] and P-value for the comparison of pocket depth [mm] between CrCo and PEEK telescopic crowns at each follow-up period

	CrCo	PEEK	P-value
At insertion	1.47±0.25	1.48±0.20	0.902NS
6 months	1.71±0.22	1.59±0.19	0.168NS
12 months	2.01±0.21	1.72±0.19	0.001*

*: Significant at P ≤ 0.05

NS: not significant

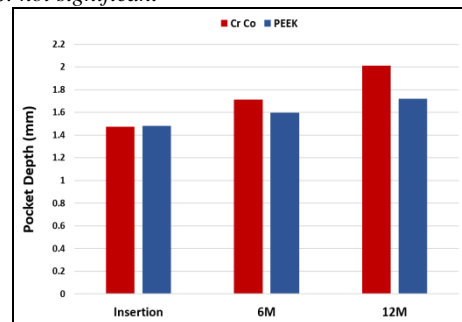


Figure 6: Bar chart showing pocket depths [mm] in CrCo and PEEK telescopic crowns groups at each follow-up period.

5. Discussion

In this study fourteen partially edentulous patients were selected with mandibular kennedy class I with the first premolar as the last standing abutment. As most of the problems of kennedy class I are related to support and retention, distal implant was placed in each side of the edentulous area to try to two stage surgical protocol was followed to omit the effect of early loading on implants, thus permitting uninterrupted osseointegration. Prospective clinical studies showed that two-stage system was preferred because it showed higher bone contact percentage, than one-stage system [26].

Because of its advantages in retaining implant supported overdentures, telescopic crowns were used in this study as its advantages include , the need for lesser number of implants, comparatively higher retention and flexible prosthetic design that can be easily adjusted in case of implant loss[27-30].

Two types of telescopic crowns were fabricated over the implants, chrome cobalt and PEEK to increase the retention of the prosthesis. The partial overdenture was designed and fabricated to cover the implants and the telescopic crown.

Implant supported telescopic partial overdenture was chosen as a treatment option as it is a reliable method of treatment of atrophied arches that ensures better masticatory function, esthetics, oral hygiene in addition to improved retention and stability[6].

Cone beam computed tomography was used in this study as it produces images that provide valuable information in relation to implant dentistry. CBCT is an exact and quick technique to represent and assess detailed photos of the trabecular structure in addition to permitting a three-dimensional remaking of the bone structure to be accomplished. CBCT was used effectively to detect bone height. Consequently, using CBCT for assessment of bone changes around the studied implants added accuracy to the results[31].

Resonance Frequency Analysis [RFA] technique using Ostell was used in this study for measuring dental implant stability due to the constant increase of its use in scientific researches throughout the recent years which is based on its high effectiveness[32].

Pocket depth was measured to assess the condition of the implants because in many recent studies it proved to be a reliable parameter in evaluating implant success[33].

All the patients in this study were satisfied with their implant supported mandibular overdenture and accommodated to their use within few days after delivery. All the implants investigated during the follow-up period showed satisfactory results within the confinement of the parameters studied.

By the end of the 12 months follow up period, there was significant decrease in the bone height in the two groups within the follow up period. The chrome cobalt telescopic crowns and the PEEK telescopic crowns. The decrease in the bone height in the chrome cobalt telescopic crown group was 1mm while the decrease in the PEEK telescopic crown group was 1.1 mm. This amount of reduction falls within the acceptable range of implant success and it agrees with the findings of Merheb J. et al.[34, 35].

There was a significant difference between the chrome cobalt telescopic crowns and the PEEK telescopic crowns. The PEEK telescopic crowns showed higher bone levels at the three follow up periods, but the amount of bone decrease in the two groups within the follow up period were almost the same. This is usually due to the bone reaction of some patients in the chrome cobalt telescopic crowns group which led to this difference at denture insertion, but since the decrease in the bone level within the two groups during the follow up period were almost the same, then the telescopic crowns had no effect in this decrease in bone level.

Concerning the implant stability, within the two groups, the Ostell readings were significantly lowest at overdenture insertion. While there was no statistically significant difference between Ostell readings at 6 and 12 months. The great changes in implant stability followed by the slow change are due to the formation of woven bone and the deposition of lamellar bone between zero and 4.5 months however, bone maturity is completed within almost 13 months [plateau effect] [36].

At each follow-up period, there were no statistically significant differences in Ostell readings between CrCo and PEEK groups; this suggests that the two types of telescopic crowns had the same effect on the stability of dental implants.

The periodontal pocket depths within CrCo group was significantly highest after 12 months, followed by that measured at 6 months. The significantly lowest mean values were recorded at overdenture insertion. Within PEEK group, the mean pocket depth after 12 months was significantly higher than at overdenture insertion. While the mean value recorded after 6 months had no significant difference with those measured at insertion and 12 months.

This increase is attributed to the gingival inflammation caused by overdenture therapy and also to the decrease in crestal bone height surrounding the abutment. These findings agree with Renner et al, Toolson et al and Telleman et al.[37-40].

There were no statistically significant differences between pocket depth mean values between CrCo and PEEK groups at overdenture insertion and 6 months follow up periods. But after 12 months CrCo group displayed significantly higher mean pocket depth than PEEK group.

This could be explained as the PEEK has better biocompatible nature, less plaque accumulation and almost no gingival inflammation around the implants due to its highly polished surface[41, 42].

6. Conclusions

From the results of this study the, the following conclusions could be obtained

- 1) There were almost no difference in crestal bone height resorption between the CrCo and the PEEK telescopic crowns.
- 2) The difference between implant stability in both groups were non-significant

At the end of the follow up period, the PEEK telescopic crown group showed lesser periodontal pocket depths than the CrCo group which suggests that the PEEK is more biocompatible than the metallic crowns.

References

- [1] I. Dahab, A. El-Gendy, I. Eltorkey, "In vitro stress analysis study of different prosthetic options using single posterior implant for management of mandibular unilateral distal extension saddle," Tanta Dent J, 12, p. 7-15, 2015.
- [2] A.I. Mahrous, H.A. Aldawash, T.A. Soliman, F.H. Banasr, A. Abdelwahed, "Implant supported distal extension over denture retained by two types of attachments. A comparative radiographic study by cone beam computed tomography," J Int Oral Health, 7, p. 5, 2015.
- [3] A.M. Alam-Eldein, F.A. El Fattah, E. Shakal, "Comparative study of two different designs of partial over denture supported with distal implant for the treatment of mandibular Kennedy class II cases," Tanta Dent J, 10, p. 39-47, 2013.
- [4] R. Shahmiri, R. Das, J.M. Aarts, V. Bennani, "Finite element analysis of an implant-assisted removable partial denture during bilateral loading: Occlusal rests position," J Prosthet Dent, 112, p. 1126-1133, 2014.

- [5] M. Sato, Y. Suzuki, D. Kurihara, H. Shimpo, C. Ohkubo, "Effect of implant support on mandibular distal extension removable partial dentures: relationship between denture supporting area and stress distribution," *J Prosthodont Res*, 57, p. 109-112, 2013.
- [6] R. Morandi, L.M. Cabral, M. de Moraes, "Implant-supported maxillary denture retained by a telescopic abutment system: A clinical report," *J Prosthet Dent*, 117, p. 331-334, 2017.
- [7] T. Joda, "Combined tooth-implant-supported telescopic prostheses in a midterm follow-up of > 2 years," *Int J Prosthodont*, 26, p. 536-540, 2013.
- [8] P. Zoidis, I. Papatasiou, G. Polyzois, "The use of a modified poly-ether-ether-ketone [PEEK] as an alternative framework material for removable dental prostheses. A clinical report," *J Prosthodont*, 25, p. 580-584, 2016.
- [9] J. Altmeyer, J. Dos Santos, S. Amancio-Filho, "Effect of the friction riveting process parameters on the joint formation and performance of Ti alloy/short-fibre reinforced polyether ether ketone joints," *Mater Design*, 60, p. 164-176, 2014.
- [10] P. Scolozzi, "Maxillofacial reconstruction using polyetheretherketone patient-specific implants by "mirroring" computational planning," *Aesthetic Plast Surg*, 36, p. 660-665, 2012.
- [11] E.T. Camarini, J.K. Tomeh, R.R. Dias, E.J. da Silva, "Reconstruction of frontal bone using specific implant polyether-ether-ketone," *J Craniofac Surg*, 22, p. 2205-2207, 2011.
- [12] C.C. Niu, J.C. Liao, W.J. Chen, L.H. Chen, "Outcomes of interbody fusion cages used in 1 and 2-levels anterior cervical discectomy and fusion: titanium cages versus polyetheretherketone [PEEK] cages," *J Spinal Disord Tech*, 23, p. 310-316, 2010.
- [13] B. Stawarczyk, M. Eichberger, J. Uhrenbacher, T. Wimmer, D. Edelhoff, P.R. Schmidlin, "Three-unit reinforced polyetheretherketone composite FDPs: Influence of fabrication method on load-bearing capacity and failure types," *Dent Mater J*, 34, p. 7-12, 2015.
- [14] J. Uhrenbacher, P.R. Schmidlin, C. Keul, M. Eichberger, M. Roos, W. Gernet, et al, "The effect of surface modification on the retention strength of polyetheretherketone crowns adhesively bonded to dentin abutments," *J Prosthet Dent*, 112, p. 1489-1497, 2014.
- [15] S. Najeeb, Z.K. Bds, S.Z. Bds, M.S.Z. Bds, "Bioactivity and osseointegration of PEEK are inferior to those of titanium: a systematic review," *J Oral Implantol*, 42, p. 512-516, 2016.
- [16] P.R. Schmidlin, B. Stawarczyk, M. Wieland, T. Attin, C.H. Hämmerle, J. Fischer, "Effect of different surface pre-treatments and luting materials on shear bond strength to PEEK," *Dent Mater*, 26, p. 553-559, 2010.
- [17] B. Stawarczyk, F. Beuer, T. Wimmer, D. Jahn, B. Sener, M. Roos, et al., "Polyetheretherketone—a suitable material for fixed dental prostheses?," *J Biomed Mater Res B Appl Biomater*, 101, p. 1209-1216, 2013.
- [18] O. Sproesser, P.R. Schmidlin, J. Uhrenbacher, M. Roos, W. Gernet, B. Stawarczyk, "Effect of sulfuric acid etching of polyetheretherketone on the shear bond strength to resin cements," *J Adhes Dent*, 16, p. 465-472, 2014.
- [19] C. Keul, A. Liebermann, P.R. Schmidlin, M. Roos, B. Sener, B. Stawarczyk, "Influence of PEEK surface modification on surface properties and bond strength to veneering resin composites," *J Adhes Dent*, 16, p. 383-392, 2014.
- [20] W.C. Scarfe, A.G. Farman, "What is cone-beam CT and how does it work?," *Dent Clin North Am*, 52, p. 707-730, 2008.
- [21] L. Walker, H.F. Morris, S. Ochi, "Periotest values of dental implants in the first 2 years after second-stage surgery: DICRG interim report no. 8. Dental Implant Clinical Research Group," *Implant Dent*, 6, p. 207-212, 1997.
- [22] H.M. Huang, C.L. Chiu, C.Y. Yeh, C.T. Lin, L.H. Lin, S.Y. Lee, "Early detection of implant healing process using resonance frequency analysis," *Clin Oral Implants Res*, 14, p. 437-443, 2003.
- [23] B. Friberg, L. Sennerby, N. Meredith, U. Lekholm, "A comparison between cutting torque and resonance frequency measurements of maxillary implants: a 20-month clinical study," *Int J Oral Maxillofac Surg*, 28, p. 297-303, 1999.
- [24] S. Al-Jetaily, A.A. Al-dosari, "Assessment of Osstell™ and Periotest® systems in measuring dental implant stability [in vitro study]," *Saudi Dent J*, 23, p. 17-21, 2011.
- [25] D.J. Baylink, J.E. Wergedal, K. Yamamoto, E. Manzke, "Systemic factors in alveolar bone loss," *J Prosthet Dent*, 31, p. 486-505, 1974.
- [26] A.K. Røynesdal, B. Amundrud, H.R. Hannæs, "A comparative clinical investigation of 2 early loaded ITI dental implants supporting an overdenture in the mandible," *Int J Oral Maxillofac Implants*, 16, p. 246-251, 2001.
- [27] J.F.M. Ferrer, A.M. González, B.O. Galdón, K.B. Juanes, F.B. Iranzo, A.C. Tomás, "Telescopic crowns in adult case with lip and palate cleft: update on the etiology and management," *Med Oral Patol Oral Cir Bucal*, 11, p. 358-362, 2006.
- [28] S. Beschnidt, S. Chitmongkolsuk, R. Prull, "Telescopic crown-retained removable partial dentures: review and case report," *Compend Contin Educ Dent*, 22, p. 927-932, 2001.
- [29] V. Szentpétery, C. Lautenschläger, J.M. Setz, "Longevity of frictional telescopic crowns in the severely reduced dentition: 3-year results of a longitudinal prospective clinical study," *Quintessence Int*, 41, p. 749-758, 2010.
- [30] Y. Sakai, H. Takahashi, N. Iwasaki, Y. Igarashi, "Effects of surface roughness and tapered angle of cone crown telescopic system on retentive force," *Dent Mater J*, 30, p. 635-641, 2011.
- [31] B. Hohlweg-Majert, M. Metzger, T. Kummer, D. Schulze, "Morphometric analysis—cone beam computed tomography to predict bone quality and quantity," *J Craniofac Surg*, 39, p. 330-334, 2011.
- [32] J.M. Kim, S.J. Kim, I. Han, S.W. Shin, J.J. Ryu, "A comparison of the implant stability among various implant systems: clinical study," *J Adv Prosthodont*, 1, p. 31-36, 2009.
- [33] P. Coli, V. Christiaens, L. Sennerby, H.D. Bruyn, "Reliability of periodontal diagnostic tools for

- monitoring peri-implant health and disease," *Periodontol* 2000, 73, p. 203-217, 2017.
- [34] J. Merheb, M. Vercruyssen, W. Coucke, L. Beckers, W. Teughels, M. Quirynen, "The fate of buccal bone around dental implants. A 12month postloading follow-up study," *Clin Oral Implants Res*, 28, p. 103-108, 2017.
- [35] M. Ajanović, A. Hamzić, S. Redžepagić, A. Kamber-Ćesir, L. Kazazić, S. Tosum, "Radiographic Evaluation Cervical Crestal Bone Resorption around Dental Implants in Maxilla and Mandible: One Year Study," *Pesqui Bras Odontopediatria Clin Integr*, 14, p. 219-224, 2014.
- [36] D. Cochran, R. Schenk, A. Lussi, F. Higginbottom, D. Buser, "Bone response to unloaded and loaded titanium implants with a sandblasted and acid-etched surface: A histometric study in the canine mandible," *J Biomed Mater Res*, 40, p. 1-11, 1998.
- [37] R. Renner, B. Gomes, M. Shakun, P. Baer, R. Davis, P. Camp, "Four-year longitudinal study of the periodontal health status of overdenture patients," *J Prosthet Dent*, 51, p. 593-598, 1984.
- [38] R. Davis, R. Renner, E. Antos, E. Schlissel, P. Baer, "A two-year longitudinal study of the periodontal health status of overdenture patients," *J Prosthet Dent*, 45, p. 358-363, 1981.
- [39] L.B. Toolson, T.D. Taylor, "A 10-year report of a longitudinal recall of overdenture patients," *J Prosthet Dent*, 62, 179-181, 1989.
- [40] G. Telleman, G.M. Raghoobar, A. Vissink, H.J. Meijer, "Impact of platform switching on peri-implant bone remodeling around short implants in the posterior region, 1-year results from a split-mouth clinical trial," *Clin Implant Dent Relat Res*, 16, p. 70-80, 2014.
- [41] B. Siewert, M. Parra, "A new group of material in dentistry," *Peek as a framework material used in*, p. 148-159, 2013.
- [42] N. Sinha, N. Gupta, K.M. Reddy, Y. Shastry, "Versatility of PEEK as a fixed partial denture framework," *J Indian Prosthodont Soc*, 17, p. 80-83, 2017.

Author Profile

Ayman H. Amin. The B.D.S. Ain Shams University, Faculty of Dentistry 2002. Assistant Lecturer British University, Egypt. M.Sc. degree in prosthodontics, Faculty of Dentistry. Cairo University, 2010.