

Bilateral Juvenile Open Angle Glaucoma: A Rare Case Report

Dr. Monalisa Deori¹, Dr. Jayant Ekka², Dr. Jawahar Jyoti Kuli³

¹Post-Graduate Student, Department of Ophthalmology, Assam Medical College, Dibrugarh, Assam, India

²Former Post-Graduate Student, Department of Ophthalmology, Assam Medical College, Dibrugarh, Assam, India

³Professor & Head, Department of Ophthalmology, Assam Medical College, Dibrugarh, Assam, India

Abstract: Juvenile open angle glaucoma (JOAG) is a rare subset of primary open angle glaucoma (POAG) that appears later in childhood or early adulthood. We report a case of 16 year-old girl with progressive vision diminution of both eye (BE) presenting with no perception of light in right eye (RE) and only perception of light in left eye (LE). There was no other ocular or systemic problem. Intraocular pressure (IOP) was 50 mmHg in each eye. There was wide open angle configuration of anterior chamber in BE on gonioscopy. Dilated fundus examination revealed pale optic disc with near total cupping in RE & 0.8 - 0.9 cupping in LE. Thinning of the neuroretinal rim, nasal shifting and bayoneting of the blood vessels were noted in BE. Maximal medical therapy was administered to lower the IOP, with minimal success. Subsequently, Trabeculectomy with topical antimetabolite was performed in left eye, with adequate control of her IOP. Postoperatively, her vision on left eye improved up to hand movement positive. Conclusion- Rarity of the disease and delay in diagnosis often leads to advanced glaucomatous damage of the optic nerve. Hence, IOP measurement must be done as a part of routine ophthalmic examination to overcome the disease burden.

Keywords: JOAG, POAG, Juvenile, glaucoma, neuroretinal rim

1. Introduction

Glaucoma is the second leading cause of irreversible blindness worldwide.[1],[2] Juvenile open-angle glaucoma (JOAG) is an rare subtype of Primary open-angle glaucoma (POAG) that appears later in childhood or early adulthood.[3] It is distinct from other types of congenital or childhood glaucomas that present with ocular abnormalities like buphthalmos, megalocornea, Haabstriae or other systemic developmental abnormalities. It is usually autosomal-dominant form of chronic open angle glaucoma.[4] However, it is found to be more common in males than in females, and in patients with myopic refractive status.[5] Bilateral JOAG patients often has a strong family history than those with unilateral JOAG.[5] To determine the disease progression the visual field (VF) tests, intraocular pressure (IOP) measurement and periodic eye examinations in patients with positive family history of glaucoma are very important.

2. Case Report

A 16-year-old female presented with diminution of vision in right eye (RE) since 6 months which was insidious in onset, gradually progressive. A month later, she had similar episode in left eye with progressive deterioration of vision. Medical history including long term use of steroids, previous refractive surgery and patient's family history of glaucoma were not significant. The patient denied perception of light in right eye & in left eye only up to perception of light with inaccurate projection of rays in superior and nasal quadrant of the visual field at the time of presentation.

3. Clinical Examination

Her Intraocular pressure (IOP) was found to be 50 mmHg in both eye (BE) with non-contact tonometry (NCT). On slit-

lamp biomicroscopy, mild edema of the cornea was noted in both the eyes. Gonioscopy revealed wide open angle configuration of anterior chamber. Dilated fundus examination, revealed glaucomatous optic nerve head damage in BE. In RE, optic disc was pale, disc margins were well-defined, cup-to-disc ratio showed near total cupping with thinning of the neuroretinal rim, nasal shifting of blood vessels and presence of Bayoneting sign. While in LE cup-to-disc ratio was 0.8-0.9 cupping. The visual field tests and optical coherence tomography was not done in this case due to poor fixation. Corneal diameters, keratometry and axial length were normal. No other ocular structural abnormalities and systemic illness were found.

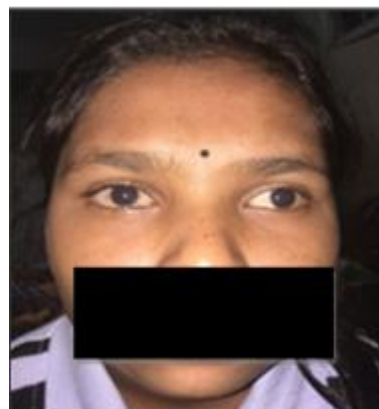

Figure 1: Patient's appearance during first visit

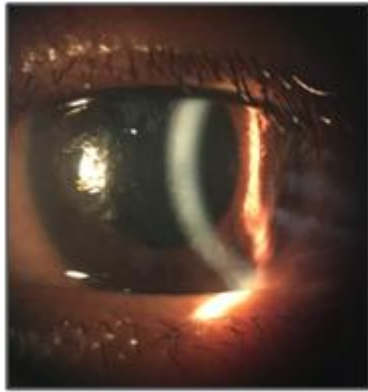


Figure 2: Slit lamp image

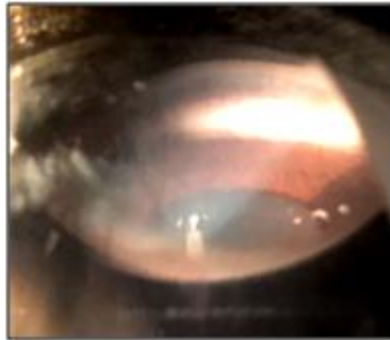


Figure 3: Gonioscopic image

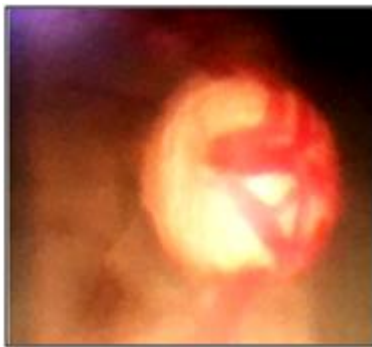

Figure 4: Optic nerve head image of LE.

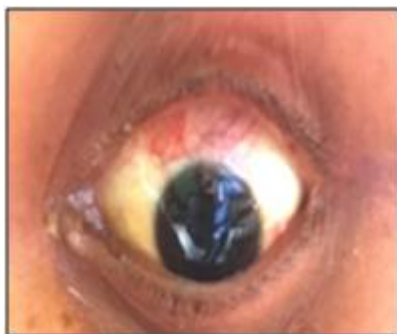


Figure 5: Trabeculectomy bleb on postoperative day 7

Treatment

The patient was started on topical combined IOP lowering drugs and systemic acetazolamide (oral). After one week she was taken up for surgery (*Trabeculectomy with intraoperative Mitomycin-C*) in LE under local anaesthesia after taking written consent from her parents. On postoperative day 1, her IOP in LE was 20 mmHg which had further reduced to 16 mmHg at one week postoperative period. Her vision in LE was improved to hand movement

positive. The fellow eye was planned for *Cyclodestructive* surgery at a later date and was advised for periodic follow-up visit.

4. Discussion

JOAG differs from adult onset POAG in its age of onset and the severity of IOP. [3] Recent population-based studies suggest that the incidence of JOAG was 0.38 per 100,000 residents between the age of 4 and 20 years. [6]

JOAG is found to be associated with myopia and high IOP despite maximal medical treatment. [5],[7],[8] Studies have also reported JOAG to be more common in male than in females. [5] On the contrary, *we report a case in a 16-year old female patient with absent family history of glaucoma.*

Surgery remains the mainstay of treatment, as their response to drug and laser treatment is minimal, ⁴ and in this case also there was poor control of IOP with maximal medical treatment. *Pathania et al.* [9] have also reported the success rate of 89% at 3 years and 79% at 5 years after trabeculectomy.

Moreover, a patient with JOAG remains asymptomatic for a longer period unless the IOP is very high, as in our case, the disease was diagnosed very late due to which her vision was reduced to light perception. Hence, early detection and prompt treatment of these patients help to preserve good vision and improve the vision related quality of life. [10]

5. Conclusion

Rarity of the disease and delay in diagnosis often leads to advance glaucomatous damage to the optic nerve. Hence, IOP measurement must be considered as a part of routine ophthalmic examination to overcome the disease burden. Further large-scale prospective studies would be needed regarding the disease severity, frequency and sex preponderance, to come to a definite conclusion.

References

- [1] Quigley HA. Number of people with glaucoma worldwide. *British journal of ophthalmology*. 1996 May 1;80(5):389-93.
- [2] Quigley HA, Broman AT. The number of people with glaucoma worldwide in 2010 and 2020. *British journal of ophthalmology*. 2006 Mar 1;90(3):262-7.
- [3] Allingham RR, editor. Childhood glaucomas; clinical presentation. In: *Shields text book of glaucoma*. 6th ed. India: Wolters Kluwer;2017.p.218.
- [4] Allingham RR, editor. Childhood glaucomas; clinical presentation. In: *Shields text book of glaucoma*. 6th ed. India: Wolters Kluwer;2017. p.143.
- [5] Kwun Y, Lee EJ, Han JC, Kee C. Clinical characteristics of juvenile-onset open angle glaucoma. *Korean Journal of Ophthalmology*. 2016 Apr 1;30(2):127-33.
- [6] Aponte EP, Diehl N, Mohny BG. Incidence and clinical characteristics of childhood glaucoma: a

- population-based study. Arch Ophthalmol 2010;128:478–482.
- [7] Lotufo D, Ritch R, Szmyd L, Burriss JE. Juvenile glaucoma, race, and refraction. *Jama*. 1989 Jan 13;261(2):249-52.
- [8] Park SC, Kee C. Large diurnal variation of intraocular pressure despite maximal medical treatment in juvenile open angle glaucoma. *Journal of glaucoma*. 2007 Jan 1;16(1):164-8.
- [9] Pathania D, Senthil S, Rao HL, Mandal AK, Garudadari CS. Outcomes of trabeculectomy in juvenile open angle glaucoma. *Indian journal of ophthalmology*. 2014 Feb;62(2):224.
- [10] Rahi JS, Cumberland PM, Peckham CS. Visual impairment and vision-related quality of life in working-age adults: findings in the 1958 British birth cohort. *Ophthalmology*. 2009 Feb 1;116(2):270-4.