

Radiological Evaluation of Neonatal Lung Pathologies

Dr Ankur Chandra¹, Dr C. Raychaudhuri²

¹1ST Year Resident, SBKSMIRC, Pipariya, Waghodia, Baroda, India

²Head of Department, Radiodiagnosis, SBKSMIRC, Pipariya, Waghodia, Baroda, India

Abstract: Background: A wide spectrum of disorders may affect the lung of neonate. Although ultrasound, CT and MRI may play a role in the diagnosis and characterization of some neonatal lung disorders, chest radiographs are primarily imaging modality used in most cases. Interpretation of neonatal chest radiographs can be challenging, because many diseases produce similar imaging findings. However, by using a systematic pattern based approach described here, one can narrow the differential diagnosis and provide essential information critical to clinical decision making. Materials and Methods: This study included 38 newborns who were admitted in the special care baby unit in Dhiraj General Hospital. Antero-posterior chest xray in supine position of neonates (pre-term, term and post-dated) were examined. Chest X – rays were taken by a portable X – ray machine using (100 cm) focus field distance, (45 – 50 kVp) and (4 – 5 mAs). Final diagnosis was based on clinical, radiological and laboratory findings. Result: In preterm (28-32 weeks), 21% of neonates had pulmonary pathologies in which respiratory distress syndrome (62.5%) was most common. In preterm (32-36 weeks), 39.50% neonates had pulmonary pathologies in which transient tachypnoea of newborn (46.67%) was most common followed by pneumonia (26.67%). In neonates >36weeks and post-dated neonates, 39.50% had pulmonary pathologies in which transient tachypnoea of new-born (26.67%) was common followed by meconium aspiration syndrome (20%) and congenital diaphragmatic hernia (13.33%). Over all transient tachypnea of newborn (28.94%) was most common followed by respiratory distress syndrome (21.05%), pneumonia (15.79%) and meconium aspiration syndrome (7.9%), primary pulmonary hypertension (5.26%), congenital diaphragmatic hernia (5.26%), congenital heart disease (5.26%) and others (10.52%). Conclusion: Chest xray is essential in neonates with acute respiratory distress to exclude structural abnormalities such as congenital diaphragmatic hernia or congenital lobar emphysema. Any sign of post-natal respiratory distress is an indication for chest xray which should be taken as early as possible.

Keywords: full-term, lung, neonatal, preterm

1. Introduction

Neonatal respiratory disorders account for most admissions to neonatal intensive care units in the immediate new born period. Neonate in respiratory distress must be evaluated promptly and accurately.

The chest X-ray is the most valuable imaging modality in the assessment of the neonate with respiratory distress.

Whilst many of the radiological appearances are relatively non-specific, integration of the clinical features, gestational age of neonate with the x-ray appearances will help the clinician arrive at the correct diagnosis in most cases.

This paper will describe the radiological evidences of the most important causes of neonatal respiratory distress along with a statistical analysis and co-relation with gestational age of newborn whether early preterm, late preterm, term or post dated.

Aims and Objectives

- To know the range of chest radiographic findings in newborn babies suffering from respiratory distress, at or soon after birth.
- To know which neonatal lung pathology is common at different gestational age.

2. Materials and methods

This study included 38 newborns who were admitted in the special care baby unit in Dhiraj General hospital, from 1st January 2017 to 31st May 2017. Antero-posterior chest radiograph in supine position of (38) neonates (pre-term, term and post-dated) were examined. Additional radiograph were taken on request. Chest X – rays were taken by a portable X – ray machine using (100 cm) focus field distance, (45 – 50 kVp) and (4 – 5 mAs). Final diagnosis was based on clinical, radiological and laboratory findings.

Conditions

Disorders of Aeration

Transient tachypnea of the newborn
Idiopathic respiratory distress syndrome
Meconium aspiration syndrome
Neonatal pneumonia
Primary pulmonary hypertension
Pleural effusion

Disorders of Circulation

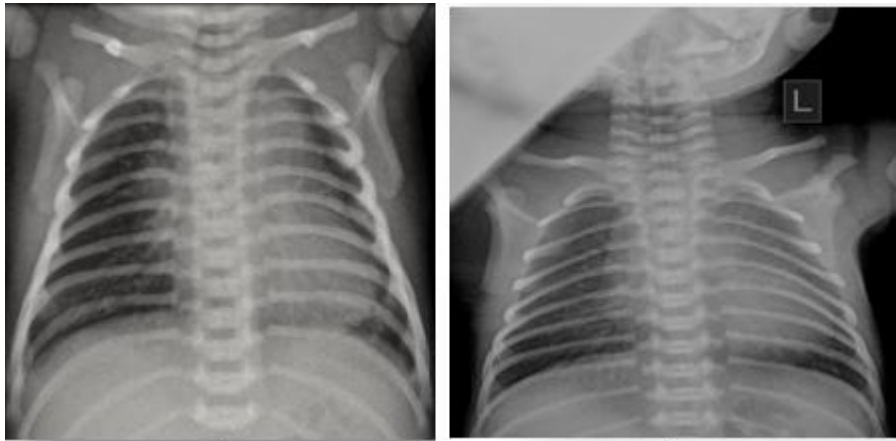
Congenital heart disease

Developmental Abnormality

Tracheo-esophageal fistula and esophageal atresia
Congenital diaphragmatic hernia
Congenital lobar emphysema
Skeletal anomalies

3. Cases

Transient tachypnea of newborn

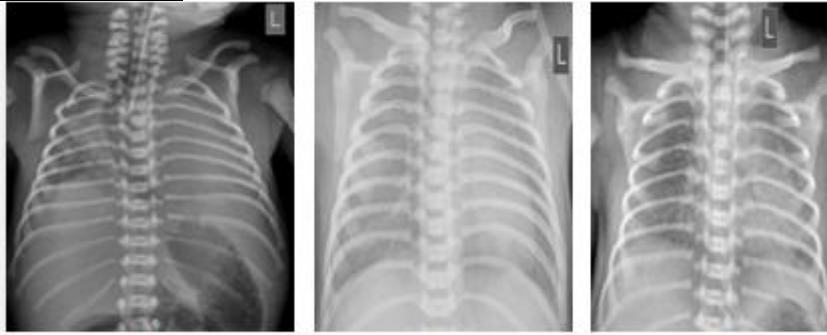


1

2

1. Slightly overinflated lung fields with increased interstitial streaky shadowing
2. Prominent Vascular markings with Hazy margins in a preterm of 33 wks.

Respiratory distress syndrome (HMD)



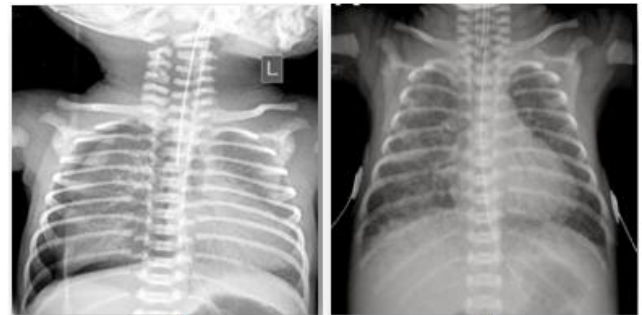1

2

3

- 1) Marked Pulmonary opacification with loss of diaphragmatic and Cardiac contour in a 28 wks. Preterm Neonate
- 2) Marked opacification of the lung field with maintained Cardiac and diaphragmatic silhouette
- 3) Classical granular appearance of RDS with obscuration of cardiac silhouette with bell shaped thorax due to under aeration

Neonatal pneumonia

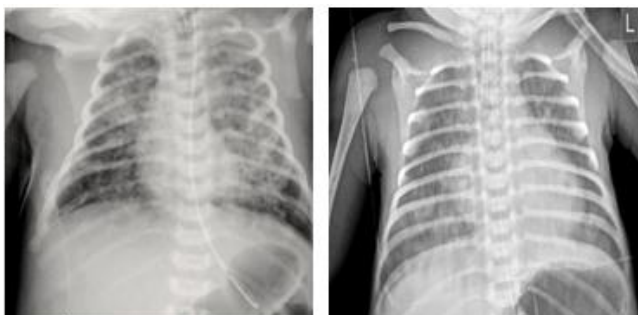

1

2

- 1) Neonatal pneumonia in a 33 wks preterm complicated by pneumothorax on right side.
- 2) AP film shows bilateral patchy opacities, more marked on right side. No effusions are seen.

Meconium Aspiration syndrome

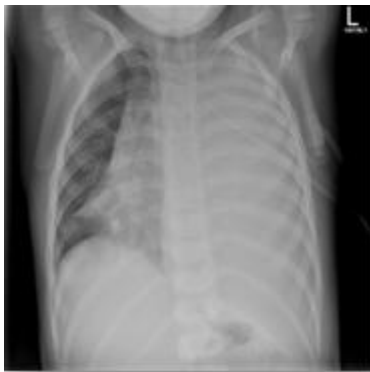

1

2

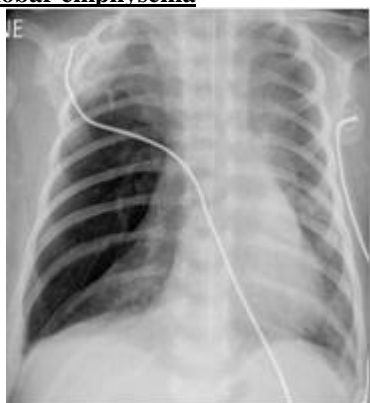1. Bilateral patchy asymmetrical areas of opacification in a Term neonate.
2. Coarse nodular shadowing with overinflation secondary to meconium aspiration in a post dated neonate.

Pleural Effusion



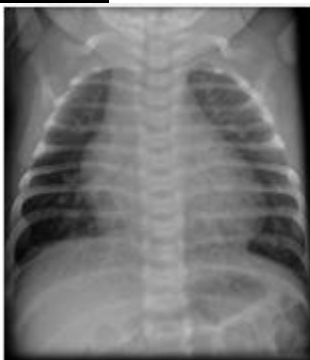Complete opacification of the left hemithorax with contralateral mediastinal shift consistent with a large effusion and limited underlying collapse.

Congenital lobar emphysema



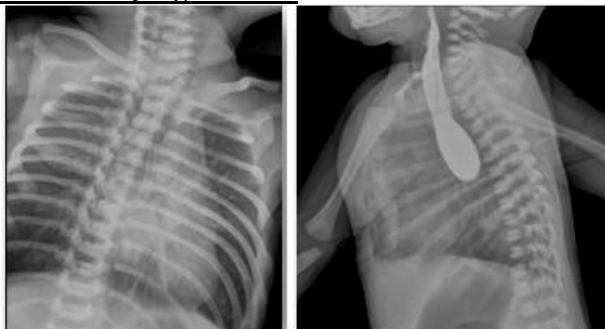Hyper expanded right middle lobe with compressive atelectasis of the right upper and lower lobes. There is contralateral mediastinal shift.

Congenital heart disease



There is mild cardiomegaly with congestive changes

Tracheo-oesophageal fistula

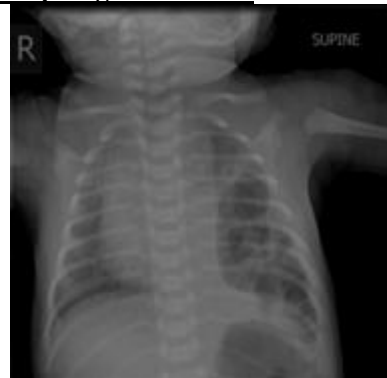

(1)

(2)

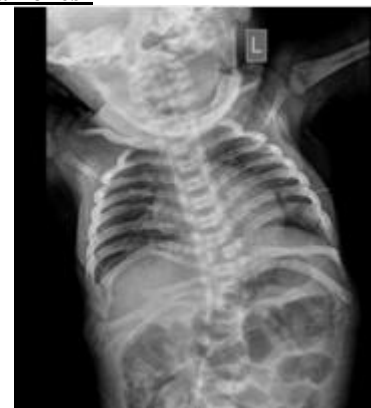- (1) Curling of Ryle's tube in esophagus can be seen .
- (2) On dye study Lateral radiograph shows contrast up to mid oesophagus without any contrast reaching Stomach

Congenital diaphragmatic hernia



Congenital diaphragmatic hernia with intestinal herniation into left hemithorax

Skeletal anomalies



Multiple segmentation anomalies seen involving cervical and thoracic region along with multiple rib abnormalities (crowding).

4. Results

- 1) In preterm (28-<32 weeks), 21% of neonates had pulmonary pathologies in which respiratory distress syndrome (62.5%) was most common
- 2) In preterm (32-36 weeks), 39.50% neonates had pulmonary pathologies in which transient tachypnoea of newborn (46.67%) was most common followed by pneumonia (26.67%)
- 3) In neonates >36weeks and post-dated neonates, 39.50% had pulmonary pathologies in which transient tachypnoea of new-born (26.67%) was common followed by meconium aspiration syndrome (20%) and congenital diaphragmatic hernia (13.33%).
- 4) Over all transient tachypnea of newborn (28.94%) was most common followed by respiratory distress syndrome(21.05%), pneumonia(15.79%) and meconium aspiration syndrome (7.9%), primary pulmonary hypertension(5.26%), congenital diaphragmatic hernia(5.26%), congenital heart disease(5.26%) and others (10.52%).

- 5) In 11 patients of transient tachypnea of newborn, the observed radiographic abnormalities were hyperinflation and prominent pulmonary interstitial markings (55.54% and 27.28% respectively). One chest radiograph was normal (9.09%).
- 6) In 8 patients of respiratory distress syndrome, the observed radiographic abnormalities were pulmonary opacification and reticulo-granular pattern (37.50% and 25% respectively).

Diagnosis	Total		Preterm	Preterm	Neonate of
	No	%	(28-<32 wks.)	(32-36 wks.)	(>36 wks.)
			No	No	No
Transient Tachypnea Of Newborn	11	28.94	0	7	4
Respiratory Distress Syndrome	8	21.05	5	3	0
Neonatal Pneumonia	6	15.78	0	4	2
Meconium Aspiration Syndrome	3	7.89	0	0	3
Primary Pulmonary Hypertension	2	5.26	2	0	0
Pleural Effusion	1	2.64	0	0	1

Diagnosis	Total		Preterm	Preterm	Neonate
	No	%	(28-<32 wks.)	(32-36 wks.)	(GA >36 wks.)
			No	No	No
Conenital Heart Disease	2	5.26	1	1	0
TOF / OESOPH. Atresia	1	2.64	0	0	1
Congenital Diaphragmatic Hernia	2	5.26	0	0	2
CCAM	0	0	0	0	0
Congenital Lobar Emphysema	1	2.64	0	0	1
Skeletal Anomalies	1	2.64	0	0	1
Cases	38		8	15	15
	(100%)		(21%)	(39.47%)	(39.47%)

Transient tachypnea of newborn

Radiographic findings	Number	Percentage
Hyperinflation	6	54.54
Prominent pulmonary markings	3	27.28
Prominent inter-lobar fissure	1	9.09
Normal	1	9.09
Total cases	11	100

Respiratory distress syndrome

Radiographic findings	Number	Percentage
Pulmonary opacification	3	37.5
Reticulo-granular pattern	2	25
Obscuration of cardiac silhouette	2	25
Pulmonary interstitial emphysema	1	12.5
Total	8	100

5. Conclusion

- 1) Chest radiography is essential in neonates with acute respiratory distress to exclude structural abnormalities such as congenital diaphragmatic hernia or congenital lobar emphysema.
- 2) One should remember that any sign of post-natal respiratory distress is an indication for radiograph of the chest which should be taken as early as possible.
- 3) In equivocal cases if we know the gestational age of newborn it can be of valuable help to reach to diagnosis.

References

[1] Guglani L, Ryan R, Lakshminrusimha S. Risk factors and management of transient tachypnea of the newborn. *Pediatric Health* 2009;3(3):251-260.

[2] Venkatesh V, Katzberg HD. Glucocorticoid regulation of epithelial sodium channel genes in human fetal lung. *Am J Physiol* 1997;273:L227.

[3] Jimenez E, Marin ML, Martin R, et al. Is meconium from healthy newborns actually sterile? *Res Microbiol* 2008;159 (3):187-193.

[4] Janssen DJ, Carnielli VP, Cogo P, et al. Surfactant phosphatidylcholine metabolism in neonates with meconium aspiration syndrome. *J Pediatr* 2006;149(5):634-9.

[5] Singh S, Clark RH, Powers RJ, et al. Meconium aspiration syndrome remains a significant problem in the NICU: Outcomes and treatment patterns in term neonates admitted for intensive care during a ten-year period. *J Perinatol* 2009;29(7):497-503.

[6] Agrons G, Courtney S, Stocker J, et al. From the Archives of the AFIP, Lung disease in premature neonates: Radiologic-pathologic correlation. *Radiographics* 2005;25(4):1047-1073.