

Prospective Study on Efficacy of Mastectomy Flap Quilting Sutures in Reducing Post Modified Radical Mastectomy Seroma Formation

Dr. Ashoka Chakravarthy.D¹, Dr. Balaji. M. K²

¹Assistant Professor, Department of General Surgery, Madurai Medical College, Madurai, India

²Post Graduate, Department of General Surgery, Madurai Medical College, Madurai, India

Abstract: *Aim and Objectives of the Study: To evaluate the efficacy of Mastectomy Flap Quilting Sutures in Reducing Post Modified Radical Mastectomy Seroma Formation. Materials and Methods: The size of sample work is 80 cases Patients with odd in-patient no underwent Modified Radical Mastectomy with conventional simple wound closure. Patient with even in-patient no. underwent Modified Radical Mastectomy with obliteration of dead space by Flap fixation. The patients were followed for three weeks in post-operative period, Day 1 drain volume, total drain volume, drain removal day, seroma and wound complication were all recorded. The results of the two groups were compared and analyzed by using Chi-square test. Results: The average total drain volume in the post-operative period in group A was 1426ml and 932ml in group B. p value was found to be significant (<0.001). The average day of drain removal in group A was 13 days and 8 days in group B. p value was found to be significant (<0.001). 8 patients developed seroma in group A vs none in group B. p value was found to be significant (>0.05). Conclusion: The present prospective study demonstrated that the mechanical obliteration of dead space by flap fixation significantly decreases the incidence of seroma formation.*

Keywords: Modified radical mastectomy; Seroma; Flap fixation

1. Introduction

Seroma formation and its sequelae including infection, flap necrosis, delayed wound healing and patient discomfort form one of most commonly encountered complication following mastectomy and axillary dissection varying in incidence from 3 to 85 %. Seroma formation after breast cancer surgery is a persistent problem much to the annoyance of surgeon and patient alike, in spite of advances in surgical techniques and hemostasis. Pathophysiology of seroma is not clear and it is widely discussed in literature. Seroma is formed by acute inflammatory exudates in response to surgical trauma and acute phase of wound healing or fibrinolytic activity in serum or lymph drainage. Seroma is influenced by large dissection area, dead space under the skin flaps and axillary region, shoulder movement which affects attachment of skin flaps.

Seroma accumulation elevates the flaps from the chest wall and axilla there by hampering their adherence to the tissue bed. It thus can lead to significant morbidity such as wound hematoma, delayed wound healing, wound infection, wound dehiscence, prolonged hospitalization, delayed recovery and initiation of adjuvant therapy.

Mechanical closure of dead space by flap fixation is a simple surgical procedure that eliminates dead space after mastectomy. The objective of this study is to evaluate the effect of mechanical closure of dead space after mastectomy in prevention of seroma formation.

2. Review of Literature

Different techniques have been employed to obliterate the dead space (under flaps and the axilla) to reduce seroma formation. Halsted first advocated creating a short superior

flap and suturing it with interrupted silk to the fascia below the first rib and skin grafting the remaining part of the defect. In 1951, Orr used tension sutures tied over rubber tubing bolsters to tack flaps to the chest wall.

In 1953, Keyes et al. used through and through sutures to attach the skin flaps to the chest wall. Besides these techniques, suturing of flaps with subcutaneous tissue, avoiding use of axillary drains following breast conservation therapy, and obliterating axillary dead space by muscle approximation have all been tried for reducing seroma formation. Coveney et al. compared suturing skin flaps to underlying muscle with conventional skin closure and observed a lower incidence of seroma formation in the flap suture group, although flap suturing did add to total operating time.

A recent randomized study compared a combination of skin flap suturing, ligation of lymphatics and obliteration of axillary dead space to conventional skin closure after mastectomy. As a result, the incidence of seroma formation decreased to 2% with the combination of techniques. Although effective, the authors stated that it was impossible to determine which of the three techniques, or any combination, actually produced the observed effect. Mechanical pressure has also been applied to obliterate dead space.

3. Methodology

3.1 Materials and Methods

The size of sample work is 80 cases. In group A, 42 women who underwent modified radical mastectomy had their wound closed in two layers – subcutaneous tissue with 2/0 vicryl and skin with 2/0 ethilon. In group B, 38 women who

underwent modified radical mastectomy had their wound closed by fixation of skin flap to underlying pectoralis major muscle with multiple rows of intermittent 2/0 vicryl followed by skin closure with 2/0 ethilon. In all the patients, 2 14F suction drain were kept in axilla and in front of pectoral muscles.

Drain volume on first post-operative day was recorded. Drain was removed when the output was less than 30ml for 24 hours. Total drain volume was recorded. The patients were followed for three weeks. The patients who developed seroma by clinical examination were recorded. Wound was observed for any complications like infection, cellulitis, and necrosis. In this study, the results of the two groups were compared and analyzed by using Chi-square test.

Inclusion Criteria

All the patients admitted in general surgical ward, aged more than 18 years with carcinoma breast requiring modified radical mastectomy. Patients consented for inclusion in the study according to the designated proforma.

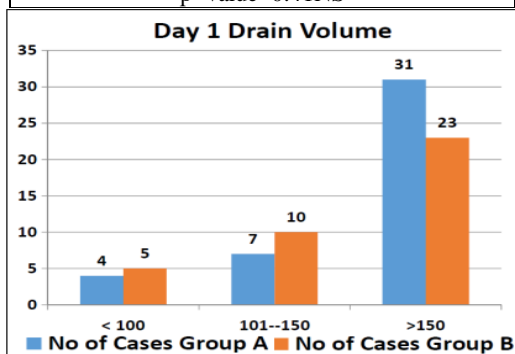
Exclusion Criteria

- 1) Patients with carcinoma breast undergoing breast conservation surgery
- 2) Patients with carcinoma breast undergoing radiotherapy
- 3) Patients with carcinoma breast undergoing modified radical mastectomy after neo-adjuvant chemotherapy
- 4) Patients with carcinoma breast undergoing palliative surgery/toilet mastectomy
- 5) Patients with carcinoma breast undergoing completion mastectomy
- 6) Patients not consented for inclusion in the study

4. Results

In the present study, the drain volume in first post-operative day in Group A (Flap Non Fixation) was compared with Group B (Flap Fixation) after Modified radical mastectomy. Drain volume in first post-operative day varied from 100 to 200ml with average of 170 ml in group A and 163 ml in group B. There was no statistically significant difference in the drain volume in first post-operative day (p>0.05).

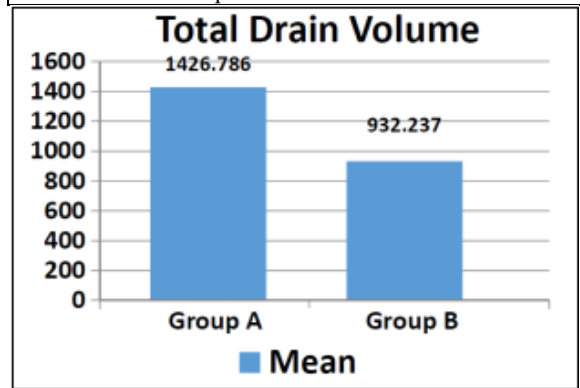
Day1 Drain Volume(ml)	No. of Patients		Total
	GroupA	GroupB	
<100	4	5	9
100-150	7	10	17
>150	31	23	54
Mean Volume(ml)	170.2	163.8	
p' value=0.41NS			



Total Drain Volume

The average total drain volume in the post-operative period in group A was 1426 ml and 932ml in group B. p value was found to be significant(<0.001)

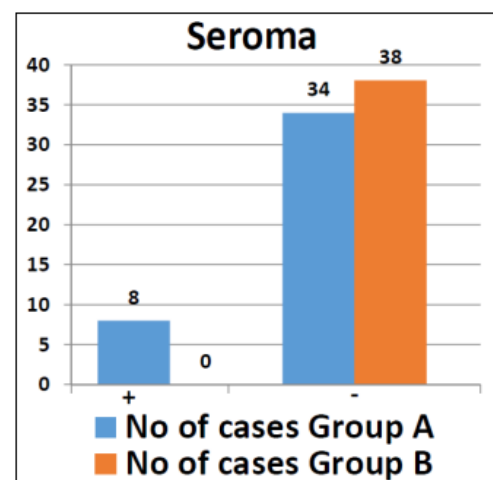
	Mean Total Volume (ml)	SD
Group A	1426	240
Group B	932	216
p' value<0.001S		



Incidence of Seroma

8 patients developed seroma in group A vs none in group B. P value was found to be significant (<0.05).

Seroma	GroupA	GroupB	Total
Present	8	0	8
Absent	34	38	72
p' value=0.027S			



Incidence of Wound Complications

One patient developed wound complication (cellulitis) vs none in group B. There was no statistically significant difference in the incidence of wound complications in both groups.

Wound Complications	Group A	Group B	Total
Present	1	0	1
Absent	41	38	79
p' value=0.95NS			

5. Conclusion

In the present study, 80 women have completed the study protocol. Of this 42 women in groupA (Flap non fixation)

and 38 women in group B (Flap fixation) underwent modified radical mastectomy. After analyzing the data and observations, the present prospective study demonstrated that the mechanical obliteration of dead space by flap fixation significantly decreases the incidence of seroma formation.

However, the sample size in the current study is relatively smaller, so a larger study sample may be needed before any further conclusion can be made. Although the study sample is small in this present study, it is still wise to recommend mechanical obliteration of dead space by flap fixation in patients undergoing modified radical mastectomy.

So when performing modified radical mastectomy, the flap-fixation technique is a valuable technique for reducing seroma formation allowing early drain removal and increased patient satisfaction.

References

- [1] Kumar S, Lal B, Misra MC. Post-mastectomy seroma: a new look into the aetiology of an old problem. *J R Coll Surg Edinb.* 1995;40:292-294.
- [2] Bryant M, Baum M. Postoperative seroma following mastectomy and axillary dissection. *Br J Surg.* 1987;74:1187
- [3] Willett WC, Rockhill B, Hankinson SE, Hunter DJ, Colditz GA. Epidemiology and nongenetic causes of breast cancer. In: Harris JR, Lippman ME, Morrow M, Osborne CK, editors. *Diseases of the Breast.* 2nd ed. Philadelphia: Lippincott Williams & Wilkins; 2000. pp. 175–220.
- [4] Watt-Boolsen S, Nielsen VB, Jensen J, Bak S. Postmastectomy seroma. A study of the nature and origin of seroma after mastectomy. *Dan Med Bull.* 1989;36:487–489.
- [5] Oertli D, Laffer U, Habermeyer F, Kreuter U, Harder F. Perioperative and postoperative tranexamic acid reduces the local wound complication rate after surgery for breast cancer. *Br J Surg.* 1994;81:856–859.
- [6] Fischer's mastery of Surgery, sixth edition, Lippincott Williams & Wilkins, 2012.
- [7] Halsted WS. The results of operations for the cure of cancer of the breast performed at the Johns Hopkins Hospital from June 1889 to January 1894. *Arch Surg.* 1894;20:497.
- [8] Meyer W. An improved method for the radical operation for carcinoma of the breast. *Med Rec NY.* 1894;46:746.
- [9] Bland KI, Chang HR, Prati R, et al. Modified radical mastectomy and total (simple) mastectomy. In: Bland KI, Copeland EM, eds. *The Breast: Comprehensive Management of Benign and Malignant Diseases.*
- [10] Bland KI, Menck HR, Scott-Conner CE, et al. The National Cancer Data
- [11] Base 10-year survey of breast carcinoma treatment at hospitals in the United States. *Cancer* 1998;83(6): 1262-73.
- [12] Nahabedian, Maurice Oncoplastic surgery of the breast 618.1'90592
- [13] Fisher B, Anderson S, Bryant J, et al. Twenty-year follow-up of a randomized trial comparing total

mastectomy, lumpectomy, and lumpectomy plus irradiation for the treatment of invasive breast cancer *N Engl J Med* 2002;347

Author Profile



Ashoka Chakravarthi .D completed his M.B.B.S from Coimbatore Medical College in 1998. He completed his M.S General Surgery from Madurai Medical College in 2007. He is Assistant professor of surgery in Madurai Medical College For 11 Years.