

An Interesting Case of Fraser's Syndrome with Cryptophthalmos in a New Born Child

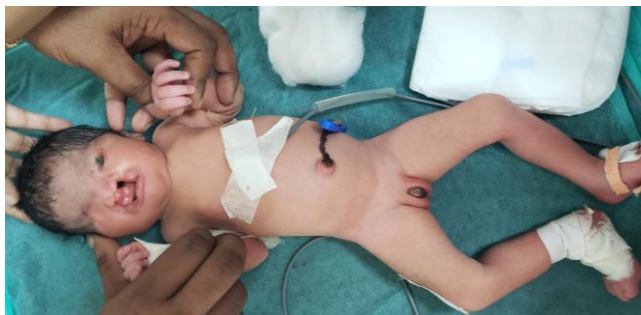M. Dinesh, M. Parni Kumar, G. Harshitha

1. Introduction

Cryptophthalmos in association with Fraser's syndrome was first described in 1872 by Zehender and Manz¹. Cryptophthalmos is derived from greek word "Kryptos" means hidden or secret. Cryptophthalmos refers to a rare failure of eyelid fold formation which results in fused eyelids². Cryptophthalmos may be complete characterised by smooth fold of skin that completely covers the eyeball and seen to extend from forehead on to the cheek or it may be partial where some areas of normal lid can be identified. Cryptophthalmos may occur in isolation, but also occur in association with other congenital anomalies like Fraser's syndrome. This is a rare case report of one eye Cryptophthalmos with other eye absent upper lid.

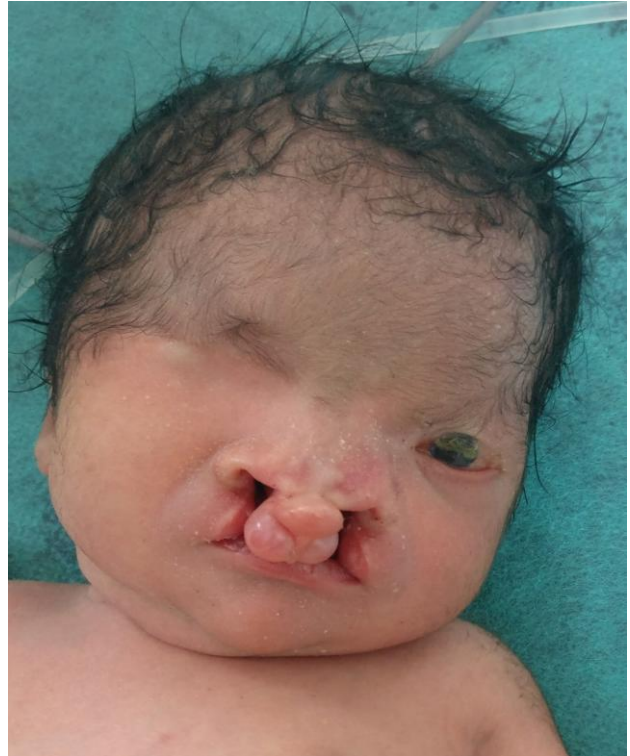
2. Case Report

A 4 hour old female baby who is a third offspring to their parents presented with absence of upper eyelid of left eye and right eyeball not visible since birth. history of consanguineous marriage present, parents are second degree relatives, mothers age is 24 yrs. Baby was delivered by caesarean section at Government General hospital, Guntur.



Baby was preterm, 2200gm birth weight and cried immediately after birth. Family history of first male child was stillborn with multiple anomalies. The second male child is 3yr old and apparently normal and healthy

On examination right eye complete cryptophthalmos, eyeball not visible. left eye absent upper eyelid. Microtia (under development of external ear) of both sides, cleft lip with cleft palate, absence of nasal bridge noted. There are no limb deformities, external genitalia appear to be normal and all external orifices are patent.



On ocular examination both eyebrows appear to be normal, right eye eyelids fused together with absent eyelashes. Left eye upper eyelid is absent and eye lashes are under developed, cornea is hazy (due to exposure keratopathy) and iris and pupil are not visible. Size of the cornea and the eyeball appear to be normal.

3. Discussion

Fraser's syndrome is a rare autosomal recessive congenital disorder with cryptophthalmos, syndactyly, genital malformations, congenital malformations of nose, ears and larynx and imperforate anus.¹

Diagnostic criteria for Fraser's syndrome:

Major criteria:

- Cryptophthalmos
- Syndactyly
- Abnormal genitalia
- Sibling with Fraser's syndrome

Minor criteria:

- Congenital malformation of nose
- Congenital malformation of ears
- Congenital malformation of larynx
- Cleft lip +/- palate

Volume 8 Issue 3, March 2019

www.ijsr.net

Licensed Under Creative Commons Attribution CC BY

- Skeletal defects
- Umbilical hernia
- Renal agenesis
- Mental retardation

[3] Fraser syndrome – A case report, by begum sharifun
naher, Bangladesh j child health 2014 vol 38 (2)

2 major and one minor criteria (or) 1 major and 4 minor criteria are required for the diagnosis of Fraser's syndrome. In our case there are cryptophthalmos, sibling with Fraser's syndrome as 2 major criteria and congenital malformation of nose, cleft lip with palate as 2 minor criteria.

Fraser's syndrome is autosomal recessive inherited syndrome; consanguinity of marriage is reported in 15 – 24.8% of cases. 25% of fetuses affected are still born and mental retardation is seen in 80% of survivors.³

Genes of Fraser's syndrome are FRAS1 Gene which is involved in epithelial morphogenesis during early development, FREM2 or GRIP1 genes.

Prenatal ultrasonography is suggested in making diagnosis of Fraser's syndrome. Genetic counselling should be based on increasing probability of occurrence, antenatal diagnosis in next pregnancy using ultrasonography and medical termination of pregnancy of the affected foetus.

The underlying globe is usually microphthalmos and anterior segment is markedly disorganised. Posterior segment is usually preserved. Treatment is aimed at functional and cosmetic restoration of lids but is difficult and unsatisfactory. In our case there is absence left eye upper lid. Congenital coloboma may range from small defect to almost complete absence of the lid. Small defects upto one third can be managed by direct closure. Moderate sized defects (1/3rd to 2/3rd) managed by either direct closure aided with lateral canthotomy or Tenzel's semi-circular flap. Larger defects may need procedures like Cutler beard even though there is a possibility of inducing iatrogenic sensory deprivation amblyopia.

4. Conclusion

Treatment of Fraser's syndrome may include surgery to correct some of the malformations associated with this disorder. Guarded visual prognosis is explained to the parents in both eyes. In view of poor surgical outcome in case of complete cryptophthalmos of the right eye and also in the left eye. Palliative treatment is advised to the left eye to save the left eye. Visual outcome, the benefits and risk of surgical procedure are discussed with consultant paediatrician and prognosis explained to the parents. Genetic counselling is done to the parents.

References

[1] Fraser syndrome and cryptophthalmos: review of the diagnostic criteria and evidence for phenotypic modules in complex malformation syndromes by A M Slavotinek, C J Tiffet, journal of medical genetics 2009 volume vol 39 issue 9.

[2] zia chaudhari 1 st edition vol 2