

# A Rare Case of Pneumonia Evolving into Atypical Haemolytic Uremic Syndrome

Rishikesh Dessai<sup>1</sup>, Vinus Taneja<sup>2</sup>, Manishi Nauteyal<sup>3</sup>, Ambuj Garg<sup>4</sup>

Department of Medicine, Sir Ganga Ram Hospital, Delhi, India

**Abstract:** A typical hemolytic uremic syndrome (aHUS) is a rare disease characterised by non-immune hemolytic anaemia, thrombocytopenia and acute kidney injury. It results from chronic, uncontrolled activation of the alternative complement pathway, leading to thrombotic microangiopathy (TMA). Renal impairment and progression to end-stage renal disease are common in untreated patients with aHUS. We report a case of 60-year old who was initially treated for pneumonia and acute kidney injury and was later diagnosed with atypical haemolytic anaemia based on clinical and lab parameters. The patient was successfully treated by plasma exchange which is the treatment of choice for HUS.

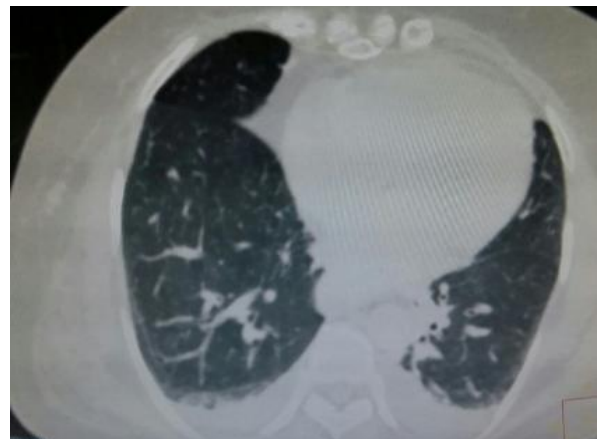**Keywords:** Atypical hemolytic uremic syndrome, aHUS, thrombotic microangiopathy, TMA

## 1. Introduction

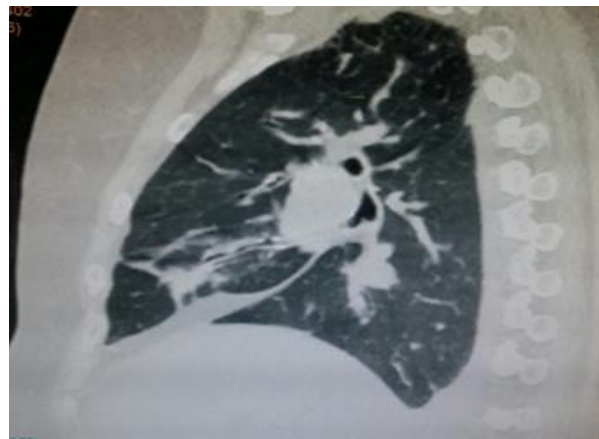
Atypical haemolytic uremic syndrome (aHUS) is a thrombotic microangiopathy caused by complement dysregulation. Mutations in genes encoding complement regulatory proteins are identified in 50% of cases. Recently, autoantibodies targeting complement factor H (CFH-ab) have been defined as a new cause of aHUS that affects young individuals. aHUS may also be triggered by infections like streptococcus pneumoniae and human immunodeficiency viral infection, drug toxicity, pregnancy or autoimmune disorders like SLE. Usually there is an underlying genetic predisposition that gets unmasked with stress responses which is respiratory infection in our case.

## 2. Case Report

A 60 year old female with no known comorbidities presented to our hospital with fever, cough with expectoration and decreased urine output. Positive findings on systemic examination were bilateral crepitation and rhonchi. SpO<sub>2</sub> was 92% on room air. Laboratory evaluation revealed Haemoglobin: 10.1g/dl, TLC: 52.9/mcl, platelets:11,000/mcl, ESR: 45mm /1<sup>st</sup> hour, peripheral blood smear revealed neutrophilic leukocytosis, RBCs showing schistocytosis, schistocyte index 4.5%, fragmented cells:2%, serum creatinine:5.70mg/dl, BUN:100mg/dl, Na/K:128/5.65meq/l, Total bilirubin: 2.67mg/dl, Direct bilirubin: 1.00mg/dl, Urine r/e revealed 15-20 RBCs(hematuria), 5-10 WBCs, 1+ proteinuria(30mg/dl), 24 hr urine protein:153mg, Urine culture revealed Candida albicans 1,00,000 colony count, IAT/DAT(indirect/direct Coombs test) were negative, ANA and ANA profile negative, Reticulocyte count was 1.6% (Corrected: 0.9%), IPF: 6.9%, Fibrinogen: 2.69g/l, Anti c ANCA, pANCA negative, low C3: 953(1032-1495), normal C4:238 (167-385), Anaemia profile revealed iron: 30mcg/dl, ferritin:290ng/ml, folic acid>20ng/ml, vitamin B12>1500pg/ml, LDH: 1109 IU/l. NCCT thorax showed bilateral mild pleural effusion with basal consolidation, subsegmental consolidation in the right middle lobe.



**Figure 1:** NCCT chest axial view showing bilateral pleural effusion with basal consolidation.



**Figure 2:** NCCT chest sagittal view showing subsegmental consolidation in the right middle lobe

Atypical HUS was diagnosed based on clinical and laboratory findings and patient was managed by plasmapheresis, multiple units of PRBCs and PRPs. Haemodialysis was done in view of acidosis and anuria. Post plasma exchange serum LDH reduced to 259IU/l, platelets increased to 2,37,00/mcl and serum creatinine decreased from 5.70mg/dl to 2.84mg/dl. With intravenous antibiotics, TLC normalised to 7,300/mcl.

### 3. Discussion

Atypical HUS is characterised by a triad of microangiopathic haemolytic anaemia that is diagnosed by elevated LDH, low haptoglobin, schistocytes, normal IAT, DAT plus thrombocytopenia plus acute kidney injury. Male-to-female ratio is equal in children but it is more common in adult females. It can be divided into 2 broad categories: typical (or otherwise D+HUS) and aHUS. D+HUS is more common in children and usually preceded by a history of diarrhea. aHUS can be divided into idiopathic and secondary forms. The pathogenesis of idiopathic aHUS involves activation of the complement system. Genetic aberration in 1 of the proteins of the alternative complement pathway can be found in at least 50% of idiopathic aHUS patients. Genetic aberrations, however, are not the sole cause of complement activation in aHUS. An environmental factor, such as a complement trigger, is probably needed to develop the disease. Tumors associated with aHUS, include breast and colon carcinomas, gastric adenocarcinoma, and small cell lung carcinoma. It can also occur with ovarian cancer, prostate cancer, lymphoma, pancreatic cancer, and, very rarely, leukemias. It is also seen in cobalamin metabolism disorders, pregnancy (especially eclampsia), autoimmune diseases, drugs (e.g., quinine, mitomycin, cisplatin, bleomycin, tacrolimus, cyclosporine, clopidogrel, ticlopidine), and infections with *Streptococcus pneumoniae* and other microorganisms (varicella, influenza, HIV, pertussis). The genetic predisposition is deficiency/ point mutations of complement regulator proteins: Factor H, Factor I and MCP or autoantibodies to Factor H or gain of function mutation of Factors B/C3. First line of management is plasmapheresis which replaces deficient factors and eliminates autoantibodies. A retrospective study done by Noris et al in 2011 showed that plasma treatment induced complete/partial remission of 63, 25 and 75% of episodes in patients with deficiency of CFH, CFI or anti-CFH autoantibodies, respectively. FDA in 2011 has approved Eculizumab (humanized recombinant immunoglobulin G2/4 monoclonal antibody against complement factor C5) for the management of aHUS. Eculizumab inhibits the generation of a membrane attack complex (MAC):C5b-9, and hence inhibits the complement system but the risk associated with the drug is infection with encapsulated bacteria like *Neisseria meningitidis* as it blocks the terminal complement component. Therefore, patients must receive meningococcal vaccination prior to initiating the drug therapy if physicians cannot wait for immunity to develop. It can be used as a preventive therapy in patients at risk of recurrences, however the cost of the medication creates barriers to treatment. Persistence of hemolysis or lack of improvement in renal function after 3-5 daily plasma exchanges has been regarded as a criterion for uncontrolled TMA and is an indication for initiating eculizumab.

### 4. Conclusion

A typical HUS triggered by pneumonia is an uncommon condition in our country. Stress in the form of infection/malignancy/ use of immunosuppressant/ chemotherapeutic agents in a genetically predisposed person triggers microangiopathic haemolytic anaemia, platelet destruction

and acute kidney injury. Clinical and laboratory parameters are important in making the final diagnosis. Plasmapheresis is the first line of management. Our patient showed drastic improvement in her laboratory parameters after plasmapheresis along with haemodialysis, PRBC infusions and treatment of pneumonia with i/v antibiotics. So, the most important step in treating aHUS is early diagnosis and initiation of plasmapheresis, identifying the trigger wherever possible and timely treating the same for better outcome.

### References

- [1] Barbour T, Johnson S, Cohn S, et al.(2012) Thrombotic microangiopathy and associated renal disorders. *Nephrol Dial Transplant.*; 27:2673-2685.
- [2] Benz K, Amann K. (2010) Thrombotic microangiopathy: new insights 242.
- [3] Dragon-Durey MA, Loirat C, Cloarec S, et al. (2005) Anti-factor H autoantibodies associated with atypical hemolytic uremic syndrome, *J Am Soc Nephrol.*;16:555-563.
- [4] Fremeaux-Bacchi V, Miller EC, Liszewski MK, et al. (2008) Mutations in complement C3 predispose to development of atypical hemolytic uremic syndrome. *Blood.*;112:4948-4952.
- [5] Gordon LI, Kwaan HC.(1994) Thrombotic microangiopathy manifesting as thrombotic thrombocytopenic purpura/hemolytic uremic syndrome in the cancer patient. *Semin Thromb Hemost.* 25(2):217–21.
- [6] Goicoechea de Jorge E, Harris CL, Esparza-Gordillo J et al. (2007) Gain-of-function mutations in complement factor B are associated with atypical hemolytic uremic syndrome, *Proc Natl Acad Sci USA* 240-245.
- [7] Jozsi M, Licht C, Strobel S, et al.( 2008) Factor H autoantibodies in atypical hemolytic uremic syndrome correlate with CFHR1/CFHR3 deficiency, *Blood.*;111:1512-1514.
- [8] Loirat C, Fremeaux-Bacchi V. (2008) Hemolytic uremic syndrome recurrence after renal transplantation, *Pediatr Transplant.*619-629.
- [9] Neild G. (1994) Haemolytic uremic syndrome in practice. *Lancet.*398-401.
- [10] Noris M, Remuzzi G.(2005) Hemolytic uremic syndrome. *J Am Soc Nephrol.* 16:1035–50.
- [11] Noris M, Caprioli J, Bresin E, Chiara Mossali, et al. (2010) Relative Role of Genetic Complement Abnormalities in Sporadic and Familial aHUS and Their Impact on Clinical Phenotype. *Clin J Am Soc Nephrol.* 1844–1859.
- [12] Noris M, Remuzzi G (2009) Atypical hemolytic-uremic syndrome, *N Engl J Med.* 361.
- [13] Rafiq A, Tariq H, Naeem Abbas, et al. (2015) Atypical Hemolytic-Uremic Syndrome: A Case Report and Literature Review. *Am J Case Rep.*109–114.
- [14] Sawai T, Nangaku M, Ashida A, et al.(2014) Diagnostic criteria for atypical hemolytic uremic syndrome proposed by the Joint Committee of the Japanese Society of Nephrology and the Japan Pediatric Society. *Clin Exp Nephrol.*18:4–9.

- [15] Sherka C, Jozsi M, Zipfel P, et al. (2009) Autoantibodies in haemolytic uraemic syndrome (HUS), *Thromb Haemost* ;101:227-232.
- [16] Thajudeen B, Sussman A, Bracamonte E.(2013) A Case of Atypical Hemolytic Uremic Syndrome Successfully Treated with Eculizumab. *Case Rep Nephrol Urol*.139-146.
- [17] Zipfel PF, Heinen S, Skerka C. (2010) Thrombotic microangiopathies; new insights and new challenges *Curr Opin Nephrol Hypertens*. 372–378.