

A Rare Case Study of Testicular Teratoma Cancer in Young Male Patient

Dr. Rashmi Anil Kale¹, Dr. Jayshri Karpe²

¹Professor and HOD of Shalyatantra, Department of Shalyatantra, Sumatibhai Shah Ayurveda Mahavidyalaya, Hadapsar, Pune-28, Maharashtra, India

E-mail id-drrakale[at]gmail.com

²Senior Resident & Post Graduate Final Year Student, Department of Shalyatantra, Sumatibhai Shah Ayurveda Mahavidyalaya, Hadapsar, Pune-28, Maharashtra, India

E-mail id-karpejayshri102[at]gmail.com

Abstract: A testicular tumour more commonly referred as teratoma of testicular cancer, teratoma arises from totipotent cells in the rete testis and often contains a variety of cell types. This is the most common form of testicular tumour in the adults and the highest incidence is between 25 & 35 yrs. of age, they almost never occur in infancy. Testicular tumours, accounts for 1% of all malignant tumours; 99% of testicular tumours are malignant. Its predisposing factors are undescended testis, Klinefelter's syndrome, testicular atrophy and also associated with Cryptorchidism. In the reported case, there was no history of previous illness but shows huge swelling at right side testes and right inguinal lymph nodes were enlarged, no resolution of swelling or no improvement of the clinical picture of the patient was observed after trial of conservative management. An operative intervention was decided and operated specimen was sent for HPE.

Keywords: Testis, Teratoma, Orchiectomy, *Arbud*.

1. Introduction

A teratoma arises from totipotent cells in the rete testis and often contains a variety of cell types.¹it's accounts for 1% of all malignant tumours;99% of testicular tumours are malignant.²This is the most common form of testicular tumour in the adult, the highest incidence is between 25 and 35 yrs. of age.³Cryptorchidism is a predisposing condition and other associations includes atypical germ cells and multiple nevi.⁴They almost never occur in infancy.⁵Malignant teratomatous tumours spreads predominantly by blood and also lymphatic spread through para-aortic node, left supraclavicular node, iliac node⁶. Testicular teratoma presenting complaints of a sensation of heaviness but minimal pain is present, anorexia, fever (on and off), weight loss, an enlarged supraclavicular node is the presenting sign of a testicular tumour. Hepatic enlargement, lung metastases are usually silent but can cause chest pain, dyspnoea and haemoptysis⁷. Secondary hydrocele is common, cremaster is hypertrophied and thickened, vas, prostate and seminal vesicle are normal and altered breath sounds and pleural effusion occasionally acute epididymo-orchitis or acute haematocele, bone pain⁸.

Malignant tumour stages –

- 1) Testes lesion only –no spread
- 2) Nodes below the diaphragm only
- 3) Nodes above the diaphragm
- 4) Pulmonary / hepatic metastases.⁹

Malignant tumours investigating by blood sample for HCG (human chorionic gonadotropin hormone), α -fetoprotein, LDH (Lactate dehydrogenase), USG (A+P), CT (A+P), MRI (A+P)- for detecting secondaries and for monitoring the response to therapy.¹⁰Orchiectomy is essential to remove the primary tumour and to obtain histology and later on give chemotherapy and patients

prognosis up to 5 yrs. Survival rate of more than 85% is achieved.¹¹

In Ayurvedasamhita, '*Arbud*' reference came in '*Sushrut Nidansthan-Adhyaya-13*' quote that vitiated Vatadi dosh gets aggravated and affects mamnsa, Rakta, Kapha, medodhatu and become localised in the skin, makes it thick (swollen), pain may or may not be present.¹²'*Medoarbud*' reference came in '*Sushrut Sutrasthan- Adhyaya-24-Vyadhisamuddheshiy*' and came in category of *Adibalpraruttaj-KulajVyadhi* with *Medojdusthi*.¹³ and also according to modern science Teratoma of Testicular cells arises from totipotent stem cells i.e. ecto, meso, endoderms.¹⁴

2. Case Presentation

A 30 year old male presented with complaints of right scrotal swelling since 1-2 month, history of weight loss by 5 kg and recently complicated by local hyperaemia & pain. Patient had H/O- right side inguinal hernioplasty one year ago with no medical illness present and habitual history of alcohol consumption and tobacco chewing since 5-6 yrs.

On clinical examination, patient was stable with P-74/min, BP-110/70 mm of hg and finding shows there was non-specific a huge swelling approx. 10/15 cm, hard in consistency, intensively painful on palpation, irregular margins, right side inguinal lymph node was palpable but another lymph node was non-palpable, on rectal examination, rectum was partially loaded, no any external or internal growth felt. Patient was resuscitated with IV line using crystalloids, antibiotics for 3 days conservative treatment given.

Laboratory investigations showed further signs of inflammation with white cell count of 308×10^3 /UI, a high

Volume 9 Issue 10, October 2020

www.ijsr.net

Licensed Under Creative Commons Attribution CC BY

ESR 52 mm/hr, HB-12gm%, plt-308×10³/UI, Renal function were normal and α -feto protein 836.40ng/ml (<8.5ng/ml), serum LDH level 1858IU/ LT (normal -250-450IU/LT), β -HCG 3,50,600 MIU/ML(non- pregnant F- not detected to 5.30), ultrasonography of abdomen (12/9/2019) was done which revealed well defined heterogeneous lesion of size 88×82 mm, no e/o- vascularity, likely matted necrotic lymph node in right inguinal region of approx. size 50×30mm.CT-SCAN (A+P) on 14/9/2019 iv contrast done. A large heterogeneously enhancing soft tissue density lesion measuring (9.5×9.7×12.9cm) was seen within the scrotal sac inseparable from the rete testes suggestive of malignant neoplastic etiology of the testes and lesion was seen within both the lobes of Liver within segment VI (2.4 ×1.8 ×2.3cm), and also lesion in the right upper retro peritoneum with extension on left side, represented metastatic necrotic nodal masses causing infra hepatic IVC occlusion, right external iliac & right common femoral necrotic lymph node (2.4×5.1×3.6cm), nodules within lung base suggestive of metastasis on right side (1× 1.3× 1.1cm),and left side (1.5 ×1.7× 1.2cm)

High level right side orchidectomy with right inguinal lymph node excision was done on 16/9/2019, and findings shows right side testes of approx. size 10×7cm, irregular margins, enlarged, matted lymph node on right side approx. 3×2cm and sample send for HPE and reports was Excised right inguinal lymph node(24/9/2019) –metastatic deposits of non seminomatous germ cell tumour, consistent with deposits of choriocarcinoma and embryonal carcinoma,size of the metastatic lymph node -4×3×2cm,perinodal extension is not seen, right orchidectomy-non seminomatous mixed germ cell tumour, immature teratoma-80%, choriocarcinoma-15%, Embryonal carcinoma-5%, predominantly necrotic tumour showing extensive areas of haemorrhage, tumour abuts the tunica albuginea, lymphovascular emboli-seen, perineural invasion –not seen, A rt inguinal lymph node shows metastatic deposits of choriocarcinoma and embryonal carcinoma,size of metastatic lymph node-4×3×2cm, perinodal extension is not seen, pathologic stage –pT2N2MX. Post-operative period was uneventful. Patient was discharged on 7th post-operative day and for further chemotherapy treatment.

3. Discussion

Patient history suggests Testicular malignancy development although there is no association between cryptorchidism and

Testicular malignancy, the condition was surgically corrected if treated early. In Ayurveda, Malignant tumour called as "GHATAKTUMOUR", is a rounded(*vrutta*), fixed(*sthira*),huge(*mahaantam*)swelling,painless(*mandruja*),involvement of all Dhatus (*analpamulam*), increases in different stages (*chirrudhhi*), absence of fluctuation (*apakam*), *Gaun Aarbud or Durarbud or Adhyarbud* (Metastatic growths or secondary deposits),¹⁵ In '*Raktaarbud* 'due to "*Mityaahar-Vihar*" vitiated vatadidosha goes into compound and formation of huge, painless, instant, fluctuating swelling or bloody discharge present. '*Raktaarbud* ' is a '*AsadhyaVyadhi*' does not cure by treatment.¹⁶

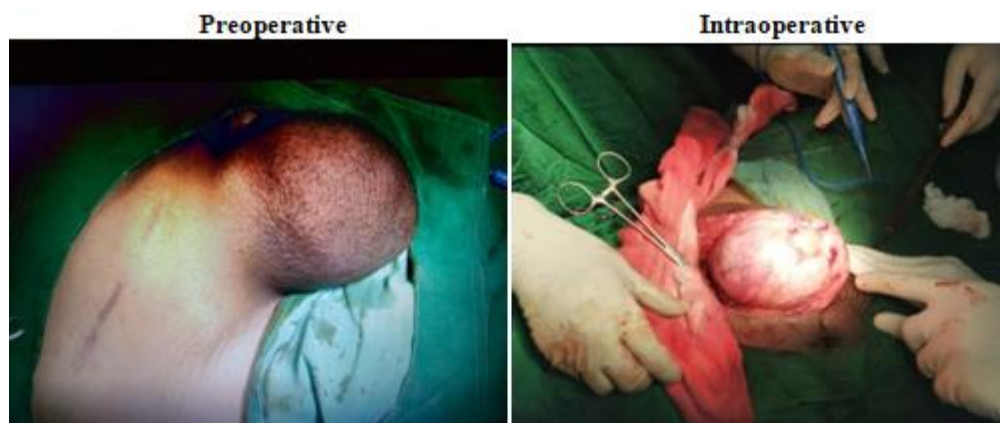In '*Mamnsaarbud*' due to '*Musthiprahara*' painless, fixed, rounded,indurated and hard swelling occurs at '*Musthiprahar*' site. '*Mamnsaarbud*' is also a '*AsadhyaVyadhi*' .¹⁷

4. Conclusion

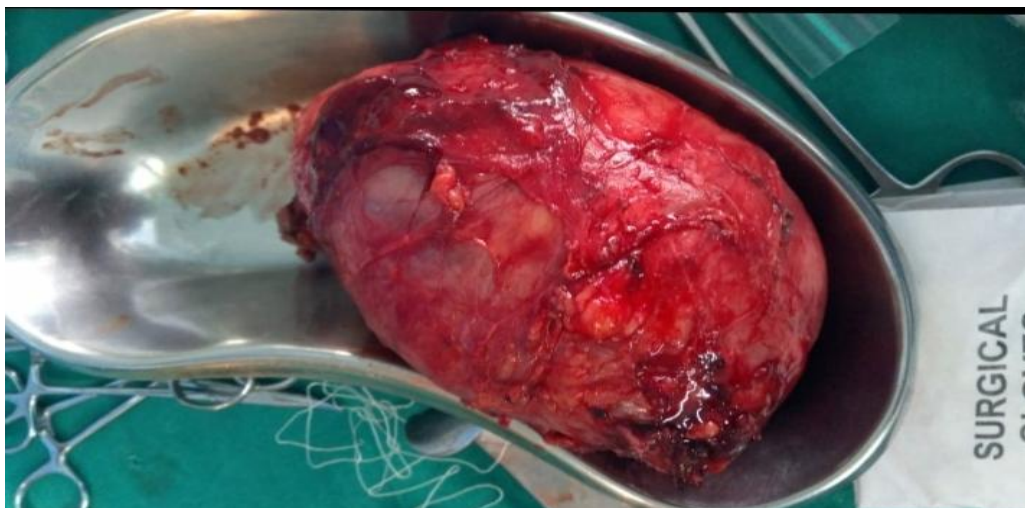
Although rare, Testicular tumour should be considered in all male patients presenting with acute scrotal swelling, measures for the increase of patients awareness regarding genital pathology should be taken in order to lower the period between the onset of symptoms and Hospital presentation.

In above case surgical removal of testes and rt inguinal lymph node was carried out and F/U was taken up to H/E reports was –metastatic deposits of non seminomatous germ cell tumour, consistent with deposits of choriocarcinoma and embryonal carcinoma, size of the metastatic lymph node -4×3×2cm, perinodal extension is not seen, rt orchidectomy-non seminomatous mixed germ cell tumour, immature teratoma-80%,choriocarcinoma-15%, Embryonal carcinoma-5%, predominantly necrotic tumour showing extensive areas of haemorrhage, tumor abuts the tunica albuginea, lymphovascular emboli-seen, perineural invasion –not seen, A rt inguinal lymph node shows metastatic deposits of choriocarcinoma and embryonal carcinoma, size of metastatic lymph node-4×3×2cm,perinodal extension is not seen, pathologic stage –pT2N2MX.

5. Photos



Post-operative



References

- [1] Bailey & Love's R.C.G.RUSSELL NORMAN S. WILLIAMS & CHRISTOPHER J.K.WILLIAMS & CHRISTOPHER J.K.BULSTRODE, short practice of surgery 24th edition international student's edition 2004 ;Hodder Education , a member of the Hodder Headline Group;ISBN-10:0340808195;pg.no.1385.
- [2] Shriram Bhat M;M.S.(General surgery); clinical methods in surgery 3th edition 2019;jaypee brothers medical publishers(p)ltd;ISBN 978- 93-5270-545-0;pg.no.436.
- [3] S.Das;MBBS,FRCS;A Concise textbook of Surgery 8th edition jan 2014;published by Dr.s.das;ISBN-978-81-905681-2-8;pg.no.1327.
- [4] Frederick L,Greene,M.D.David L. Page,M.D.AJCC cancer staging handbook 6TH edition 2005;published by Springer(india)Private Limited,ISBN-81-8128-286-8 pg.no.347.
- [5] S.Das;MBBS,FRCS;A Concise textbook of Surgery 8th edition jan 2014;published by Dr.s.das;ISBN-978-81-905681-2-8;pg.no.1287.
- [6] K Rajgopal Shenoy MBBS, M.S., Anita Shenoy; MBBS, M.D. FRCA, Manipal Manual of Surgery 4th edition;CBS Publishers pvt Ltd;ISBN-978-81-239-2416-8 pg.no.996.
- [7] Bailey & Love's R.C.G.RUSSELL NORMAN S. WILLIAMS & CHRISTOPHER J.K.WILLIAMS & CHRISTOPHER J.K.BULSTRODE, short practice of surgery 24th edition international student's edition 2004 ;Hodder Education ,a member of the Hodder Headline Group;ISBN-10:0340808195;pg.no.1386.
- [8] Makhan Lal Saha,MBBS,M.S.(surgery)FMAS FAIS;Bedside Clinics in Surgery ,3rd edition;published by JAYPEE The Health Sciences;ISBN-pg.no.1071,1072.
- [9] Bailey & Love's Bailey & Love's R.C.G.RUSSELL NORMAN S. WILLIAMS & CHRISTOPHER J.K.WILLIAMS & CHRISTOPHER J. K. BULSTRODE, short practice of surgery 24th edition international student's edition 2004 ;Hodder Education, a member of the Hodder Headline Group; ISBN-10:0340808195;pg.no.1387.
- [10] Bailey & Love's R.C.G.RUSSELL NORMAN S. WILLIAMS & CHRISTOPHER J.K.WILLIAMS & CHRISTOPHER J.K.BULSTRODE, short practice of surgery 24th edition international student's edition 2004 ;Hodder Education ,a member of the Hodder Headline Group;ISBN-10:0340808195;pg.no.1386.
- [11] Bailey & Love's R.C.G.RUSSELL NORMAN S. WILLIAMS & CHRISTOPHER J.K.WILLIAMS & CHRISTOPHER J.K.BULSTRODE, short practice of surgery 24th edition international student's edition 2004 ;Hodder Education ,a member of the Hodder Headline Group;ISBN-10:0340808195;pg.no.1387.
- [15] Illustrated Sushruta Samhita-nidansthan-edited with AYURVEDA-TATTVA-SANDIPIKA by KAVIRAJA AMBIKADUTTA SHASTRI,A.M.S.Edition reprinted 2018,Chaukhamba orientelia Varanasi;ISBN-978-81-89798-19-2(vol^m-I)pg.no.352.
- [16] Illustrated SushrutaSamhita-sutrasthan-edited with AYURVEDA-TATTVA-SANDIPIKA by KAVIRAJA AMBIKADUTTA SHASTRI, A.M.S.Edition reprinted 2018,Chaukhamba orientelia Varanasi;ISBN-978-81-89798-19-2(vol^m-I)pg.no.130,132.
- [17] Shriram Bhat M;M.S.(General surgery); clinical methods in surgery 4th edition 2013;jaypee brothers medical publishers(p)ltd;ISBN 978- 93-5025-944-3;pg.no.1166.
- [16] [17] Illustrated Sushruta Samhita-nidansthan-edited with AYURVEDA-TATTVA-SANDIPIKA by KAVIRAJA AMBIKADUTTA SHASTRI,A.M.S.Edition reprinted 2018,Chaukhamba orientelia Varanasi;ISBN-978-81-89798-19-2(vol^m-I)pg.no.354.