

Treatment Strategies in Clinically and Radiologically Suspicious but RTPCR Negative Cases of COVID-19 (Case Report)

Dr. Saurabh Tyagi¹, Dr. Frank P², Dr. Trinath Dash³

¹Postgraduate, Department of Respiratory Medicine, Jawaharlal Nehru Main Hospital and Research Institute

²Postgraduate, Department of Respiratory Medicine, Jawaharlal Nehru Main Hospital and Research Institute

³Guide, Joint Director, Department of Respiratory Medicine, Jawaharlal Nehru Main Hospital and Research Institute

Abstract: *In view of the current ongoing pandemic of COVID-19, many cases which are strongly suspected of having COVID LRTI clinically and radiologically but are RTPCR negative in early stages pose a clinical challenge to the treating physician. In these cases, different diagnostic modalities have to be used for diagnosis of COVID-19 and early treatment as per COVID protocols with non-invasive ventilatory support can significantly alter the outcome in favour of patient. We hereby are going to discuss about a case of severe acute respiratory illness due to COVID-19 who was RTPCR negative in earlier stage. He was managed with standard COVID treatment protocols with various modes of non-invasive ventilatory supports and now is being treated in chest ward for post COVID fibrosis.*

Keywords: COVID-19, RTPCR, LRTI, RAT, TrueNAT, antivirals, steroids, anticoagulants, NIV, prone ventilation, serological

1. Case Report

A 57-year-old male patient with no past history of diabetes, hypertension or any other respiratory comorbidity presented with chief complaints of fever for 3 days.

Cough with mucoid expectoration for 3 days

SOB GRADE-II MMRC for 2 days

No H/O chest pain, hemoptysis, loss of consciousness.

On evaluation- patient is conscious, coherent and well oriented.

BP-130/90mmhg,

Heart rate-112/min,

Respiratory rate-26/min,

Spo2%- 54% with 10 liters of oxygen

Temperature-101^oF,

Auscultation – bilateral diffuse fine inspiratory crepts present.

Patient was found rapid antigen negative for COVID (by SD biosensor Q COVID 19 AG detection kit) two days before hospitalisation.

Patient was found RTPCR negative for COVID (by ICMR NIV protocol) on the day of hospitalisation.

Patient was diagnosed to be lower respiratory tract infection due to covid-19 as he came positive by truenat (by TrueNAT_RDRP_C) on day-10 of hospital stay.

- Patient was provided initially with a high flow oxygen through venturi mask
- He was treated with i.v broad spectrum antibiotics (carbapenems, macrolides),
- Antiviral drugs (remdesivir standard dose 200mg i.v od day-1 followed by 100mg i.v od day 2-5), started before the serological confirmation of covid-19 i.e., on day 1 of hospitalisation.
- High dose iv steroids (methylprednisolone 125mg bid) started after inflammatory markers report.

- Anticoagulation (low molecular weight heparin 60mg, s/c, bid).
- Antifibrotic (pirfenidone 801mg TDS) started on day 10 of hospitalisation after CT scan shows sign of fibrosis.
- Supportive medication in the form of zinc, Vitamin-C, B-complex etc.
- Even after the treatment and being on oxygen support, patient had severe hypoxemia (SPO2%- 54% with 10 liters of oxygen) and had to be put on NIV support
- Later was found to be tolerating NIV well, patient oxygen saturation improved and then was provided non-rebreathable mask support
- Patient is having a relatively long hospital stay with NIV and NRM support.
- Later the patient was put on prone ventilation-4cycles/day with each cycle lasting for 2 hours
- Finally, he is maintaining saturation > 95% @ room air, he does not require oxygen support at present and is presently treated for post COVID fibrosis

His routine blood investigations revealed

	08/10/20	14/10/20	17/10/20
WBC (cumm)	14800	8600	7100
Hb (gm/dl)	14.0	14.4	14.4
Platelet count (cumm)	3,08,000	2,44,000	2,29,000
Sr. CREATINE (mg/dl)	1.3	1.1	1.1
Bilirubin (mg/dL)	1.0 (D-0.5 & I-0.5)	0.5 (D-0.2, I-0.3)	0.5 (D-0.2, I-0.3)
LDH (U/L)	895	888	876
Na+(mmol/l)	129	141	140
K+(mmol/l)	3.4	4.0	3.9
Albumin (g/dL)	3.5	3.5	3.5
CRP (mg/Dl)	1.2	1.2	1.2
ALT (U/L)	86	110	108
ALP (U/L)	171	122	120
D-DIMER (mcg/ml) FEU	4.4	3.9	3.6
Sr. Ferritin (ng/ml)	3300	2506	1987

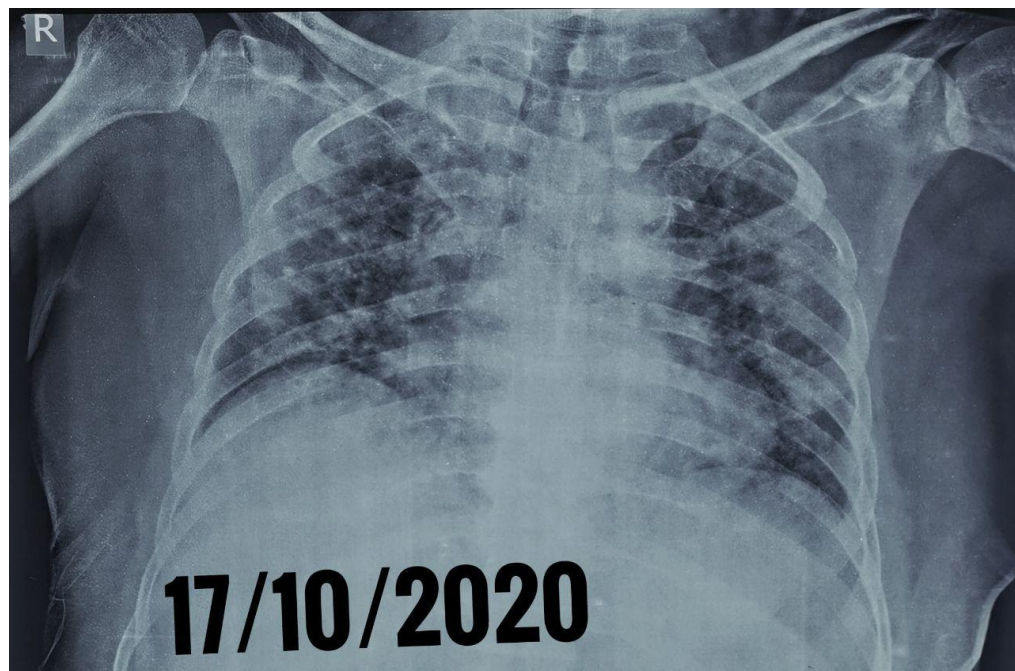
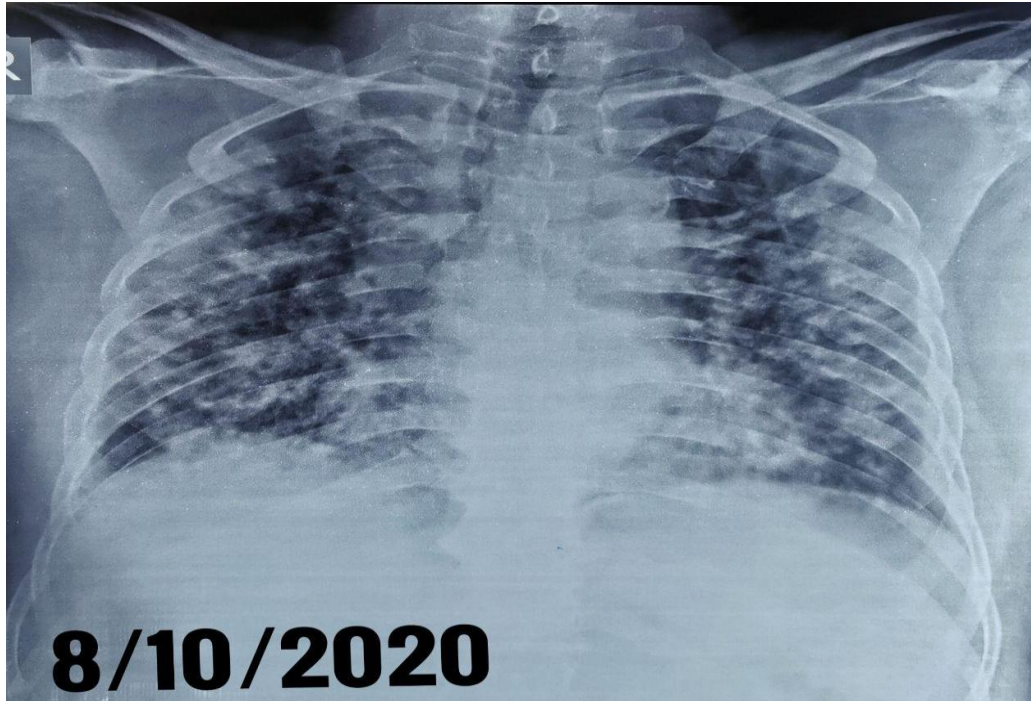
Volume 9 Issue 11, November 2020

www.ijsr.net

Licensed Under Creative Commons Attribution CC BY

Patients Radiological Profile:

Chest X-Ray: B/L fluffy homogenous shadows all over the lung fields



HRCT chest: (16/10/2020)

S/o bilateral multiple diffuse ground glass opacities with changes of consolidation with crazy paving appearance in

B/L lower lobes. Interlobular septal & vascular thickening seen in B/L lungs with mediastinal lymphadenopathy. Findings suggest p/o viral pneumonia. Corads -4. Ct severity index - 21/25



At the time of admission patient was in ARDS having spo₂ 54% with 10 liters of oxygen. He was put on NIV support and managed by hospital COVID protocol with remdesivir even though he was rapid antigen and RTPCR COVID negative because of strong clinical suspicion and radiological abnormalities pattern. His COVID test was repeated by truenat (by TrueNAT_RDRP_C) on day-10 of hospital stay which came positive.

He responded well to treatment and showed gradual improvement clinically and radiologically, his saturation also improved, and he was put off from NIV support on day 15 of hospitalisation and was put on NRM mask in chest ward with oral anticoagulants, started antifibrotics (pirfenidone 801mg tds). He was started on intermittent prone ventilation consisting of 4cycles/day with each cycle lasting upto 2 hours. He was also advised to do incentive spirometer. At present patient is off oxygen support, maintaining saturation > 95% at room air, and getting treatment for post COVID fibrosis.

2. Discussion

Early diagnosis, antiviral and steroid therapy with ventilator support, secondary infection control and prevention of coagulation dysfunction are foundation of COVID-19 management. However, its challenging to decide or make a standard treatment protocol since every treatment plan needs to be individualized accordingly as per patient's response to treatment and his clinical parameters.

Here in this case, patient presented with ARDS. Although he was RTPCR negative for COVID-19 he was still put on antivirals (remdesivir), injectable steroids (methylprednisolone) and anticoagulants (enoxaparin) as per covid treatment guidelines because there was a strong clinical and radiological suspicion of covid-19.^{[1][2][3]}

As rapid antigen test and RTPCR test for COVID-19 was negative for patient, a repeat COVID test by truenat (by TrueNAT_RDRP_C) on day-10 of hospital stay was done

which came positive. The advantage of truenat over RTPCR is shortening reporting time, cost effectiveness and readily availability in Indian field settings. For COVID-19 truenat assays showed concordance with the reference standard assay and may be recommended for screening and confirmation of COVID-19 in field settings.^[4]

This patient was put on non-invasive methods of ventilation, firstly on NIV and then on NRM masks and both was well tolerated by patient, also showing rapid improvement in oxygen saturation. An early and timely intervention with non-invasive ventilation has shown that the need for intubation can be reduced.^[5]

This patient was also put on antifibrotics (pirfenidone 801mg TDS) started on day 10 of hospitalisation just after his ct scan showed sign of fibrosis. The burden of fibrotic lung disease following sars-cov-2 infection is likely to be high; therefore, given the scale of pandemic, the global burden of fibrotic lung disease will probably increase considerably. Pirfenidone reduces serum and lung IL6 concentrations in murine models of pulmonary fibrosis, providing biological rationale for the use of pirfenidone in COVID-19.^[6]

3. Conclusion

- Early diagnosis, antiviral and steroid therapy with ventilatory support, secondary infection control and prevention of coagulation dysfunction are foundations of covid-19 management.
- Early initiation of treatment as per covid protocols can be done in clinically and radiologically suggestive cases of covid-19 even though if patient is not confirmed having covid-19 by diagnostic tests.
- Different types of diagnostic tests (antigen based, rtPCR based, truenat) should be done timely for covid-19 clinically and radiologically suggestive but serologically negative cases.
- Where ever available truenat test for covid-19 is recommended for screening and diagnostic purpose because of its short reporting time and cost effectiveness.
- Patients who are into early respiratory failure can be firstly managed with non-invasive ventilation, keeping the invasive method of ventilation in reserve for cases which can not be managed by niv.
- Patients should be monitored closely for developing early fibrosis and should be started on anti-fibrotics early in the course of disease progression.

References

- [1] Shahamah Jomah, Syed Mohammed Basheeruddin Asdaq, Mohammed Jaber AL-Yamani, Clinical efficacy of antivirals against novel coronavirus (COVID-19): A review, *Journal of Infection and Public Health*, Volume 13, Issue 9, September 2020, Pages 1187-1195
- [2] Maryam Edalatfard et al, Intravenous methylprednisolone pulse as a treatment for hospitalised severe COVID-19 patients: results from a randomised controlled clinical trial, *European Respiratory Journal* 2020; DOI: 10.1183/13993003.02808-2020.

- [3] Marta Camprubí-Rimblas, NeusTantinyà, JosepBringué, Raquel Guillamat-Prats, and Antonio Artigas, Anticoagulant therapy in acute respiratory distress syndrome, *Annals of Translational Medicine*, 01 Jan 2018, 6(2):36, DOI: 10.21037/atm.2018.01.08 PMID: 29430453 PMCID: PMC5799142
- [4] Basawarajappa, Rangaiah et al. Performance evaluation of Truenat™ Beta CoV&Truenat™ SARS-CoV-2 point-of-care assays for coronavirus disease 2019, *Indian J Med Res*, Epub ahead of print DOI: 10.4103/ijmr.IJMR_2363_20.
- [5] Nasibova EM, Pashayev CN (2020) The Use of Non-Invasive Ventilation (NIV) in the Treatment of Patients with COVID-19. *J Intensive & Crit Care* Vol.6 No.2:5.
- [6] Peter M George et al. Pulmonary fibrosis and COVID-19: the potential role of antifibrotic therapy. Published: May 15, 2020 DOI: [https://doi.org/10.1016/S2213-2600\(20\)30225-3](https://doi.org/10.1016/S2213-2600(20)30225-3) PlumX Metrics