

Functional and Radiological Outcome of Distal Radius Fractures Treated by Volar Locking Plating

Dr Sanjeev Gupta¹, Dr Tanveer Ali²

¹Professor and HOD, Department of Orthopaedics, GMC Jammu, India

²PG Resident, Department of Orthopaedics, GMC Jammu (corresponding author)

Abstract: ***Objective:** To evaluate radiological and functional outcome in fractures of the distal radius treated with internal fixation by applying volar locking plate. **Material and Methods:** Twenty seven patients (10 males, 17 females) with different types of fractures of distal radius were treated. Open reduction and Internal fixation was performed by applying volar locking plate. Anatomical restoration was evaluated by postero-anterior and lateral radiographs obtained preoperatively and at 09 months of follow up to evaluate Radial Height (RH), Radial Inclination (RI) and Volar Tilt (VT). Functional outcome was evaluated using Mayo scoring system. **Results:** Out of 27 patients, 5 had type A, 9 had type B and 13 had type C fractures (AO classification). Average procedure time was 45 minutes. According to Mayo score, 81.5% (n=22) of our patients had excellent to good outcome while as 18.5% (n=5) had fair outcome. **Conclusion:** Volar plating for fracture distal end radius reduces complications and decreases chances of re-displacement and malunion leading to better outcome. So in our opinion, volar plating for treatment of fracture distal end radius is an acceptable method with excellent outcomes.*

Keywords: Distal Radius Fracture, Volar plating, Mayo Score, Radiological outcome

1. Introduction

Fractures of lower end radius are most common fractures of the upper extremity encountered in practice and constitute 17% of all fractures and 75% of all forearm fractures. [1] These injuries account for approximately one sixth of all fractures seen and treated. In the words of Dr. Abraham Colles “this fracture takes place about an inch and a half above the carpal extremity of the radius and there is a 17% lifetime probability for distal radius fractures”. [2] The majority of these injuries are 'closed', with no evidence of breach of the surrounding skin.

Restoration of radial length, radial tilt and congruity of articular surfaces is important for good functional results. [3] Failure to achieve and maintain near anatomic restoration can lead to various deformities and disabilities. The treating orthopedician has an armamentarium of treatment options to select from to accomplish this. Distal radial fractures are being treated by various methods i.e. closed reduction with cast immobilizations, percutaneous pinning, external fixation and ORIF with conventional plating. Regardless of these fractures being common, there is no clear consensus on their treatment as there is no clear clinical-based evidence in the literature. [4] It is often not possible to have a successful outcome using the same approach and materials for different types of fractures.

Recognition of fracture patterns, secure fixation of fractures and maintenance of reduction is the key for successful management of more complex fractures of distal radius. [5]

The purpose of this study was to determine anatomical restoration and stabilization of acute fracture of the distal radius and functional outcome following ORIF by applying variable angle locking volar plate.

2. Material and Methods

This was a prospective study of 27 patients with distal radius fractures who were treated by ORIF by using fixed angle volar plate in Government Medical College and Hospital, Jammu for a period of one year from September 2018 to October 2019.

Patients with fractures of distal end radius of either side or both sides, with or without ulnar styloid fracture, of age group 18 – 85 years, of either sex having closed fractures of up to 3 cm from distal articular surface of radius willing for treatment were enrolled for this prospective open randomized case control comparative study. Patients less than 18 years or more than 85 years, having compound fractures associated with vascular injuries or had associated multiple injuries were excluded from the study.

All fractures were classified according to AO (the Association for Osteosynthesis) classification system [6] by getting Postero-Anterior (PA) and Lateral (Lat) views of radiographs of the wrist at the time of the initial injury. Some patients needed CT scan of wrist for further evaluation of intra-articular fractures.

The patients were admitted to the hospital and were operated on as soon as possible, depending on the condition of the local tissue, hematoma, tissue oedema and other associated injuries. After obtaining informed written consent, open reduction and internal fixation was performed via volar approach. Surgery was performed under brachial plexus block or general anaesthesia under fluoroscopic guidance. All the surgeries were performed by the same surgeon who was well versed with procedure and the implants used.

Surgical Procedure (Volar approach): Surgery was performed under appropriate anaesthesia i.e. either general anaesthesia or supra clavicular block under tourniquet control.

Volume 9 Issue 2, February 2020

www.ijsr.net

Licensed Under Creative Commons Attribution CC BY

In this technique, the skin was incised longitudinally along the course of the flexor carpi radialis (FCR) tendon. The FCR sheath was opened and the tendon retracted to the radial side to expose the ulnar corner of the distal radius (this can be extended into a carpal tunnel release). The FCR tendon was also retracted to the ulnar side to expose the radial styloid and scaphoid fossa. Great care was taken to avoid pressure on the median nerve. Underneath the FCR sheath lies the flexor pollicis longus (FPL) tendon. This was retracted ulnarly revealing the pronator quadratus (PQ) muscle. The PQ muscle was elevated from its radial origin and reflected ulnarly to expose the distal radius.

If the fracture is very distal, it is not necessary to completely elevate this muscle. The palmar extrinsic radiocarpal ligaments should not be detached from the radius to expose the joint surface as this may destabilize the wrist. Palmar fragments may often be comminuted and impacted. Each fragment was identified, elevated, and reduced. As the palmar surface of the distal radius is originally flat, the application of a flat implant onto this surface usually corrects any malrotation of the fracture fragments.

The C-arm was used to check for screw placement and reduction. Radiographs of the wrist joint were taken after surgery. Sutures were removed after 10 days and active wrist motion started. Cast was applied for 6 weeks postoperatively.

3. Radiological Evaluation

Radiological assessment was done in terms of residual Radial Inclination (RI), Radial Height (RH) and Volar Tilt (VT) and the results were graded according to the Lid Strom Criteria. Radiological parameters included measurement of through Postero-anterior and lateral radiographs.

PA view provides information about RI (Radial Inclination) and RH (Radial height). RI is a measurement of the radial angle. A line is drawn along the articular surface of the radius perpendicular to the long axis of the radius, and a tangent is drawn from the radial styloid. The normal angle is 15-25°. RH is a measurement between 2 parallel lines that are perpendicular to the long axis of the radius. One line is drawn on the articular surface of the radius, and the other is drawn at the tip of the radial styloid. The normal radial height is 9.9-17.3 mm.[7]

In the Lateral view, the VT (Volar Tilt) of the distal radius articular surface is measured. A line perpendicular to the long axis of the radius is drawn, and a tangent line is drawn along the slope of the dorsal-to-volar surface of the radius. The normal angle is 10-25°. [7]

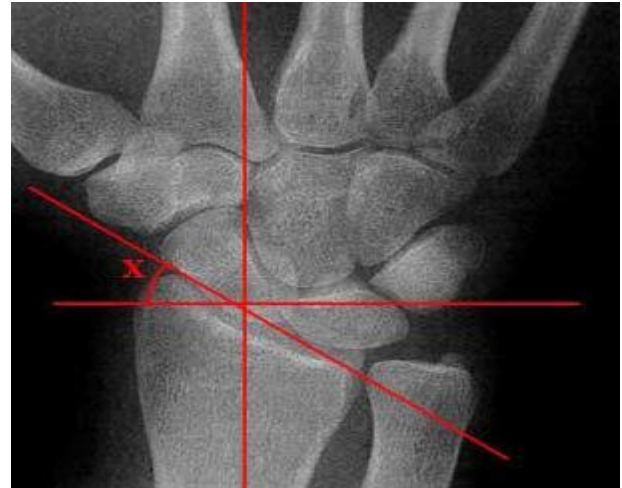

Figure: Radial inclination

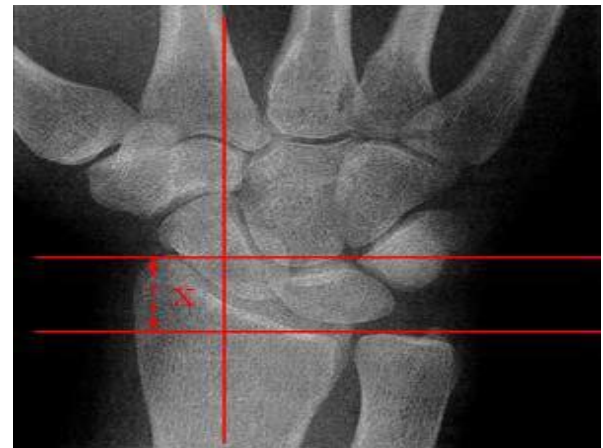

Figure: Radial Height

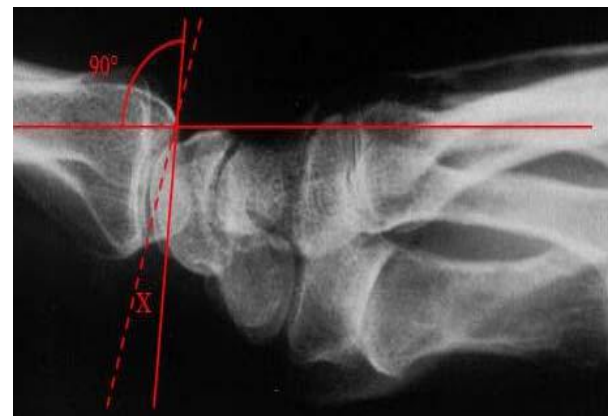


Figure: Volar tilt

These measurements were taken pre operatively and at 9 months follow up. At the end of the study all the data was compiled and analyzed statistically by a one-way measure ANOVA test. P-value less than 0.05 was considered to be statistically significant.

Functional Evaluation

Patients were evaluated by using Modified Mayo Wrist Score. It is a physician-rating scoring system which gives us a total score of a 100; 25 for the assessment of pain, 25 for the active extension/flexion arc of the wrist, 25 for grip strength, and 25 for the ability to return to regular activities. The pain is rated according to patient's description.

Category	Findings	Score
Pain (25 points)	No pain	25
	Mild occasional	20
	Moderate	15
	Severe	0
Work status (25 points)	Regular job	25
	Restricted job	20
	Able to work but unemployed	15
	Unable to work due to pain	0
Range of motion (25 points)	>120°	25
	100° to 119°	20
	90° to 99°	15
	60° to 89°	10
	30° to 59°	5
	0° to 29°	0
Grip strength (% of normal) (25 points)	90 to 100	25
	75 to 89	15
	50 to 74	10
	25 to 49	5
	0 to 24	0

Final result (total points)	Excellent	90-100
	Good	80-89
	Fair	65-79
	Poor	<65

4. Results

A total of 27 patients underwent this surgery comprising of 10 males and 17 females. The mean age and Standard Deviation (SD) at the time of the injury was 57.37 ± 11.58 years (range from 22 to 82 years). Fourteen (51.8%) fractures involved right side while thirteen (48.2%) fractures occurred on the left. Mode of injury was road traffic accident and fall in majority of the cases.

According to AO classification, most of the cases were of C (n = 13) 48.1% and B (n = 9) 33.3% type probably because of increased incidence of high velocity injuries. (Table 1)

Table 1: Types of fracture

Radiological Type (AO)	Frequency	Percent
A3	5	18.5%
B2	4	14.8%
B3	5	18.5%
C1	5	18.5%
C2	6	22.2%
C3	2	7.5%
Total	27	100.0%

Distal radius deformity was assessed by measuring RH, RI and VT at different stages of treatment. We found a mean radial inclination of 22.07±4.08°, radial height of 12.44±4.08mm and volar tilt of 10.85±2.74° (Table 2).

Table 2: Radiological evaluations of RH, RI and VT

	Volar plating group
Radial Inclination	22.07±4.08°
Radial Height	12.44±4.0 mm
Volar Tilt	10.85±2.74°

Table 3: Values on the basis of type of fracture

Type of fracture	No. of cases	Radial Inclination	Radial Height	Volar Tilt
Type A	5	24.4mm	12.4mm	10.8°
Type B	9	23.5mm	9.4mm	8.7°
Type C	13	22.2mm	14.5mm	12.3°

Table 4: Mayo score following volar plating

Result	Frequency	Percent
Excellent	15	55.6%
Good	7	25.9%
Fair	5	18.5%
Total	27	100.0%

According to Mayo score 81.5% (n=22) of our patients had excellent to good outcome while as 18.5% (n=5) had fair outcome.

Complications:

One of our patient suffered from tendon injury and 2 had residual stiffness. 2 patients had infection of the implant which had to be managed by operative means and 1 patient suffered from malunion (Table 5).

Table 5: Complications seen during volar plating.

Complications	Frequency	Percent
Nil	21	77.8%
Tendon injury	1	3.7%
Stiffness	2	7.4%
Infection	2	7.4%
Malunion	1	3.7%
Total	27	100.0%

5. Discussion

The management of fractures of distal radius has always been a debatable and challenging issue for orthopaedic surgeons. The ultimate goal is to restore grip strength and motion and allow quick return of function and to minimize the risk for future degenerative changes in the wrist joint. The rise of intra articular distal radius fractures and its various presentations of complexity in even younger individuals are predominantly due to high energy trauma especially road traffic accidents.

Different studies have proved that internal fixation with fixed angle volar plate showed better results in terms of restoration of anatomy, fixation, stability and function in comparison with other methods. The advantages of open reduction and internal fixation include direct visualization and manipulation of the fracture fragments, stable rigid fixation, and facilitation of early mobilization and hence early return to activities with good range of movements. [8,9] Fixed-angle plate designs minimize screw loosening in the distal fragments due to a 'toggling effect' and thus reduce the danger of secondary displacement. Since lock plates do not rely on frictional forces for stability, direct plate to bone compression is not required, so one can preserve periosteal blood supply and can therefore be used in osteoporotic bones or comminuted fractures. [10]

The subchondral placement of smooth pegs is useful to buttress small articular fragments and successfully control shortening and angular displacement, especially in

osteoporotic bone. Most fractures can be managed through a single volar access despite the presence of dorsal fragments, resulting in acceptable outcomes and good implant stability.

We conducted a study on 27 patients comprising of 10 males and 17 females. Right side was involved in Fourteen (51.8%) patients while thirteen (48.2%) fractures occurred on the left.

In our study mode of injury was road traffic accident [16 (59%)] and fall [9 (33%)] in majority of the cases. Ayhan Kilic et al in their study found road traffic accident in 13 patients (48.1%) and fall in 14 patients (51.9%) while Chung KC et al found 42 patients (48.3%) had road traffic accident and 45 patients (51.7%) suffered trauma due to fall. [11,12]

Xavier et al have concluded in their study that restoration of the radial length is an important determinant of the difference in extension and grip strength between the fractured and non-fractured limbs. [13] We found a mean radial inclination of $22.07 \pm 4.08^\circ$, radial height of 12.44 ± 4.08 mm and volar tilt of $10.85 \pm 2.74^\circ$. There were minor variations in the anatomical parameters (volar tilt, radial inclination and radial height) in our study which were comparable with the other studies but did not affect functional results significantly. [4, 14, 15, 16,] However, significant variation in anatomy (post reduction) may result in cosmetic deformity, poor functional results and early symptomatic osteoarthritis.

According to Mayo score 81.5% (n=22) of our patients had excellent to good outcome while as 18.5% (n=5) had fair outcome which is comparable to the study by Melone et al who reported on fifteen patients who had a severely displaced intra-articular fracture of the distal end of the radius that were treated by ORIF and had a good functional outcome in approximately 80% cases. [17] Similarly Agarwala *et al.* reported excellent/good result in 88% and satisfactory result in 12% of patients and comparable results were obtained in the study done by Chavhan *et al.* [4,18]

One of our patient suffered from tendon injury and 2 had residual stiffness. 2 patients had infection of the implant which had to be managed by operative means and 1 patient suffered from malunion.

6. Conclusion

Open reduction and internal fixation has been shown to be effective in the treatment of unstable intra-articular distal radius fractures. Locking compression plates provide good to excellent results and are effective in the correction and maintenance of the distal radial anatomy. By using these plates, joint motion and daily functioning recovered in a short time.

Case 1

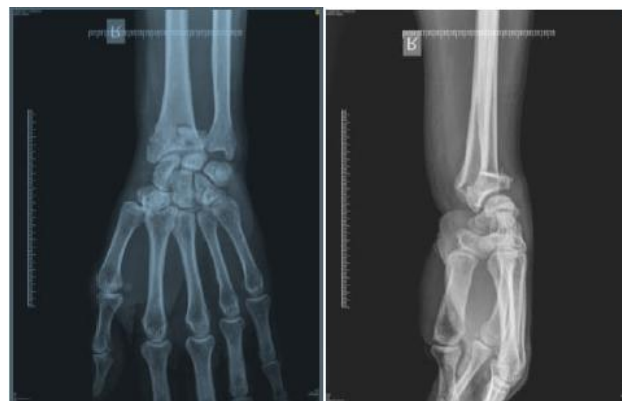

Figure 23: Pre-op AP and lateral X-ray.

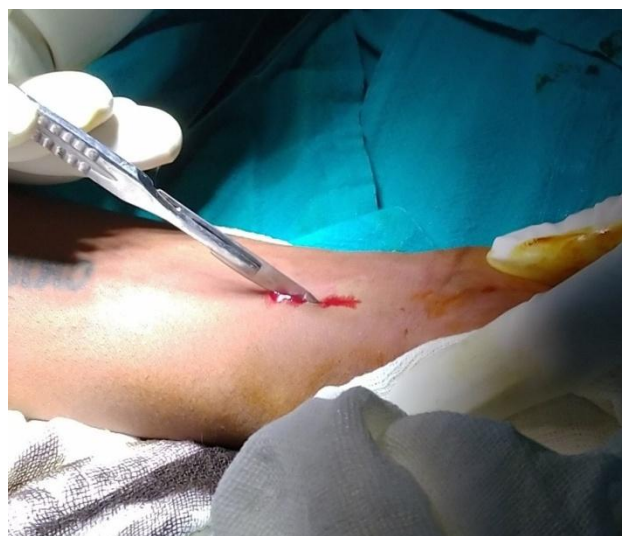

Figure 24: Incision for volar plating.

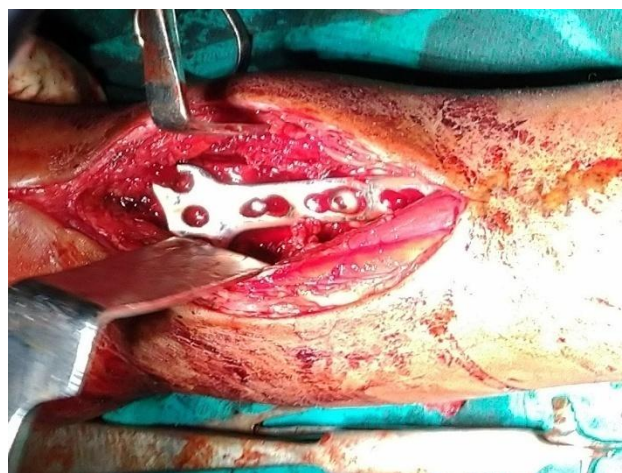


Figure 25: Volar plate in situ.

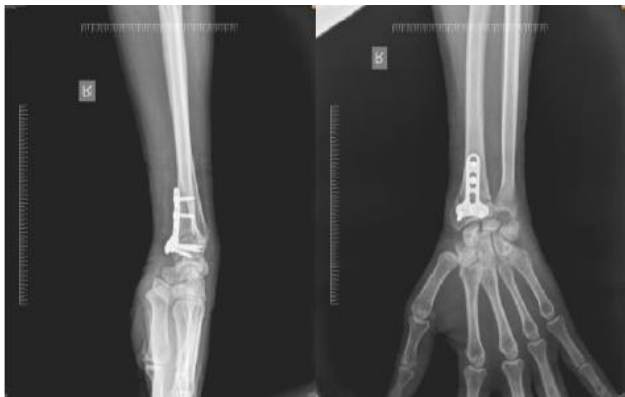

Figure 26: Post-op X-ray

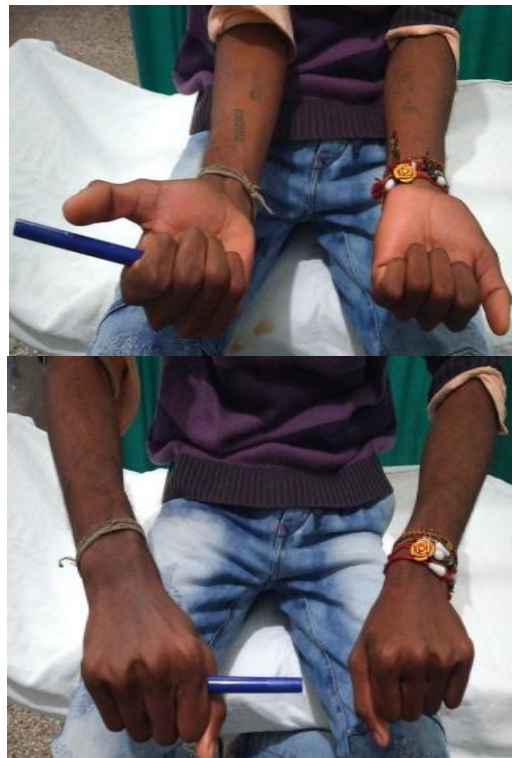

Figure 29: Supination and pronation after Volar plating at 12 weeks follow-up.

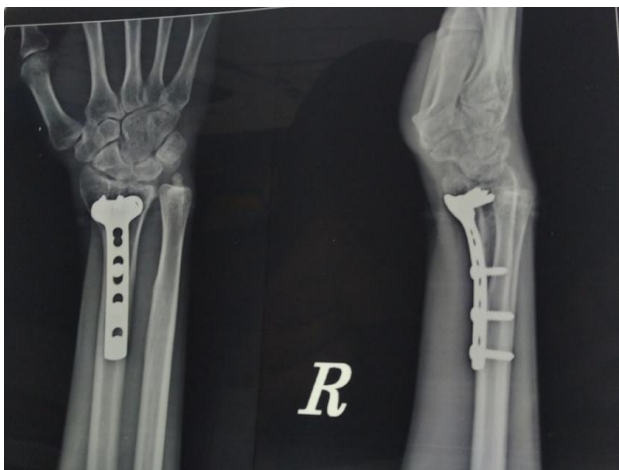

Figure 27: Healed fracture site

Case 2

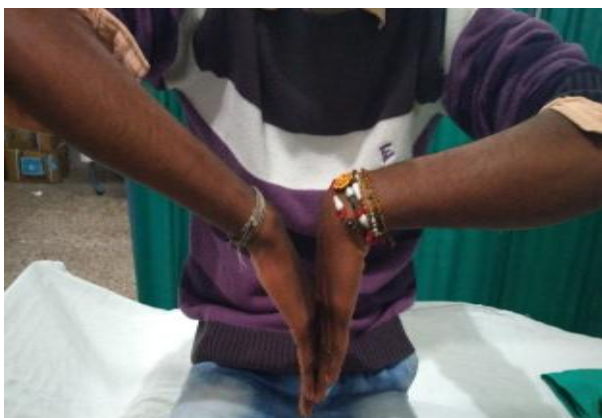

Figure 28: Palmar flexion and dorsiflexion after Volar plating at 12 weeks follow-up

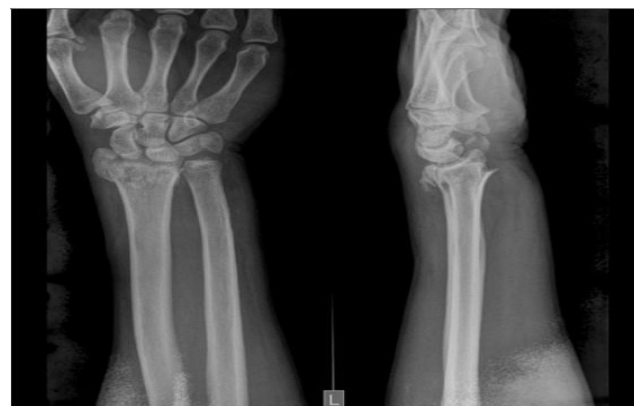

Figure 30: Pre-op X-ray

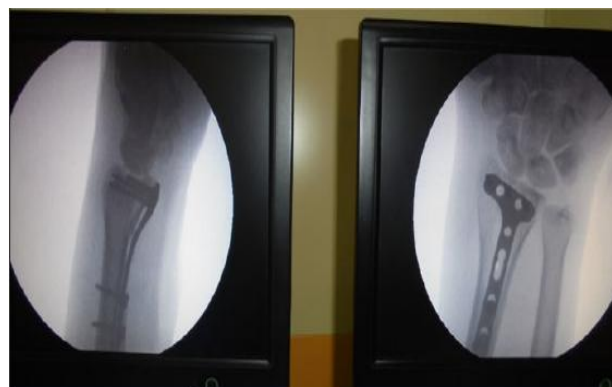

Figure 31: Visualization under C-arm post volar plate placement

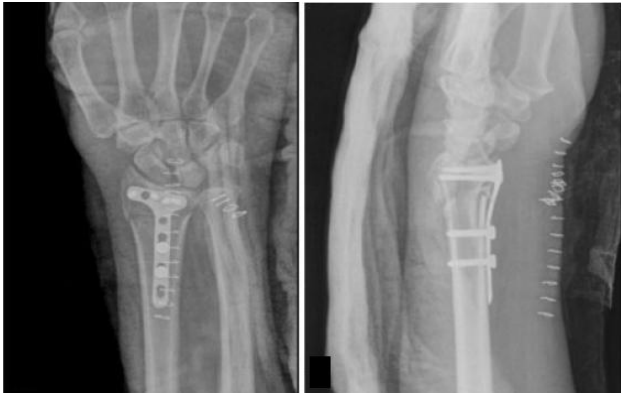

Figure 32: Post-op X-ray.

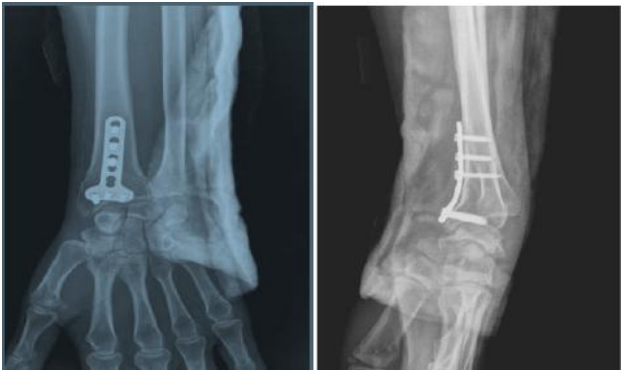

Figure 33: Follow-up X-ray at 6 weeks



Figure 34: Pronation and supination at 12 weeks follow-up



Figure 35: Palmar flexion and dorsiflexion at 12 weeks follow-up

References

- [1] Frank A, Liporace MD, Mark R, Adams, John T Capo, Kenneth J Koval. Distal Radius Fractures. *J Orthop Trauma*. 2009; 23:739-748.
- [2] Colles A. On the fracture of the carpal extremity of the radius. *Edinburgh Med Surg* 1814; 10:182-6.

- [3] Bassett RL. Displaced intraarticular fractures of the distal radius. *Clin Orthop Relat Res*. 1987; 214(214):148-152.
- [4] Agarwala S, Mohrir GS, Gadiya SD. Functional outcome in distal radius fractures treated with locking compression plate. *Bombay Hospital J*. 2012;54(2):209-19.
- [5] Koi K, Hattori Y, Otsuka K. Intra-articular fractures of the distal aspect of the radius: Arthroscopically assisted Reduction Compared with Open Reduction and Internal Fixation. *J Bone Joint Surg*. 1999;81:1093-110.
- [6] Clayton RAE, Gaston MS, Ralston SH, Court-Brown CM, McQueen (2009) Association between decreased bone density and severity of distal radial fractures. *J Bone Joint Surg AM* 91: 613-619.
- [7] Cooney WP, Linscheid RL, Dobyns JH. External pin fixation for unstable Colles' fractures. *J Bone Joint Surg (Am)*. 1979; 61:840-5.
- [8] Christoph Bartl, Dirk Stengel, Thomas Bruckner, Inga Rossion, Steffen Luntz, Christoph Seiler, et al. Open reduction and internal fixation versus casting for highly comminuted and intra-articular fractures of the distal radius (ORCHID): protocol for a randomized clinical multi-center trial. *Bartl et al. Trials*. 2011; 12:84
- [9] Altissimi M, Antenucci R, Fiacca C, Mancini GB. Long-term results of conservative treatment of fractures of the distal radius. *Clin Orthop Relat Res*. 1986;(206):202-10
- [10] Mudgal CS, Jupiter JB. Plate fixation of osteoporotic fractures of the distal radius. *J. Orthop Trauma*. 2008;22(8):S106-15.
- [11] Chung KC, Watt AJ, Kotsis SV. Treatment of unstable distal radial fractures with the volar locking plating system. *J Bone Joint Surg Am*. 2006;88:2687-94.
- [12] Kilic A, Kabukcuoglu Y, Ozkaya U, Gul M, Sokusu S, Ozdogan U. Volar locking plate fixation of unstable distal radius fractures. *Acta Orthop Traumatol Turc*. 2009;43(4):303-8.
- [13] Xavier CRM, Molin DCD, Santos RMM, Santos RDT, Neto JCF. Surgical treatment of distal radius fractures with a volar locked plate: correlation of clinical and radiographic results. *Rev Bras Ortop*. 2011; 46(5):505-13
- [14] Wong KK, Chan KW, Kwok TK, Mak KH. Volar fixation of dorsally displaced distal radial fracture using locking compression plate. *J Orthop Surg (Hong Kong)*. 2005; 13:153-7.
- [15] Rizzo M, Katt B, Carothers J. Comparison of locked volar plating versus pinning and external fixation in treatment of unstable intra-articular distal radial fractures. *Hand*. 2008; 3:111-7.
- [16] Minegishi H, Dohi O, An S, Sato H. Treatment of unstable distal radius fractures with the volar locking plate. *Ups J Med Sci*. 2011; 116:280-4.
- [17] Melone CP Jr. Open treatment for displaced fractures of the distal radius. *Clin Orthop*. 1986; 202:103-11.
- [18] Chavhan AN, Dudhekar UJ, Badole CM, Wandile KN. Functional and radiological outcome in distal radius fractures treated with locking compression plate. *Int. J Res Med Sci*. 2017; 5:574-82.