

Intra-Oral Fibro-Lipoma of the Palate: A Case Report

Dr. S Vinod Thangaswamy¹, Dr. Prasanna Kumar P², Dr. Jambukeshwar Kumar B³, Dr. P. I. Nainan⁴, Dr. Shreya B Malapur⁵, Dr. Patel Mohmed Talib Abdul Rashid⁶, Dr. Sarath K⁷

¹Professor, Department of Oral and Maxillofacial Surgery, Coorg Institute of Dental Sciences, Virajpet

²Professor & HOD, Department of Oral and Maxillofacial Surgery, Coorg Institute of Dental Sciences, Virajpet

³Reader, Department of Oral and Maxillofacial Surgery, Coorg Institute of Dental Sciences, Virajpet

⁴Post Graduate, Department of Oral and Maxillofacial Surgery, Coorg Institute of Dental Sciences, Virajpet

⁵Post Graduate, Department of Oral and Maxillofacial Surgery, Coorg Institute of Dental Sciences, Virajpet

⁶Post Graduate, Department of Oral and Maxillofacial Surgery, Coorg Institute of Dental Sciences, Virajpet

⁷Senior Lecturer, Department of Oral and Maxillofacial Surgery, Coorg Institute of Dental Sciences, Virajpet

Abstract: *Lipoma is the mesenchymal benign tumour which is uncommon in oral cavity, whereas Fibrolipoma is a microscopic variant of lipoma which is rarely seen in palate. Here is a case report of fibrolipoma of palate which was followed up for 9 months, where surgery is treatment of choice with low recurrence.*

1. Introduction

Lipoma is a rare intra-oral tumor affecting about 1-4% of oral cavity(1). It is the most common soft tissue neoplasm which is benign in nature and grows slowly. It is chiefly composed of mature fat cells(2). The etiology and pathogenesis for these lesions are not clear. One of the most accepted reason for their occurrences is due to developmental anomalies that occur in the oral and maxillofacial region and are presumed to be neoplasms of adipocytes associated with trauma(2).

Roux in 1848 first described oral lipoma which he had termed "yellow epulis". Shafer says that a person on a starvation diet will lose fat from normal fat deposits in the body but not from a lipoma. Further fatty acid precursors are incorporated at a more rapid rate into lipoma fat than into normal fat and lipoprotein lipase activity is reduced. It has been shown that for energy production in lipoma, fat is used during starvation period, as it happens with normal adipose tissue; their lipid is not available for metabolism. Adipose tissue is present in two basic forms white fat and brown fat(2).

Fibro-lipoma is a microscopic variant of lipoma, which is characterized by mature adipose tissue interspersed by dense fibrous connective tissue which is an unusual occurrence within the oral cavity. This is a case report on Fibro-lipoma of palate, which reported to our unit of Oral and Maxillofacial Surgery.

2. Case Report

A 66 year old male reported to our unit of Oral and Maxillofacial Surgery with a painless swelling on his palate since 25 years. The swelling had gradually increased in size

to the current size, gives no history of pain, difficulty in speech and mastication. Patient gives no history of trauma to the site or sudden weight loss. His medical history reported of hypertension and diabetes in the past 19 years and was under control with regular medications. He was a known smoker for 25 years (cigarette and beedi) and quit on his own 20 years ago. He is an occasional alcoholic.

On intra-oral examination, we observed a single, solitary, well defined pedunculated mass in the anterior mid-palatine region of the edentulous maxilla about 2cm posterior to the incisive papilla measuring about 1.2cm×1.2cm×0.5cm. The surface of the swelling appeared smooth and melanotic with no discharge noted. On palpation, all inspectory findings were confirmed with no local rise in temperature, non-tender, soft to semi-firm in consistency and was mobile with no pulsations felt. No local lymph node involvement was noted.

Considering the above-mentioned clinical features, provisional diagnosis of fibroma was given with a differential diagnosis of pyogenic granuloma, lipoma or minor salivary gland tumor.

Intra-oral occlusal radiographs did not show any underlying bone involvement. Routine blood investigations and examination of vital signs, showed all parameters to be in normal range.

Treatment of surgical excision of the lesion in-toto was performed under local anaesthesia with 2% Lignocaine (with 1:80,000 adrenaline). The incision was placed with electrocautery and the pedunculated mass was excised through its base attached to the periosteum of the hard palate and sent for histopathological examination. No intra-operative complications were encountered. The raw surface was left to heal by secondary intention.

Volume 9 Issue 3, March 2020

www.ijsr.net

Licensed Under Creative Commons Attribution CC BY

Patient was followed up till 9 months with no reported signs of recurrence of the lesion.

3. Histopathology

The gross specimen was greyish white in color and measured 1.9x1.4x0.7cms. The specimen was cut across to reveal few yellowish gelatinous areas. The specimen was then processed through alcohols & xylene and impregnated & embedded in paraffin wax. Sections of 5µm thick were prepared and stained using haematoxylin and eosin stains. The sections thus obtained showed stratified squamous parakeratinised surface epithelium with short and blunt rete pegs overlying a proliferative connective tissue. The connective tissue was composed juxta-epithelially of dense bundles of collagen that was sclerotic in many foci. The central area showed a collection of adipocytic tissue composed of lobules of mature adipocytes. Blood vessels of varying caliber and some areas of hemorrhage were also noted. The histopathological features were that of a Fibro-Lipoma.

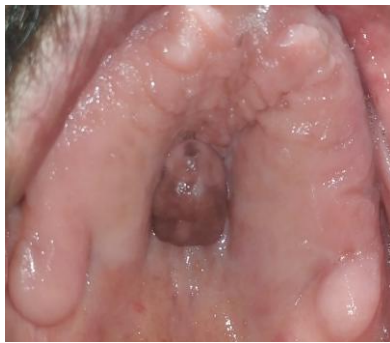

Figure 1: Lesion in the hard palate

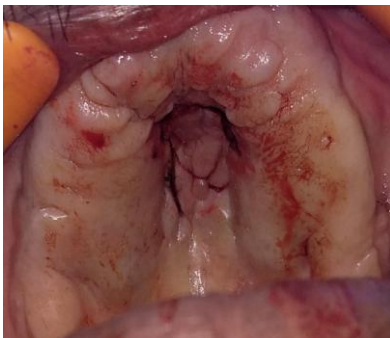

Figure 2: Complete Excision of lesion

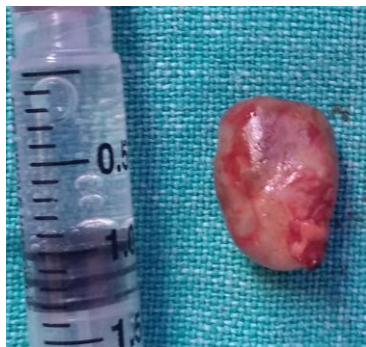

Figure 3: Lesion in en mass

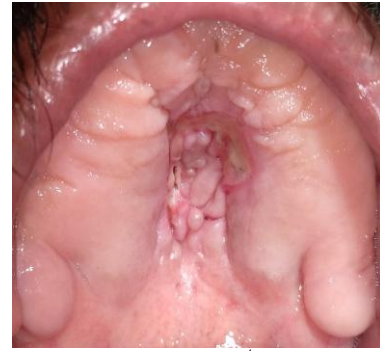

Figure 4: Post operative 1st month follow up

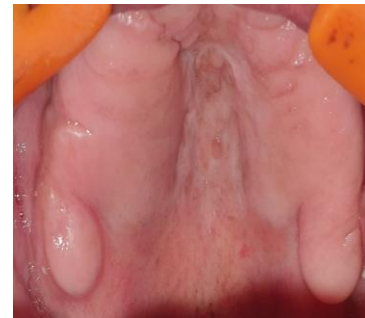

Figure 5: Post operative 9th month follow up

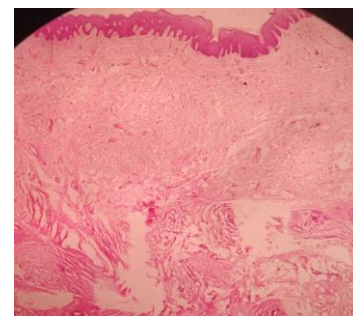


Figure 6: Histopathology of Fibrolipoma

4. Discussion

Lipoma, usually a solitary lesion may be sessile, pedunculated or submerged, ranging in size from 1cm in diameter to a massive tumor of 5cm. The surface is usually non-ulcerated with deeper lesions varying in contour and shape (3).

Lipomas are seen in patients after the age of 30 years. Although they may be congenital, more than half of cases occur between 4th and 5th decade of life. Oral lipomas have been reported in individuals from 6 weeks of age to 75 years with a mean age of 60 years, rarely seen in children(4)

Oral lipomas tend to occur with equal predilection in bothmen and women. But, Furlong et al., mentioned that frequency of oral lipoma is most common in men (as presented here). Although, it should be mentioned here that Freitas et al., showed oral lipoma has a predilection for occurrence inwomen (5,6)

Hatziotis et al., [7] had reviewed the literature from 1945 to 1967 and had found 145 cases of intraoral lipomas of which only six cases occurred in the hard palate. ER Fregnani and his associates reviewed 46 cases of lipomas and found none

occurring in the palate. Review of a few large reported series of intraoral lipoma and its variants seen in the literature did not show any case of oral lipoma occurring in hard palate(8)

According to histopathologic aspects, benign tumors of adipose tissue (lipoma) are classified as: Simple lipoma, Fibrolipoma, Angiolipoma, Intramuscular lipoma, Pleomorphic lipoma, Sialolipoma, e.t.c. Most of lipomas exhibit characteristic yellowish colour adipose tissue with thin overlying epithelium. Fibrolipoma denotes matured fat cells with fibrous tissue in the surrounding area which is rare findings of intra oral lesions.

In our case, there was a single pedunculated swelling, having normal overlying mucosa with hyperpigmentation, mobile with semi-firm consistency observed in the hard palate. Radiographic interpretation showed no bony encroachment denoting diagnosis of fibroma. Surgical removal of the lesion with cautery is preferable treatment of choice as it prevents excess bleeding and also helps in complete excision.

5. Conclusion

Fibrolipoma of hard palate is an uncommon tumor of oral cavity. Clinical presentation of Fibrolipoma is asymptomatic unless it becomes large enough and alters mastication and speech or causes difficulty in denture placement. According to previous case reports of fibrolipoma seen in the palate, which is a rare occurrence, it should be considered in the differential diagnosis in swelling of the palate. Complete excision of lesion with cautery is preferable treatment of choice to the patients with good recovery and low recurrence.

References

- [1] Fregnani ER, Pires FR, Falzoni R, Lopes MA, Vargas PA. Lipomas of the oral cavity: Clinical findings, histological classification and proliferative activity of 46 cases. *Int J Oral Maxillofac Surg.* 2003;32(1):49–53.
- [2] Chavan S, Ingle Y, Deshmukh R, Kulkarni V. Fibrolipoma - A Rare Intraoral Tumor: A Case Report. *J Dent Allied Sci.* 2013;2(2):83.
- [3] Amena Raninwala, Hemanth Kale, Tapan Modi and Kajal Dave. Intra-oral lipoma-case report. *Journal of the International Clinical Dental Research Organization.* 2010;2(3):157-60.
- [4] Naik, Bagewadi, Keluskar, Aggarwal. LIPOMA-SINGLET RING CELL TUMOR REVIEW OF 10 CASES. *Int J Dent Case Reports.* 2011; 1(2): 1-6.
- [5] Freitas MA, Freitas VS, Lima AA, Pereira FB, dos Santos JN. Intraoral lipomas: A study of 26 cases in a Brazilian population. *Quintessence Int.* 2009;40:79-85.
- [6] Ahmad Motagi, Atousa Aminzadeh, Seyed M. Razavi. Large oral lipoma: Case report and literature review in Iran. *Dental Research Journal.* 2012;9(3):350-2.
- [7] Hatziotis J Ch, Thassaloniki, and Greeze. Lipoma of the oral cavity. *Jr. of oral surg.* 1971;31(4):511-21.
- [8] Miles Dale A, Langlains Robert P, Aufdemorate Thomas B, Junfin Glass Birigit. Lipomas of the soft palate. *Oral Surg Oral Med Oral Path* 1984;57:77-80.

- [9] Sonia Egido Moreno, Ana Belen Lozano Porras, Siddharth Mishra, Marcos Allegue, Antonio Mari Roig, Jose Lopez Lopez. Intraoral lipomas: Review of literature and report of two clinical cases. *J Clin Exp Dent.* 2016 Dec; 8(5): e597–e603.
- [10] A Winnifred Christy, Anitha Bojan, Babu Mathew, MDS S Shanmugam. Lipoma in the Palate: A Rare Presentation. *Journal of indian academy of oral medicine and radiology,* Oct- Dec 2010;22[4]:S51-52