

A Neutral Zone Concept - An Overview

Dr. Anagha R. Dafade¹, Dr. Alhad I. Giradkar²

¹MDS Prosthodontist and Implantologist, Private Practitioner, Nagpur, Maharashtra, India

²MDS Conservative Dentistry and Endodontics, Private Practitioner, at Dr. Giradkar's Smile Studio, Nagpur, Maharashtra, India

Abstract: Providing complete denture therapy to patients with atrophic residual alveolar ridges is challenging. Because these patients suffer ongoing diminution of the denture foundation, modern approaches often involve dental implant therapy as a means of improving the denture foundation and supplementing the mechanics of prosthesis support, retention, and stability. Regardless of implant availability, physiologically optimal denture contours and physiologically appropriate denture tooth arrangement should be achieved to maximize prosthesis stability, comfort, and function for patients. The neutral zone technique for denture fabrication has an advantage that it stabilizes the denture with the surrounding musculature, instead of being dislodged by them. This article attempts to present historical overview on the concept of neutral zone in dentistry.

1. Introduction

The dimension of bone is under the influence of numerous systemic and local factors. Amongst these local factors are of direct concern to prosthodontists in the design of both complete and partial dentures. Many elderly patients present with severe alveolar resorption and their oral tissues may demonstrate severe age changes.¹

Because of the progressive changes that accompany edentulism, the functional dynamics that define the oral cavity, the loss of the patient's capability to adapt, and increased life expectancy, have posed a challenge for the dentist when restoring and rehabilitating the oral cavity.²

Neutral Zone Concept

Resorption of the residual ridges is a continuous process and produces a flat and sometimes concave foundation. This has been called the difficult lower jaw.^{2,45} In edentulous patients, support to the lips and the cheeks is no longer available and they tend to collapse into the oral cavity. Simultaneously, the tongue will try to expand into the space.² When all natural teeth have been lost, there exists within the oral cavity a void which is the potential denture space.²

A neutral zone is that area in the potential denture space where the forces of the tongue pressing outward are neutralized by the forces of the cheeks and lips pressing inward.² According to the Glossary of Prosthodontic Terms -9 the neutral zone is "the potential space between the lips and cheeks on one side and the tongue on the other; that area or position where the forces between the tongue and cheeks or lips are equal."³ (as shown in figure 1a and b)⁴

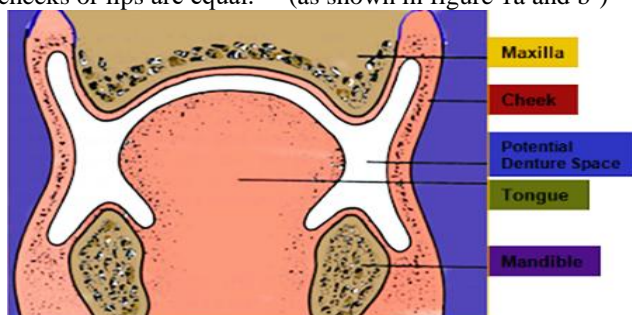


Figure 1 (a)

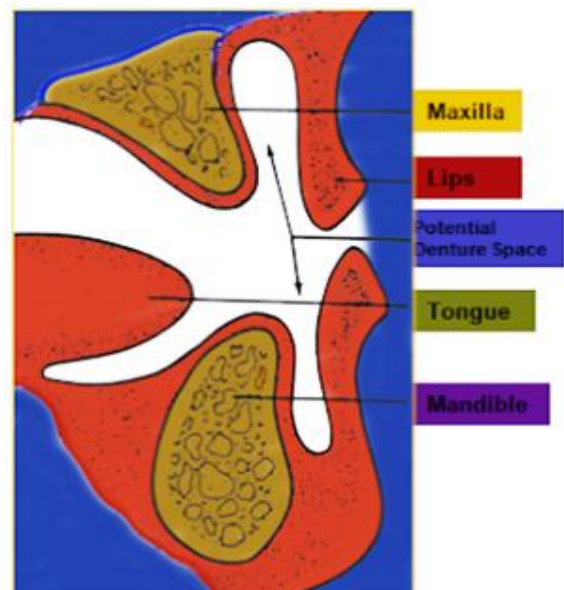


Figure 1 (b)

Figure 1: Potential denture space (neutral zone) a. cross section of molar area b. lateral view of incisor area⁴

The term 'neutral zone' was coined by Beresin and Schiesser in 1976.²

Historically, different terminology has been loosely associated with this concept, including dead space²⁹, stable zone³⁰, zone of minimal conflict, zone of equilibrium³², zone of least interference³¹, biometric denture space²⁷, denture space^{33,34}, and potential denture space.^{16,35,44}

It has been shown that neutral zone dentures are functionally more stable than conventional dentures^{45,47}. The position of the teeth in space and even the size and relationship of the jaws are controlled by the muscles. When natural teeth are lost, the shape and position of their artificial replacements must be determined by these same muscles, both in repose and function, if they are to be functionally successful.⁹

The denture space is bounded by the maxilla and soft palate above, by the mandible and floor of the mouth below, by the tongue, medially or internally, and by the muscles and tissues of the lips and cheeks laterally or externally.¹⁰

Peri-oral Musculature

Neutral Zone Philosophy is based upon the concept that for each individual patient, there exists within the denture space a specific area where the function of the **musculature** will not unseat the denture and where forces generated by the tongue are neutralized by the forces generated by the lips and cheeks.

The musculature of the denture space is divided into two groups as,

- (1) Those muscles which primarily dislocate the denture during activity . (Masseter, Mentalis, Incisive, Medial Pterygoid, Palatoglossus)
- (2) Those muscles that fix the denture by muscular pressure on its secondary supporting surfaces. (Buccinator, Orbicularis oris, Genioglossus)⁵

The outer limits of the neutral zone are determined by the perioral musculature. The main determinant of length, strength and position of the perioral musculature is the buccinator muscle. The buccinator is a thin, flat muscle composed of three bands.¹¹

The combined width of the three bands covers the entire outer surface of the dento alveolar structures, that is the teeth, alveolar process and gingival tissues.¹¹

The upper and lower bands are continuous from side to side without decussation. The middle band fibers decussate and join into the fibres of the orbicularis oris. Because the muscle fibers form a continuous band, the size of the arch is limited by the length of the muscles when they are contracted.¹¹

In the natural dentition, when, the mouth is passive, the **buccinator** is in contact with the buccal surfaces of the posterior teeth and with the mucosa covering the alveolar process.¹²

In function, as the buccinator contracts, the cheeks are pressed against the teeth and alveolar process. During mastication, the buccinator helps to place the food over the occlusal surfaces of the teeth in coordination with the tongue, which positions the food over the teeth from the lingual side.^{11, 46}

It has been suggested^{23,13,27,28} that long periods of edentulism modify the position of the neutral zone. The longer the period of edentulousness, the more buccally/labially located was the Neutral zone.²³

The common practice of centralization, or lingualization of occlusion, prevents the buccinator from performing its proper function in two ways. First, lingualization of occlusion creates a space between the cheek and the teeth and the external surface of the denture, where food tends to accumulate and it becomes more difficult for the cheek to place the food back onto the occlusal surfaces of the teeth. Secondly, the space resulting from lingualization prevents the buccinator from neutralizing the lateral forces of the tongue during function.

The lower jaw develops range of motion (lifting, lowering, protrusion, retraction, lateralization), influenced by muscles

responsible for chewing. The jaw elevation is performed by the masseter muscle, anterior temporal muscle and medial pterygoid muscle.

The masseter muscle fibers on contraction, project the jaw upward promoting contact between the dental arches. The chewing efficiency is guaranteed by the force exerted on the contraction of this muscle. Masseter muscle has no influence on the neutral zone but, it affects the distobuccal border of the denture. The jaw elevation is performed by the masseter muscle, anterior temporal muscle and medial pterygoid muscle^{11,49}

Orbicularis oris: To a great extent forms the lips. In function, as in chewing, smiling and swallowing, it exerts force against the teeth and denture flanges, which is counteracted by the tongue.¹¹

Caninus muscle: This together with other muscles, pulls the lower lip up and in sucking and swallowing helps to pull the lips forward, thus exerting forces on the teeth and labial denture flange.¹¹

- The greater zygomatic muscle pulls the angle of the, mouth upward and backward.
- The risorius muscle retracts the corner of the mouth.
- The mentalis muscle turns the lower lip outward and in contracting makes the lower labial vestibule shallow.

Because of the strength and variability of movement of the area, the modiolus is extremely important in relation to the stability of the lower denture. Unless the teeth and external surface of the denture are properly positioned and contoured by narrowing in the premolar area, the modiolus may constantly unseat the lower denture.¹¹

The tongue is composed of intrinsic muscles that lie within the tongue itself and extrinsic muscles that insert into the tongue. The function of the extrinsic muscles the styloglossus, palatoglossus, hyoglossus, and genioglossus- is to move the tongue into various positions. The tongue is capable of many varied shapes and positions during speech, mastication, and swallowing and in all of these functions is in constant contact with the lingual surface of the teeth, the lingual flange of the lower denture and the palatal surface of the upper denture. Because of this contact, the tongue is a dominant factor in establishing the neutral zone and therefore in the stability or .lack of stability of the lower denture¹¹

Denture Surfaces

Wilfred Fish¹ in described a denture as having **three** surfaces, with each surface playing an independent and important role in the overall fit, stability and comfort of the denture.

The first surface, the impression surface, is that part of the denture in contact with the tissues and on which the denture rests and determines retention of the denture,

The second surface, the occlusal surface is that area in contact with the teeth, either natural or artificial, of the opposite jaw. The stability of the denture when the teeth are in contact is determined by the fit of the impression surface

against the tissues and the fit of the occlusal surfaces against each other.

The third surface, the polished or external surface as termed by Fish, is all the rest of the denture that is not part of the other two surfaces. It is mostly denture base material, but it consists also of those surfaces of the teeth that are not contacting or articulating surfaces.

The buccal and lingual surfaces of the posterior teeth and the labial and lingual surfaces of the lower anterior teeth are not part of the occlusal surface but are part of the polished surface of the denture. The upper anterior teeth actually belong to two surfaces, both the occlusal and the polished surfaces. When the teeth are in contact, the lingual surfaces of the upper anterior teeth are part of the occlusal surface. When the teeth are apart, as in speaking as at rest, these surfaces are part of the polished surface.¹

The external surface is in contact with, the cheeks, lips and tongue. One can visualize that, based on a square unit of area, the external surface is as large or larger than the impression and occlusal surfaces combined, depending on the anatomic structures.¹

The more the ridge loss, the less the area of the denture base and the less the influence the impression surface area will have on the stability and retention of the denture. As the surface area of the impression surface decreases and the external surface area increases, the development and contour of the external surface becomes more critical.¹³

The forces on the external surface are constantly changing in magnitude and direction during swallowing, speaking and mastication. It is only when the mouth is completely at rest, that the forces are constant.¹³

In order to construct dentures that function properly not only in chewing but also in speaking and swallowing, we must develop the fit and contour of the external surface of denture just as accurately and meticulously as the fit and contour of the impression surface and the occlusal surface.¹³

The influence of the lip on the lower denture stability becomes more critical as resorption of the ridge increases or as the patient becomes older.

In addition, as patient age, the lip instead of being averted as in young individuals becomes thinner and inclines backward into the mouth. So, It is obvious that if we do not determine the neutral zone, and as a result the teeth and flanges are not properly positioned and contoured, the force exerted from the lower lip may constantly unseat the lower denture.¹¹

The lower posterior teeth are drastically affected by the position of the tongue. If the lower posterior teeth are lingualized excessively, normal tongue function will immediately unseat the denture. The tongue cannot and should not be restricted by the position of the posterior teeth.¹¹

A force exerted on an inclined plane may be broken down into two components. One component acts in the direction

parallel to the inclined plane. The other component, called normal force, acts perpendicularly to the inclined plane. If the inclined planes of the external surface are properly fashioned and the forces are of equal magnitude, the resultant normal force will be in a seating direction. By the same concept, if the dentures are triangular but not properly located within the neutral zone, the lateral force will be unequal and not provide the equilibrium necessary for a stable denture. This will result either in the dislodgement of the denture or unequal pressure on the ridge.¹¹

Techniques

Many techniques have been suggested using the previously described materials in conjunction with movements²². Beresin VE and Schiesser FJ⁶ has described that in neutral zone technique the usual sequence of complete denture construction is somewhat reversed. Individual trays are constructed first and adjusted in the mouth for stability during opening, swallowing, and speaking. Next, modeling compound is used to fabricate occlusion rims. These rims, which are moulded by muscle function, locate the patient's neutral zone. After a tentative vertical dimension and centric relation have been established⁴⁸. The mandibular neutral zone is indexed with plaster placed on the buccal and lingual surfaces. Teeth are set up exactly following the index. The final impressions are made with a closed-mouth procedure.

The techniques most commonly used for recording the neutral zone were found to be swallowing¹⁷ and phonetics. However, other techniques such as sipping water, licking, smiling¹⁸, pursing the lips¹⁹, sucking²², masticating²⁰, mouth exercises (including tongue movements, blowing, protruding of the tongue, exercise movements of the lips, cheek, and tongue, facial expression, opening and closing and whistling^{21,24,47} have also been reported.

2. Materials

Tench et al (1953) were the first in this field and have proposed modeling plastic impression compound as the material to be used for recording the neutral zone²⁴. Although this advice is widely followed, other materials such as tissue conditioner^{17, 36,50}, wax^{37,38}, zinc oxide eugenol impression material^{37,39,40}, silicone material^{10,25,41}, chairside relining material⁴² and acrylic resin⁴³ are also used for this procedure.¹⁰

Modeling plastic impression compound, being a thermoplastic material, is easy to manage and has the advantages of low cost and ease of availability, whereas wax is temporarily stable and can be contoured over a period of time by functional movements. A tissue-conditioning material was preferred by many authors because of the ease of mixing, elective initial viscosity, and slow-setting properties that enabled capture of the movable tissue morphology in the functional state. Moreover, this material also allows for an incremental molding procedure, which is important in patients with focal neurological deficits and slow or false reactions to various commands. A disadvantage of this material is its relatively high cost. Light-polymerized acrylic resin provides sufficient working

time and polishes to a high luster; however, irritation due to the monomer may be a problem.¹⁰

The admix material allowed better flow and an accurate molding.¹¹ It is a combination of impression compound and green stick (low-fusing) compound in the ratio of 3:7. The mixing of a low-fusing compound with the impression compound results in a low viscosity material allowing for ease in manipulation of the oral musculature.

Index Material

Once the neutral zone has been recorded, its position can be preserved with the help of indexing material like plaster^{6,25}, silicone²⁵, stone^{17,21,26} or modeling plastic impression compound^{1,6, 13}. These indices help to preserve the neutral zone while teeth arrangement procedures. In the study, three plaster indices were prepared one covering the lingual aspect and another two each covering buccal aspect upto midline which helped in easy removal and placement.¹⁴

Teeth selection

While teeth arrangement anatomic, semianatomic and non-anatomic tooth forms are available. Anatomic tooth resembled natural teeth with transverse ridges intended for tight interdigitation. Also called as “cusp teeth”. It is designed to simulate the occlusal surface of the natural tooth. Available in varying degree of inclinations – the standard is approximately 33°. The angle can be modified by grinding or purchased in a modified anatomic form. When the cusp incline is less than the conventional 33°, it is termed as modified anatomic or semi anatomic teeth. Non-anatomic teeth. They are also called the “cusplless”, “monoplane” or “zero degree” teeth. The occlusal surface is essentially flat and has no cusp heights. Non anatomic teeth often indicated in patients with poor neuromuscular coordination, weak denture base foundation, bruxism etc.¹⁵

Polished Surface Recording-

Usually, the contours of the external surfaces of dentures are arbitrarily determined by the dentist or technician. With the neutral-zone procedure, the external contours are molded by muscle function⁶. The moldable material used to locate the neutral zone also determines the shape of the arch and the angles and contours of the body of the denture⁶.

3. Conclusion

Based on the literature overview it can be concluded that with period of endentulism results in perioral musculature tends to shift more buccally from its original position and any complete denture that interferes with the actions of these surrounding muscles will therefore lack stability. In such situations, it can be assumed that the muscle activity will uplift the denture in patients when wearing conventional complete dentures as teeth are not set in neutral zone than compared with satisfactory dentures fabricated using the neutral zone techniques.

References

[1] Schiesser FJ ; The neutral zone and polished surfaces in complete dentures. J Prosthet Dent. 1960 Sep; 14(5): 854–65.

- [2] Martone AL; clinical applications of concepts of functional anatomy and speech science to complete denture prosthodontics; J. pros. den.;sept.-oct., 1962
- [3] The Glossary of Prosthodontic Terms. J Prosthet Dent. 2017 May;117(5):C1-e105.
- [4] Csogor A, Michman J. Initial retention of complete mandibular dentures. J Prosthet Dent. 1970 May;23(5):503–11.
- [5] Murrell GA. The management of difficult lower dentures. J Prosthet Dent. 1974 Sep;32(3):243–50.
- [6] Beresin VE and Schiesser FJ; The neutral zone in complete dentures. J Prosthet Dent. 1976;12.
- [7] Helling G, Dr O, Klineberg I. The masseter muscle: The silent period and its clinical implications. J Prosthet Dent. 1983;49(1):7
- [8] Pk D, R S The Supple Elucidation of Neutral Zone by Tissue Conditioners - A Case Report. Int J Dent Oral Sci. 2015 Sep 10;155–7.
- [9] Singh DNK, Bathala DLR, Rao DRS. Neutral Zone in Complete Dentures.
- [10] Cagna DR, Massad JJ, Schiesser FJ. The neutral zone revisited: From historical concepts to modern application. J Prosthet Dent. 2009 Jun;101(6):405–12.
- [11] Muddugangadhar B, Tripathi S, Amarnath G et al. Zone of Minimal Conflict: The Mystery Unveiled - An Overview. J Dent Allied Sci. 2013;2(1):24.
- [12] Dutra EH, Caria PHF, Rafferty KL, et al . The buccinator during mastication: A functional and anatomical evaluation in minipigs. Arch Oral Biol. 2010 Sep;55(9):627–38.
- [13] Raja HZ, Saleem MN. Effect of previous denture wearing on neutral zone morphologies. Pakistan Oral and dental journal Vol. 34 , No. 4(dec.2014)
- [14] Gupta KL, Agarwal S. Salvation of a severely resorbed mandibular ridge with a neutral zone technique. Indian J Dent Res [serial online] 2011 [cited 2018 Oct 20];22:883
- [15] Wright WH. Selection and Arrangement of Artificial Teeth for Complete Prosthetic Dentures Feb. 19, 1936. J Am Dent Assoc 1922. 1936Dec;23(12):2291–307.
- [16] Agrawala KK, Singh SV, Vero N, Alvi HA, et al. Novel registration technique to register neutral zone; Journal of Oral Biology and Craniofacial Research 2012 September-December Volume 2, Number 3; pp. 198e202
- [17] Miller WP, Monteith B, Heath MR. The effect of variation of the lingual shape of mandibular complete dentures on lingual resistance to lifting forces. Gerodontology 1998;15:113-9.
- [18] Gahan MJ, Walmsley AD. The neutral zone impression revisited. Br Dent J 2005;198:269-72.
- [19] Ohkubo C, Hanatani S, Hosoi T, Mizuno Y. Neutral zone approach for denture fabrication for a partial glossectomy patient: a clinical report. J Prosthet Dent 2000;84:390-3.
- [20] Lynch CD, Allen PF. Overcoming the unstable mandibular complete denture: the neutral zone impression technique. Dent Update 2006;33:21-2, 24-6.
- [21] Russell AF. The reciprocal lower complete denture. J Prosthet Dent 1959;9:180-90.
- [22] Fahmy F.M. kharat, D. U. A study of the importance of the neutral zone in complete dentures; Jprosth Dent 1990;64:459-62

- [23] Fahmi F. M., The position of the neutral zone in relation to the alveolar Ridge; J Prosthet Dent 1992; 67:805-9.
- [24] Porwal A and Jain P ;Neutral Zone Approach for Rehabilitation of Severely Atrophic Ridge;International Journal Of Dental Clinics 2010; 2 (3)
- [25] McCord JF, Grant AA. Impression making.Br Dent J 2000; 188:484-92.
- [26] Stromberg WR, Hickey JC. Comparison of physiologically and manually formed denture bases. J Prosthet Dent 1965;15:213-30.
- [27] Watt DM. Tooth positions on complete dentures. J Dent 1978;6:147-60.
- [28] Demirel F, Oktemer M. The relations between alveolar ridge and the teeth located in neutral zone. J Marmara Univ Dent Fac 1996;2:562-6.
- [29] Fish EW. Principles of full denture prosthesis. London: John Bale, Sons & Danielsson, Ltd; 1933. p. 1-8.
- [30] Brill N, Tryde G, Cantor R. The dynamic nature of the lower denture space. J Prosthet Dent 1965;15:401-18.
- [31] Wright SM. The polished surface contour: a new approach. Int J Prosthodont 1991;4:159-63.
- [32] Grant AA, Johnson W. An introduction to removable denture prosthetics. Edinburgh: C. Livingstone; 1983. p. 24-8.
- [33] Schlosser RO. Complete denture prosthesis. Philadelphia: WB Saunders Company; 1939. p. 183-90.
- [34] Heath R. A study of the morphology of the denture space. Dent Pract Dent Rec 1970;21:109-17.
- [35] Roberts A. The effects of outline and form upon denture stability and retention. Dent Clin North Am 1960;4:293-303.
- [36] Ikebe K, Okuno I, Nokubi T. Effect of adding impression material to mandibular denture space in Piezography. J Oral Rehabil 2006;33:409-15.
- [37] Walsh JF, Walsh T. Muscle-formed complete mandibular dentures. J Prosthet Dent 1976;35:254-8.
- [38] Raybin NH. The Polished Surface of Complete Dentures. J Prosthet Dent 1963;13:236-9.
- [39] Pekkan G, Hekimoglu C, Sahin N. Rehabilitation of a marginal mandibulectomy patient using a modified neutral zone technique: a case report. Braz Dent J 2007;18:83-6.
- [40] Barone JV. Physiologic complete denture impressions. J Prosthet Dent 1963;13:800-9.
- [41] Suzuki Y, Ohkubo C, Hosoi T. Implant placement for mandibular overdentures using the neutral zone concept. Prosthodont Res Pract 2006;5:109-12.
- [42] Makzoum JE. Morphologic comparison of two neutral zone impression techniques: a pilot study. J Prosthet Dent 2004;92:563-8.
- [43] Makzoum JE. Complete denture prosthodontics for a patient with Parkinson's disease using the neutral zone concept: a clinical report. Gen Dent 2008;56:12-6.
- [44] Atwood DA. Post extraction changes in the adult mandible as illustrated by micrographs of midsagittal sections and serial cephalometric roentgenograms. J Prosthet Dent 1963; 13: 810-824.
- [45] Dafade AR, Dhamande MM, Godbole SR et al Fabrication of Complete Denture with Neutral Zone Technique for a Difficult Lower Jaw, Sch. J. Dent. Sci., Vol-5, Iss-11 (Nov, 2018): 514-520
- [46] Dhamande MM, Dafade AR, Sathe S et al Electromyographic analysis of buccinator muscle activity in denture wearer and non-denture wearer by fabricating dentures with neutral zone technique (An in-vivo study), Central India Journal of Dental Sciences Vol. 8 Issue 2 July - Dec 2017
- [47] Reddy D, Kumar R, Reddy RN et al, Patients satisfaction with complete denture fabrication using two neutral zone impression material-an in vivo study; 10/5368; 2014.6.3.1.1
- [48] Alfano S.G. and Leupold R.J. ; Using the neutral zone to obtain maxillomandibular relationship records for complete denture patients; The Journal Of Prosthetic Dentistry ; June 2001
- [49] U. C. Belser ; The contribution of the deep fibers of masseter muscle to selected tooth clenching and chewing tasks; The Journal of prosthetic dentistry 1986
- [50] Kursoglu P, Ari N. , Calikkocaoglu S ; Using Tissue Conditioner Material In Neutral Zone Technique; Nysdj • January 2007

Author Profile



Dr. Anagha R. Dafade, MDS Prosthodontist and Implantologist, Private Practitioner, Dr. Giradkar's Smile Studio, Sitabuldi, Nagpur