

# Case Report of Arnold-Chiari Malformation Presenting with Multiple Motor and Dynamic Sensory Symptoms

Dr. V. K. Katyal<sup>1</sup>, Dr. Bharti<sup>2</sup>, Dr. Angshuman Mukherjee<sup>3</sup>, Dr. Manish Kumar<sup>4</sup>, Dr. Banoth Sridhar<sup>5</sup>

<sup>1</sup>Senior Professor and Head, Department of Medicine, PGIMS, Rohtak, India

<sup>2</sup>Junior Resident – III, Department of Medicine, PGIMS, Rohtak, India

<sup>3, 4, 5</sup>Junior Resident -II, Department of Medicine, PGIMS, Rohtak, India

**Abstract:** *The involvement of the cervico-medullary junction leading to atypical motor and sensory features presents a clinical conundrum and diagnostic challenge to the physician. We hereby present a case of platybasia with syringomyelia as a result of dynamic cervico-medullary junction obstruction leading to ataxia with cranial nerve involvement as well as with dynamic sensory symptoms in a 31 year old Indian male falling in the Arnold-Chiari malformation spectrum.*

**Keywords:** platybasia, syringomyelia, cervico-medullary junction, chamberlain's line, mcgregor's line, Arnold-Chiari malformation

## 1. Introduction

The dynamic obstruction of the cervico-medullary junction presents an interesting challenge for clinical diagnosis. Though classically presenting with headache mostly beginning in the suboccipital region, the nature of dynamic obstruction results in varied clinical features including the involvement of cranial nerves as well as features of upper cord syndrome. This makes the localisation of the lesion a case of interesting diagnostic challenge. We present here a case of a 31 year old male who was initially suspected with brainstem involvement but on further evaluation revealed itself as a case dynamic obstruction of the cervico-medullary junction due to dysregulation of CSF circulation as a result of platybasia.

## 2. Case Report

A 31 year old male patient was brought to the General Medicine OPD with chief complaint of Right sided weakness associated with difficulty in walking properly and turning around for the last 5 years. The patient states that the weakness began in the Right Upper Limb which progressed to involve the Right and Left Lower limbs with aggravation of features over the last 1 month. The patient had sought treatment from multiple practitioners but with no relief of symptoms. The patient's attendant gives a history of taking tablet Omnacortil (oral steroid) and tablet Eptoin (oral phenytoin) as prescribed by some local practitioner. This was no history of vertigo, difficulty in reading, writing, diplopia, visual disturbance, hearing loss, dysphagia, dysarthria, dysphonia, shoulder weakness, involuntary movements, seizure, incontinence, aphasia, symptoms of dysautonomia, or personality, mood or behaviour changes. The patient did not have any significant family history.

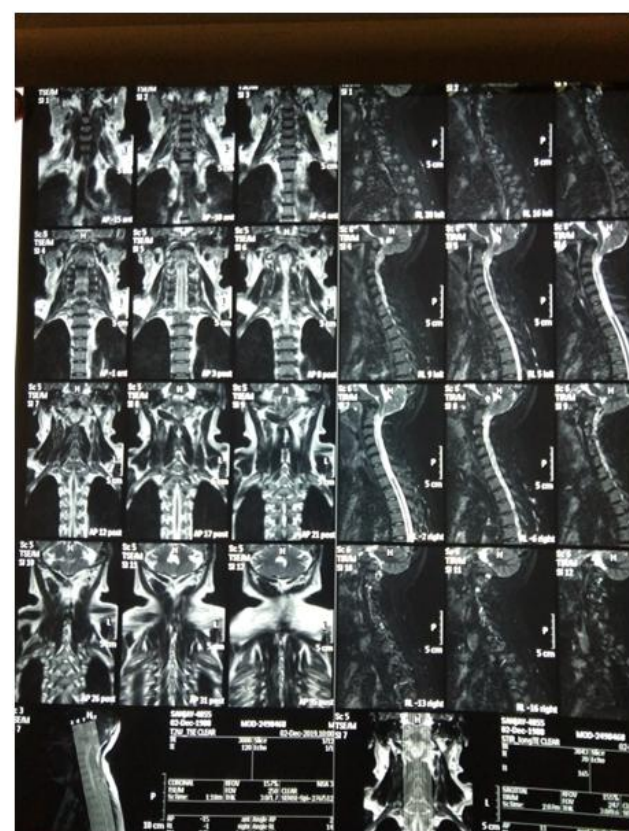
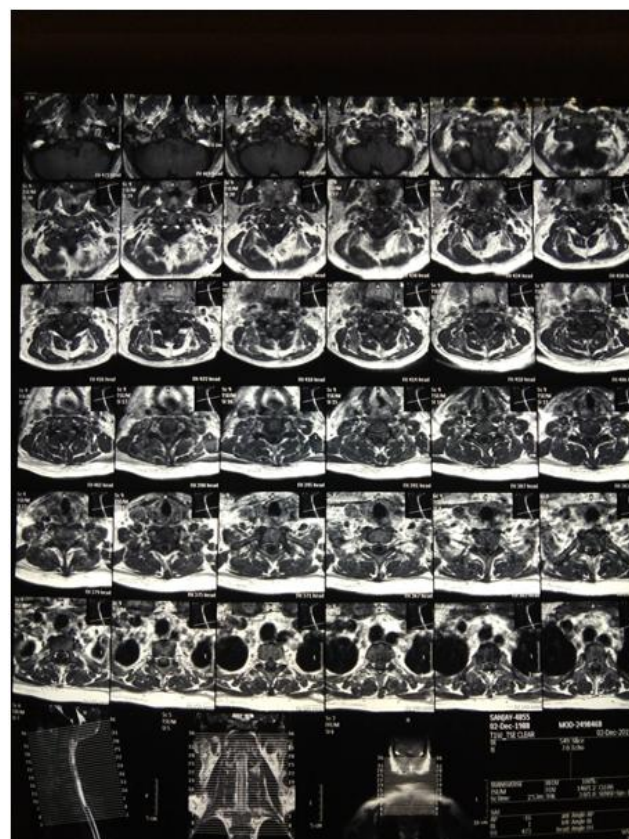
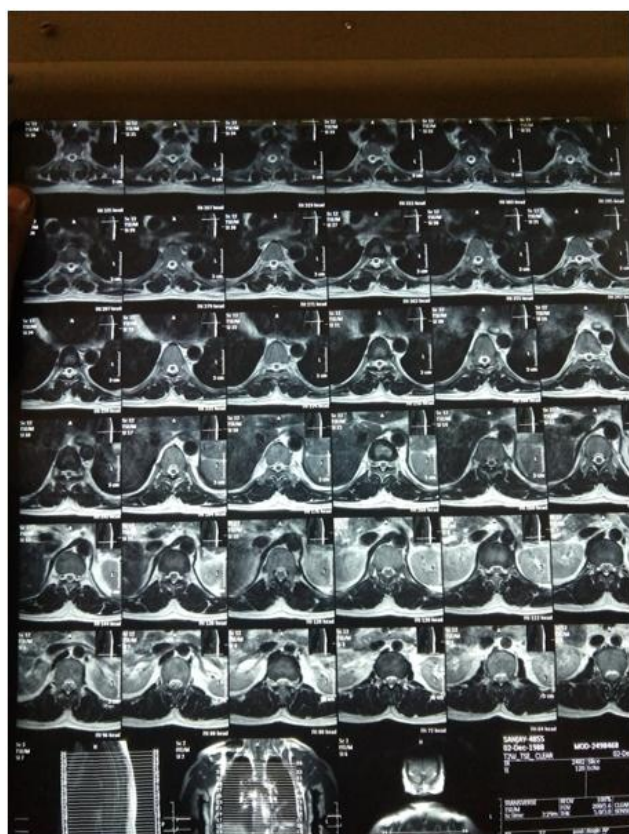The patient was conscious, oriented and co-operative with a blood pressure of 150/74 mm Hg and a pulse rate of 84/minute with regular rhythm, afebrile with a respiratory rate of 20 breaths/minute. There was no pallor, icterus, clubbing,

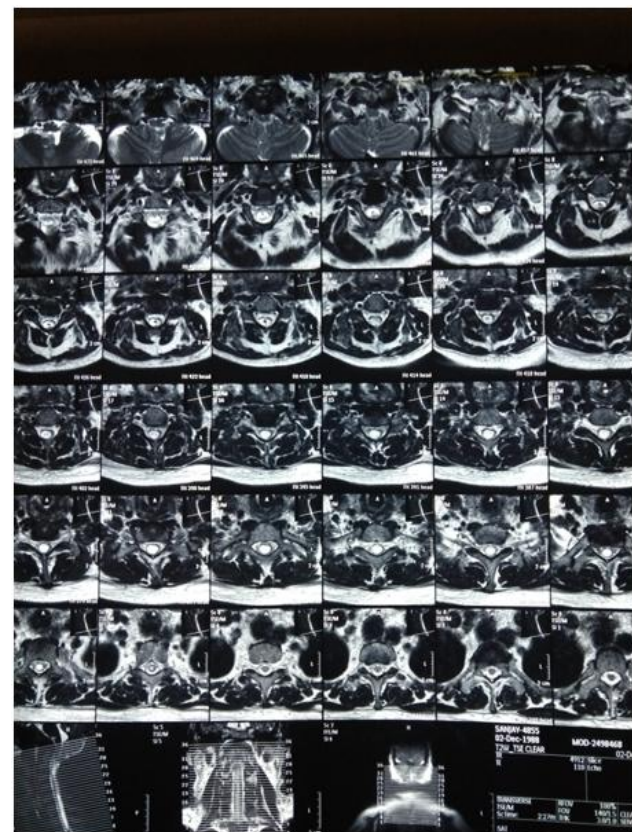
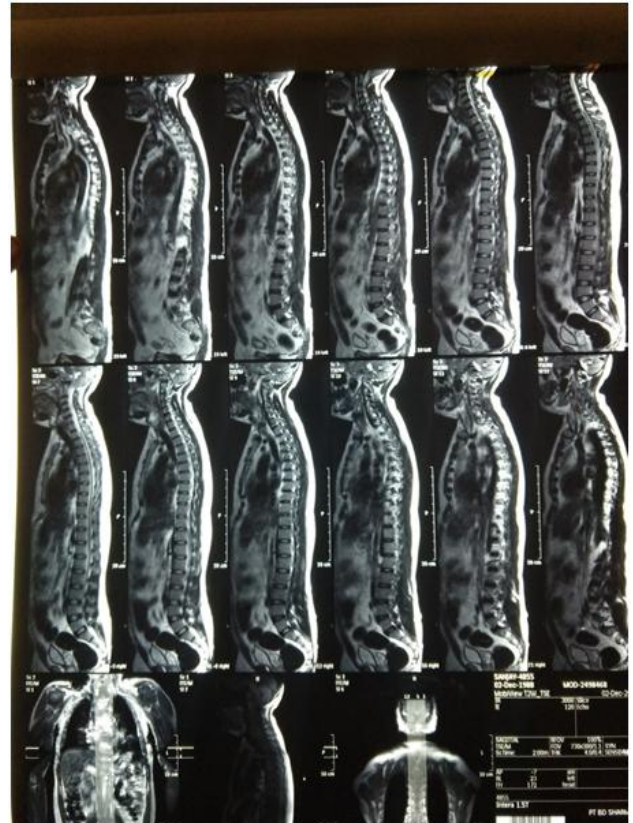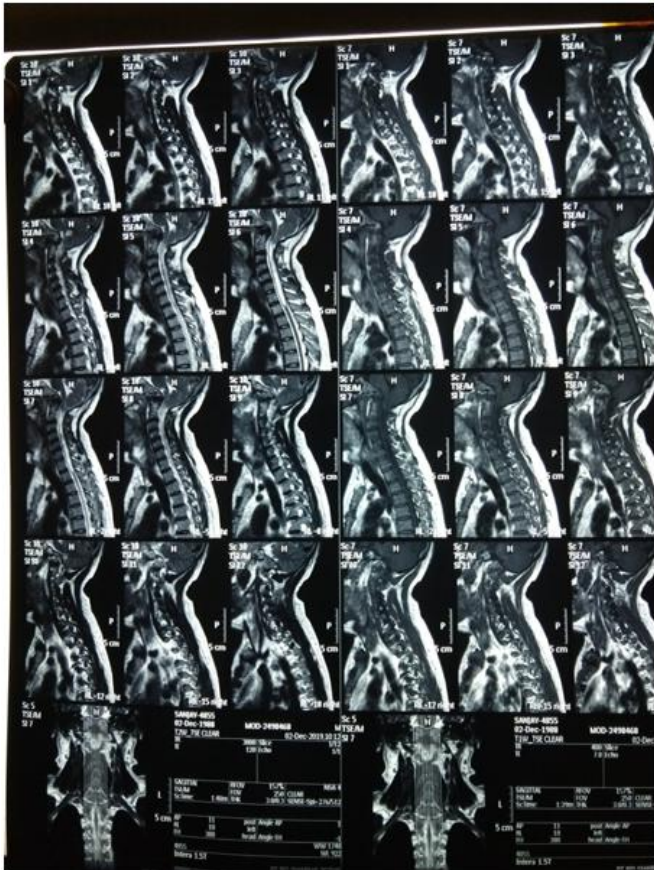cyanosis, lymphadenopathy or raised jugular venous pressure or pedal edema. Neurological evaluation revealed normal pain and temperature sensation with decreased fine touch sensation in bilateral upper limb and thorax. On inspection, the finger of the upper limb were found to maintain a resting posture of painless exaggerated flexion to varying degrees with restriction of voluntary motion but was amenable to painless passive flexion. Bilateral Plantar reflex was found to be flexor with clasp knife rigidity in all 4 limbs. Further examination of Right side upper and lower limb power was 4/5 and left sided upper and lower limb power was 5/5. Examination of reflexes revealed bilaterally symmetrical exaggerated upper limb reflexes with clonus in the right lower limb and 4+ deep tendon jerk in left lower limb.

The patient was advised a Non-Contrast CT Scan of Head, MRI Brain, thrombophilia profile, lipid profile along with routine blood investigations. The thrombophilia and lipid profile was done in view of the relatively young age of the patient and due to multiple sites of neurological involvement on clinical examination; a suspicion of thrombotic disorders leading to multiple arterio-venous infarcts was kept. The follow up visit revealed the development of brisk pendular nystagmus in all positions of gaze with bilateral lower limb clonus but equal and symmetrical bilateral lower limb reflexes. Sensory examination revealed the spontaneous recovery of fine touch over thorax but not on upper limbs. Routine blood investigations along with thrombophilia and lipid profile were within normal limits and NCCT brain revealed non specific hyperintensity of Right cerebellum. Fundus examination was not suggestive of any raised ICT. Mantoux and VDRL was non reactive with an ESR of 8 mm excluding inflammatory pathologies. MRI Brain was however delayed due to financial constraints of the patient.

The next follow-up visit in two weeks revealed similar motor findings with sensations decreased upto L2 level with dorsiflexion during plantar response. Consultation was taken from the Department of Neurosurgery upon whose advise Dynamic CT of the Cervico-Vertebral Junction and Cine

MRI of the Cervico-Vertebral Junction for the study of CSF flow was done. The CT of the CV junction revealed complete fusion of atlas and occiput on both sides with the tip of the dens being above the Mc Gregor's / Chamberlain's line with posterior subluxation which was suggestive of basilar invagination. The Cine MRI revealed a syrinx formation at the C2-D1 level with CSF flow on phase contrast. The MRI was also suggestive of atlanto-occipital assimilation with basilar invagination with cerebellar tonsillar herniation (2 mm below the foramen magnum) with crowding at the foramen magnum. Thus a diagnosis of Chiari I malformation with a high flow syrinx as C2-D1 level with atlanto-occipital invagination with platybasia along with basilar herniation was made. The patient was referred to a higher centre in view of unavailability of the setup for fixation of the dynamic block.





### 3. Discussion

Platybasia is defined as flattening of the skull base. Clinically it is defined with respect to the skull base angle which is measured as the angle between the line joining the nasion to the centre of the pituitary fossa and the line joining the centre of the pituitary fossa to the anterior border of the foramen magnum. Measured most accurately with an MRI, its normal value is taken to be between 125-143 degrees with values more than 143 degrees being diagnostic of platybasia. The Chamberlain's line is defined as the line joining the posterior edge of the hard palate to the ophisthion( midline of the posterior boundary of the foramen magnum ). The McGregor's line is defined as the line joining the posterior edge of the hard palate with the lowest point of the occipital curve. Basilar invagination is the upward migration of the tip of the odontoid process (dens) above the foramen magnum. With the aid of the aforementioned landmarks we can radiologically define basilar invagination as the presence of the tip of the dens more than 5 mm above the Chamberlain's line or more than 7 mm above the McGregor's line (1).

The Arnold-Chiari malformations are a group of disorders characterised by a "variable displacement of a tongue of tissue, derived from the inferior cerebellar vermis, into the upper cervical canal accompanied by a similar caudal dislocation of the medulla, and fourth ventricle, the medulla often showing a "kink-like" deformity"(2).

Thus depending on the degree and the number of structures involved they Arnold-Chiari group of malformations can be subdivided into the following subtypes(2):

- Chiari Type 0 malformation: This is characterized by an altered cerebrospinal fluid (CSF) dynamics at the level of the foramen magnum. Patients with this type have syringomyelia without tonsillar herniation or with only mild tonsillar herniation associated findings
- Chiari Type 1 malformation: There is herniation of the cerebellar tonsils more than 5 mm below the foramen magnum. There is usually an associated syringomyelia. It is not usually associated with brainstem or fourth ventricular herniation or hydrocephalus
- Chiari Type 1.5 malformation: specifically describes patients with Chiari Type I malformations but with the addition of an elongated brainstem and fourth ventricle
- Chiari Type 2 malformation: This is characterized by caudal herniation of the cerebellar tonsils, brainstem, and fourth ventricle through the foramen magnum. It is mostly accompanied by myelomeningocele, hydrocephalus, and sometimes syringomyelia
- Chiari Type 3 malformation: This consists of occipital encephalocele
- Chiari Type 4 malformation: This consists of cerebellar aplasia or hypoplasia associated with aplasia of the tentorium cerebelli.

The commonest of the above 6 types is the type 1 malformation associated with the formation of syringomyelia which is the development of a CSF filled cavity in one or more spinal cord segments which may or may not extend into the brain. The development of the syrinx in Chiari Type 1 malformations is attributed to the altered CSF hydrodynamics as a direct result of the altered structure of the base of the skull. The search for the cause of the altered hydrodynamics has elicited various theories none of which fully explain all the clinical correlates of this disorder. Some of the more relevant ones include the Goel's theory of chronic atlanto-occipital insufficiency leading to compensatory Chiari malformation and Oldfield's theory of obstruction to diastolic flow of CSF (2).

The commonest features of presentation of this subtype are oppressive suboccipital headache aggravated by Valsalva manoeuvres and neck pain often associated with sensory dyesthesias such as a deep seated burning sensation over shoulder, napes and upper limbs. However the involvement of cranial nerves is rare and other symptoms of tract involvement may be present to varying degrees (3).

The associated syrinx formation in Type I Chiari malformation is not only associated with mass effect on the traversing spinal tracts but also with dynamicity of CSF flow obstruction. This dynamicity of CSF flow obstruction with the attendant variable degrees of compression may manifest in various ways which include dynamic compression of the white matter tracts presenting as central cord syndrome due to syringomyelia, variable degrees of cerebellar tonsillar herniation with dynamic ingress and egress of the tonsils(4), asymptomatic elevation of optic nerve head on fundus examination (4), left vocal cord palsy along with left CN XII palsy with gait ataxia and posterior column impairment(5). The associated long-standing compression of the cerebellum has also been implicated in cognitive dysfunction as measured by dysregulated response inhibition evidenced by the Stroop test in post neurosurgery patients of long standing Chiari malformation(6). Our aim in presenting this case lies

in our efforts to highlight the rarity of the atypical presentation of this disorder which involve dynamic changes of the clinical manifestations.

## References

- [1] Pearce JMS. Platybasia and basilar invagination. *Eur Neurol.* 2007;58(1):62–4.
- [2] Toru Y, Herve C, Pierre-Marie, Longis Toshihiro T, Joël D. Posterior instrumented fusion surgery for adult spinal deformity: Correction rate and total balance. *J Craniovertebral Junction Spine.* 2017;10(1):291–4.
- [3] Fernández AA, Guerrero AI, Martínez MI, Amado Vázquez ME, Fernández JB, Chesa I Octavio E, et al. Malformations of the craniocervical junction (chiari type i and syringomyelia: Classification, diagnosis and treatment). *BMC Musculoskelet Disord.* 2009;10(SUPPL. 1):1–11.
- [4] Antonucci MU, Drohan A. Dynamic Cerebellar Tonsils in Chiari Malformation. *J Pediatr [Internet].* 2019;206:295. Available from: <https://doi.org/10.1016/j.jpeds.2018.11.020>
- [5] Sneha Chitra Balasubramanian CS, Saphiya NN, Madan A, Mathews SS, Nair AR. Complex Chiari Malformation Presenting with Bulbar Symptoms in an Adult: Single-stage Posterior Fusion and Foramen Magnum Decompression: A Rare Case Report. *Asian J Neurosurg.* 2018;13(2):29682044.
- [6] Allen PA, Houston JR, Pollock JW, Buzzelli C, Li X, Harrington AK, et al. Task-specific and general cognitive effects in chiari malformation type I. *PLoS One.* 2014;9(4):1–11.