

To Study the Outcome of Cyanoacrylate Glue in Different Corneal Pathologies

Dr Pankti S Shah¹, Dr Pinkal D Ratpiya², Dr Komal S Bagrecha³

^{1, 2, 3} Year Resident Doctor, C.H Nagri Eye Hospital

Abstract: *The cyanoacrylates were first synthesized in 1949 by H. Coover. The main advantage of synthetic tissue adhesives is cheap and simple production process, which gives possibility of using the cyanoacrylates in many surgical disciplines of medicine. That makes also synthetic tissue adhesives better than biological tissue glue (for example fibrin- based adhesives) which preparation is much more complicated and expensive. Nowadays the cyanoacrylates are often used in ophthalmology, mostly in treatment diseases of the anterior segment--for example corneal thinning, ulceration and perforation of cornea. In this paper possible uses of cyanoacrylate tissue adhesives in ophthalmology are presented. The method of application of the cyanoacrylates on the surface of damaged cornea is presented. On base of analysis provided in many clinical centres, the advantages, disadvantages and clinical effects of using tissue adhesives are discussed in this paper.*

Keywords: Cyanoacrylate Glue, Bandage Contact Lens, Corneal Perforations, Corneal Ulcer

1. Introduction

Perforations and impending perforations are corneal pathologies that require urgent intervention. Surgery on inflamed or infected eyes does not offer the most optimal prognosis as there is increased risks of infection, synechia formation, and secondary glaucoma.

The use of tissue adhesive offers an alternative as either a temporizing procedure or definitive treatment.

Cyanoacrylate tissue adhesives (CTAs) are used to treat corneal perforations and thinning and have been tried in other types of ophthalmic surgeries. Treatment options depend on the size of the corneal perforation.

Corneal perforations up to 3.0mm have been treated successfully with the use of cyanoacrylate tissue adhesive. The management of larger perforations (>3.0 mm) remains a challenge.

For larger perforations, urgent Tectonic/ Therapeutic procedures are preferred. The effective early application of a cyanoacrylate glue corneal patch can aid in the management of small corneal perforations, corneal melts and wound leaks. Use of Cyanoacrylate Glue has shown to improve visual outcomes and reduce enucleation rates (6% versus 19%). It may also avoid the need for tectonic penetrating keratoplasty. Cyanoacrylates also have significant bacteriostatic activity against Gram-positive organisms. In larger corneal perforations, there is a risk of inadvertent entry of the corneal glue into the anterior chamber, possibly leading to cataract formation, glaucoma, or granulomatous keratitis. In addition, the CTA adhesive plug may not stay in position because of lack of an underlying tissue scaffold.

With corneal application, the major concern is toxicity of cyanoacrylates through direct contact with the corneal endothelium and lens. Monitoring for infection/corneal infiltrate is necessary at all times, especially when the glue has been present for more than 6 weeks.

2. Aims and Objectives

- 1) To evaluate the Outcome of application and use of Isoamyl-2 cyanoacrylate tissue adhesive in the management of corneal pathologies.
- 2) To find out different corneal conditions where glue application is effective in management.
- 3) To evaluate change in anterior chamber depth before and after application of Isoamyl-2 cyanoacrylate tissue adhesive.
- 4) To look for any complications related to Isoamyl-2 cyanoacrylate tissue adhesive

3. Materials and Methods

Type of study: This is a Prospective Observational study carried out for a period of 7 months.

Methods: All consecutive patients presenting with corneal perforations managed at a tertiary care centre between July 2019 and January 2020 were included. At initial presentation, all cases underwent a detailed clinical evaluation including obtaining clinical history, recording of visual acuity, and slit-lamp biomicroscopy.

Inclusion Criteria

Patients of all age group

All patients having corneal perforations ≤ 3 mm with

- Positive Seidel's test.
- Post traumatic sealed corneal perforations.
- Infected Corneal Ulcers.
- Infectious corneal perforations.
- Descemetocoele.
- Impending Perforation with Negative Seidel's test.
- Lamellar Corneal Perforation with Negative Seidel's

Exclusion Criteria

Corneal perforations >3mm in size

Materials Required

- 1) 2- isoamyl cyanoacrylate glue
- 2) Bandage Contact Lens
- 3) Slit Lamp microscope
- 4) 26- Gauge needle
- 5) Tuberculin syringe
- 6) Topical Anaesthetic agent (Proparacaine 0.5% eye drops)
- 7) Topical Antibiotic (Ofloxacin 0.3% eye drops)

Application of Glue (including patient preparation)

- 1) Topically anaesthetize the eye (Proparacaine 0.5% eye drops).
- 2) Take the glue in 2 cc syringe and 26 G needle.
- 3) Dry the ocular surface
- 4) Apply a small amount of glue to the centre of corneal perforation. Remove excess glue.
- 5) Apply a Bandage contact lens over it.
- 6) Instill antibiotic eyedrops.

Post Glue Management

- 1) Monitor for infection/infiltrate carefully.
- 2) Prophylactic topical antibiotics were given to all patients.
- 3) Close follow up of 2 days was given initially.
- 4) Documentation of change of anterior chamber depth.
- 5) Removal of glue was done between 7 days to 3 months

4. Observations and Results

All patients diagnosed as Corneal Perforation attending the Cornea outpatient department have been screened between July 2019 and January 2020. Total 33 patients who had corneal perforation or impending corneal perforation and fulfilling the inclusion criteria were enrolled in the study.

Sex Distribution

Sex	No. of Patients
Male	24 (72.72%)
Female	9 (27.2%)
Total	33

History of Trauma

Out of 33 patients who underwent Cyanoacrylate Glue procedure, History of Trauma in any form (Chemical Injury, Mechanical Injury, Fall of Foreign Body, Insect Bite) was present in 13 patients.

History of Systemic Illness

Of the total of 33 patients, 2(6%) patients had Rheumatoid Arthritis, 1(3%) patient had Sjogren's syndrome, 1(3%) patient had Hypothyroidism and 2(6%) patients had Diabetes Mellitus

History of Ocular Illness

The total of 33 patients, 3(9%) patients had Dry eyes, 1(3%) patient had endophthalmitis for which Intravitreal Antibiotics were given, 1(3%) patient had healed corneal ulcer, 1(3%) patient had Retinal Detachment and 1(3%) patient had Thyroid Eye Disease.

Cause of Corneal Perforation

Of total 33 patients, 13(39%) had Trauma, 4(12%) had Peripheral Ulcerative Keratitis, 10(30%) had History of

Ulcer and 6 (18%) had no specific cause of corneal perforation.

Cause of Corneal Perforation	Number of Patients
Trauma	13
PUK	4
Corneal Ulcer	10
No specific Cause	6

Location of Corneal Perforation

Of the 33 patients, 13 patients had central corneal perforation, 10 had Para central, 9 had peripheral and 1 had marginal corneal Perforation.

Size of Corneal Perforation

Of the 33 patients, 14(42%) patients had perforation size of ≤ 1 mm, 13(40%) patients had perforation size of ≤ 2 mm and 6(18%) had perforation size of ≤ 3 mm.

Pre Glue Seidel's Test

Before applying Isoamyl-2 Cyanoacrylate Glue, Seidel's test was Positive in 31(94%) of the patients and Seidel's Test was Negative in 2(6%) of the patients of which 1 had impending Corneal Perforation and 1 had Lamellar Corneal Tear

Post Glue Seidel's Test

After applying Isoamyl-2 Cyanoacrylate Glue, Seidel's test was Negative in 27(79%) patients and was Positive in 7(21%) patients, who needed subsequent tectonic procedure or Amniotic Membrane Grafting.

Pre Glue BCL Anterior Chamber Depth

Of the 33 patients, Pre Glue, Anterior Chamber was Flat in 12(36%) patients, Shallow in 19(58%) patients, 1 patient had impending corneal perforation and 1 patient had lamellar corneal tear, so anterior chamber was formed in these 2 patients.

Post Glue BCL Anterior Chamber Depth

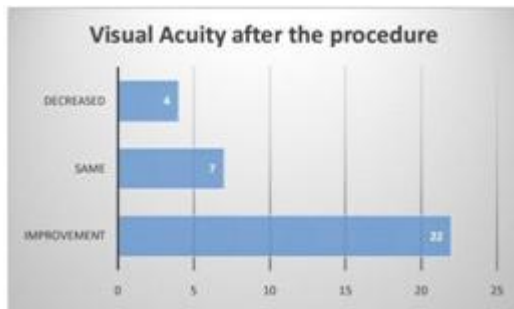
Of the 33 patients on whom Isoamyl-2 Cyanoacrylate Glue was performed, Anterior Chamber depth was formed in 22(67%) patients, Irregular in 4(12%) patients, Shallow in 6(18%) patients and Flat in 1(3%) patient.

Time of Removal of Glue

The mean duration for which the tissue adhesive remained in situ was 34 ± 22 days (range: 4– 95 days)

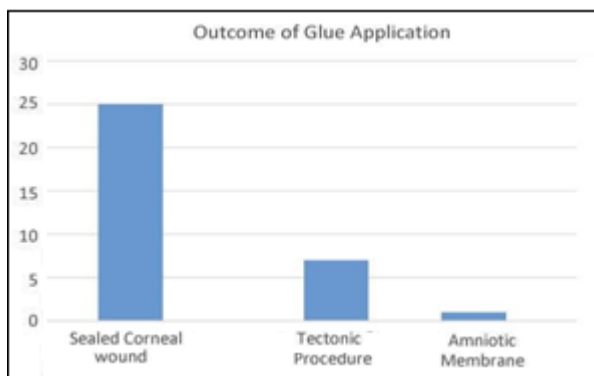
Visual Acuity after Removal of Glue

There was improvement of visual acuity after removal of Glue in 22(67%) patients, Visual acuity remained same in 7(21%) patients and there was decrease in visual acuity in 4(12%) patients. Of the 11 patients in whom improvement in visual acuity was not found, 4 patients visual acuity improved after tectonic procedure



Outcome of Procedure

- 1) Successful sealing of corneal wound was present in 25(76%) patients.
- 2) Urgent Tectonic procedure was done in 7(21%) patients due to post Glue Shallow/Flat anterior Chamber or Post glue positive Seidel's test. Amniotic Membrane Transplantation after Glue application was done in 1 (3%) patient.
- 3) No patient had to undergo Enucleation



Of the 7 eyes in whom tectonic procedure was performed, BCVA improved in 4 (57%) patients, remained same in 2 (29%) patients and decreased in 1 (14%) patient.

Complications

- 1) There was 1(3%) patient of extrusion of Bandage Contact lens after 4 days of its application.
- 2) There was 1(3%) patient in whom Glue was not visible after 15 days of its application, after which tectonic procedure was done in this patient due to shallow anterior chamber.
- 3) Multiple Glue application was done in 1(3%) patient of PUK.

5. Discussion

- 1) The use of tissue adhesives in ocular surgery was proposed in 1963. It was first reported in the management of corneal perforations by Refojo et al. and Webster et al. ⁽⁴¹⁾Use of cyanoacrylate tissue glues is the management for small or impending perforations. Cyanoacrylate demonstrates a glue quality and rate of polymerization that is ideal for the treatment of corneal perforations of up to 3-mm diameter. It is easily applicable, provides tectonic support, possesses antibacterial properties, and arrests the progression of keratolysis.
- 2) As the load of infective corneal ulcer patients in our Outpatient department is more, we have included infective corneal perforations in our study.

- 3) We applied tissue adhesive for the treatment of corneal perforations or impending corneal perforations that had history of trauma, corneal ulcer, Peripheral Ulcerative Keratitis or no specific history. Isoamyl-2 Cyanoacrylate glue showed its effectiveness for both frank corneal perforations and impending corneal perforations.
- 4) One of the hindrance in utilizing the tissue glue was the size of the perforation and the condition of the surrounding tissue. These elements influenced glue adherence. Of the 33 eyes, only 1 patient (3%) required repeat application of Glue. Previous reports have indicated that a tissue adhesive should be in place for 4 to 8 weeks to be effective. We found that the length of time of adherence and its impact differed from patient to patient.
- 5) For perforations of >3 mm size, Ashok Sharma et al showed utilisation of scleral patch graft augmented cyanoacrylate tissue adhesive.
- 6) We searched for vascularization and epithelialization under the glue for complete healing. Mean time period for removal of glue was 34±22 days. Weiss et al. demonstrated a clear trend towards increased complication rate (especially microbial keratitis) longer the glue remained in place. When we had to remove the tissue adhesive, the glue was easily removed with a McPherson Tying forceps. Other reported methods of removing tissue adhesive include applying 'acetone' or using the neodymium: YAG laser", methods that we have not found necessary.
- 7) We encountered few complications which were not serious. One patient presented with extrusion of glue for which a tectonic procedure was done. One patient presented with extrusion of Bandage Contact Lens after 4 days of its application which was followed by re-application of BCL without any further complications. Other reported complications of cyanoacrylates include giant papillary conjunctivitis, retinal toxicity, cataracts, and granulomatous keratitis.
- 8) Careful follow ups of the patients are necessary to avoid the disastrous complications of an infectious ulcer developing under the glue. However, the advantages of Isoamyl-2 cyanoacrylate outweigh the complications of the glue. Conditions which can be managed by CTAs are frank or impending corneal perforations, stromal melts, leaking filtering blebs, lamellar corneal tear and wound leaks. This cyanoacrylate glue may be a temporary measure until suitable donor tissue is available for a penetrating keratoplasty.
- 9) The advantage of this tissue adhesive in treating serious visual conditions is that it requires topical anesthesia and can be performed quickly at the slit lamp microscope while other tectonic procedures like lamellar patch graft requires a surgery with donor tissue for maintaining globe integrity. A patient with tissue glue set up can have an elective penetrating keratoplasty when suitable tissue is available.

6. Conclusion

- 1) Use of Tissue adhesives in ophthalmology have increased over the past several years. Our study is of 33 patients having perforation or impending corneal

- perforation managed with Cyanoacrylate tissue adhesive glue.
- 2) Various corneal pathologies where Cyanoacrylate tissue adhesive glue was useful were Trauma, Corneal Ulcers, Peripheral Ulcerative Keratitis No specific cause for perforation was there in 6 (18%) patients.
 - 3) Anterior chamber was formed in 22 (67%) patients, irregular in 4(12%) patients, shallow in 6(18%) patients and flat in 1(3%) patient.
 - 4) In 7 patients, whom anterior chamber depth remain shallow or flat, other surgical procedures were required for tectonic support.
 - 5) Seidel's test was negative in 25(75.7) patients.
 - 6) The complication rate after Cyanoacrylate tissue adhesive glue application was 9 % like extrusion of Glue, extrusion of Bandage Contact Lens or multiple glue applications.
 - 7) Tissue adhesive appears to be a very useful mode of therapy for corneal perforations and thinning with a small perforation by eliminating the need of tectonic surgical procedure.
- [10]Hyndiuk RA. Experimental pseudomonas keratitis. Transactions of the American Ophthalmological Society. 1981;79:540.
 - [11]Cavanagh HD. Herpetic ocular disease: therapy of persistent epithelial defects. International ophthalmology clinics. 1975;15(4):67-88.
 - [12]Foster CS, Duncan J. Penetrating keratoplasty for herpes simplex keratitis. American journal of ophthalmology. 1981;92(3):336-43.
 - [13]Forster R, editor The role of excisional keratoplasty in microbial keratitis. Cavanagh HD The cornea: transactions of the World Congress on the Cornea III New York; 1988.

References

- [1] Saini J, Sharma A, Grewal S. Chronic corneal perforations. Ophthalmic Surgery, Lasers and Imaging Retina. 1992;23(6):399-402.
- [2] Setlik DE, Seldomridge DL, Adelman RA, Semchyshyn TM, Afshari NA. The effectiveness of isobutyl cyanoacrylate tissue adhesive for the treatment of corneal perforations. American journal of ophthalmology. 2005;140(5):920-1.
- [3] Jhanji V, Young AL, Mehta JS, Sharma N, Agarwal T, Vajpayee RB. Management of corneal perforation. Survey of ophthalmology. 2011;56(6):522-38.
- [4] Hirst LW, Smiddy WE, Stark WJ. Corneal perforations: changing methods of treatment, 1960–1980. Ophthalmology. 1982;89(6):630-5.
- [5] Boruchoff SA, Donshik PC. Medical and surgical management of corneal thinnings and perforations. International ophthalmology clinics. 1975;15(4):111-23.
- [6] Portnoy SL, Insler MS, Kaufman HE. Surgical management of corneal ulceration and perforation. Survey of ophthalmology. 1989;34(1):47-58.
- [7] Panda A, Khokhar S, Rao V, Das GK, Sharma N. Therapeutic penetrating keratoplasty in nonhealing corneal ulcer. Ophthalmic Surgery, Lasers and Imaging Retina. 1995;26(4):325-9.
- [8] Sall K, Stevenson OD, Mundorf TK, Reis BL, Group CPS. Two multicenter, randomized studies of the efficacy and safety of cyclosporineophthalmic emulsion in moderate to severe dry eye disease I. Ophthalmology. 2000;107(4):631-9. Moorthy S, Jhanji V, Constantinou M, Beltz J, Graue-Hernandez EO, Vajpayee RB. Clinical experience with N-butyl cyanoacrylate tissue adhesive in corneal perforations secondary to herpetic keratitis. Cornea. 2010;29(9):971-5.
- [9] Arentsen JJ, Laibson PR, Cohen EJ. Management of corneal descemetocoeles and perforations. Ophthalmic Surgery, Lasers and Imaging Retina. 1985;16(1):29-33.