

Role of Magnetic Resonance Imaging in the Differentiation between Benign and Malignant Adnexal Masses

Nahla L. Faizo¹, Rania Mohammed Ahmed², Alanood Althobaiti³, Arwa Altowairqi⁴, Wejdan Alqurashi⁵, Taef Ahmed⁶, Rawan Alsufyani⁷, Shahad Alshibani⁸, Wejdan Althobaiti⁹

¹Radiological Sciences Department, College of Applied Medical Sciences, Taif University, Saudi Arabia (Corresponding Author)

^{2,3,4,5,6,7,8,9}Radiological Sciences Department, College of Applied Medical Sciences, Taif University, Saudi Arabia

Abstract: ***Introduction:** Adnexal masses are common among women and are classified into benign and malignant lesions. This study aimed to evaluate the role of MRI in the characterization of adnexal masses in comparison to US. The objectives of this project were to assess the age group mostly affected by adnexal masses among women at Taif city; to emphasize the most common type of lesion among those patients; and to compare the level of agreement between MRI and US in the differentiation of different adnexal masses. **Materials and Methods:** This study was conducted at different Taif hospitals and was performed retrospectively on 73 female patients. The cases were divided into seven age groups, start from under 20 years up to more than 70 years old with 10 years interval. Subjects were chosen as suspected cases of adnexal mass whom underwent US followed by MRI. Also, lab test CA-125 was taken in consideration as indicator for malignancy. **Result:** The most affected age group was between 41-50 years with percentage of 32%. Below this age group and above it, percentage of patients diagnosed with adnexal mass gradually decrease. Cyst was the most detected adnexal lesion with percentage of 52%. There was a high level of agreement between MRI and US in the differentiation between adnexal masses. **Conclusion:** MRI is more accurate in differentiating cancerous lesions than US. Both imaging modalities equally achieved 82% in detecting cysts but MRI has higher sensitivity (100%) and specificity (94%) in diagnosing malignant adnexal lesions.*

Keywords: Adnexal masses, Benign, Malignant, MRI, US, CA-125

1. Introduction

Adnexal masses are common female pelvic diseases (1). Adnexa refers to the region within the pelvic that is made up of the fallopian tube, ovary, structures that develop from the related embryologic remnants as well as the round ligament. The adnexa has no specific location and it may be found in different structures or around the uterus (2)(3). Medical imaging plays significant role to diagnose adnexal mass and provide differential diagnosis whether it is benign or malignant. However, there are factors besides medical imaging should be taken in account when assessing the probability of malignancy for an adnexal mass and those include age, menopause status, history of breast or ovarian cancer, and serum test (CA-125). Also, it is important to properly classify adnexal masses to evaluate which type requires surgery (4). Adnexal mass could be fluid filled structure or solid. Also, there are several types of benign adnexal masses such as cysts, ectopic pregnancies and fibroids, whereas malignant adnexal masses includes ovarian and uterine carcinomas (3)(2).

The diagnosis of adnexal masses can be challenging due to wide variety of etiologies (3). Accurate and early diagnosis of the adnexal masses is most crucial step toward setting treatment plan. In recent times, imaging has gained prevalence in detecting adnexal masses and also in evaluating their origin as well as characterizing the nature of the adnexal masses. Moreover, imaging also plays a critical role in differentiating between malignant and benign. There are several imaging modalities and tools that are used to diagnose adnexa masses. Nonetheless, Ultrasound (US) and

magnetic resonance imaging (MRI) are the most prevalently used.

US is the primarily imaging modality for adnexal masses investigation due to several reasons such as low cost, real time, lack of ionizing radiation, could be performed portability and has high spatial and temporal resolution. US has the advantage of characterizing an adnexal mass, which indicates the possible etiology of the mass. Also, US provides suggestive characteristics of malignancy in an adnexal mass include a solid component, thick septations, bilateralness and blood flow to the solid component of the mass (5)(6)(7).

MRI is a second-line imaging technique to evaluate adnexal masses that remain indeterminate on US (8). The main advantages of MRI are the great soft tissue contrast that indicate the nature of lesions wither benign or malignant (9). MRI diagnoses malignancy with sensitivity 100% and specificity 94% and therefore, it can be helpful to reduce the number of women undergoing unnecessary surgery (8)(10). MRI has a maximal diagnostic value comparing to US or other imaging modalities regarding indeterminate adnexal mass especially when CA-125 levels are normal or only slightly raised (11). CA-125 (Carbohydrate antigen, that is a type of cell surface glycoprotein) is a tumor marker for predicting the risk of malignancy and it is useful for diagnosis and follow up of treatment in patients with gynecological malignancies (12)(13)(14). Level of CA-125 is raised in 80% of epithelial ovarian cancer but the efficacy is comparatively low in first stage of malignancy. The serum concentration of CA-125 rises above 35 IU/ml on tumor but it could be elevated in some physiologic cases and benign

conditions such as menstruation and endometriosis. The essential point in the interpretation of results is the magnitude of the elevation. It is reported when levels of CA-125 is >200 IU/ml, it is potentially associated with ovarian malignancies. In differentiating benign or malignant disease, this indicator has sensitivity of 61%–90% and specificity of 71%–93%. Value of Ca-125 to predict cancer risk in postmenopausal women is greater as compared to in premenopausal women (14)(15).

It is really not clear which is the best imaging modality providing accurate method to diagnose adnexal masses. Thus, the main aim of our study to evaluate the role of MRI in the characterization of adnexal masses. The objectives of this project include: assess the age group mostly affected by adnexal masses among women at Taif city, to emphasize the role of MRI in the differentiation of adnexal masses, to compare the accuracy of MRI and US in the differentiation of adnexal masses and emphasize the role of CA-125 as a helps to differentiate benign from malignant. Outcomes from this study, increase awareness in women about adnexal masses, and improve the diagnosis and management of cases with adnexal mass.

2. Materials and Methods

This is a retrospective study that has been conducted at several Taif hospitals including King Abdul Aziz Specialist Hospital, King Faisal Medical Complex and Alhada Armed Forces hospital (Ethics) from January to February 2020. The study included data from female patients who were

suspected for adnexal masses and underwent MRI, US and were referred to laboratory testing for CA-125 to confirm the diagnosis. From 173 patients, we included only 73 cases who filled the criteria mentioned previously with different marital status, aged less than 20 up to more than 70 years. Seven age groups were chosen as (<20, 21-30, 31-40, 41-50, 51-60, 61-70, >70) based on survey of women with adnexal mass was performed in Istanbul (Turkey)(1). Patients were chosen as suspected cases of adnexal masses based on US finding and then were referred to MRI pelvis. US data was obtained from the patient's medical reports, MRI data were collected from Picture Archiving and Communication System (PACS) program, and CA-125 were obtained from laboratories report. A table was created with the following information: demographic information, (serial number of patient, age), the presence of adnexal mass on MRI and US, type, and laboratory result of CA-125 Antigen, agreement of MRI with US. Adnexal lesions were found in MRI and US were classified as benign (including cyst, fibroid, ectopic pregnancy, polyp) and malignant (including ovarian cancer, uterine cancer). This classification was based on the similarity of pathological finding as shown in (table 1, figure 1) and confirmed by previous literature. Data were revised, coded, entered, tabulated and analyzed using statistical for Microsoft Excel. Data collection and reporting of finding were undertaken in manner designed to protect confidentiality of subjects. Ethics approval was obtained from the Institutional Review Board (IRB) of the Armed forces hospitals and Ministry of health hospitals at Taif region.

Table1: MRI and US features of different adnexal masses

Type of lesion	Appearance of lesion on MRI	Appearance of lesion on US
Cyst	Clear fluid, thin regular wall(16). T2: Fluid appears as hyperintense signal. T1: Fluid appears as hypointense signal.	Smooth wall anechoic area with posterior acoustic enhancement(17).
Fibroid	Fibroids appear as well-defined, solid masses. These are usually of similar echogenicity to the myometrium, but sometimes may be hypoechoic(18).	Well defines hypoechoic solid mass(18).
Ectopic Pregnancy	Appear as cystic saclike structure, "ring of fire" sign intensity(19). T2: Low signal intensity and intermediate T1: High signal intensity with ascites is consistent.	Transvaginal intracavitary fluid or blood within the endometrial cavity, surrounded by an echogenic ring of trophoblastic(20)
Polyp	T1: Isointense signal to endometrium. T2: Hypointense intracavitary masses surrounded by hyperintense fluid and endometrium(21)	Echogenic, smooth, intracavitary masses outlined by the fluid(21)
Ovarian cancer	Solid, cystic mass with the margin being generally smooth. Thick septa in cystic lesion. Necrosis in solid lesion, ascites(22).	Ascites, mural nodule, thick and irregular walled cyst, with thick septae(22).
Uterine Cancer	T1: Hypo- to isointense to normal endometrium. T2: Hyperintense or heterogeneous relative to normal endometrium(23).	Heterogeneous and irregular endometrial thickening with intrauterine fluid collection(23).

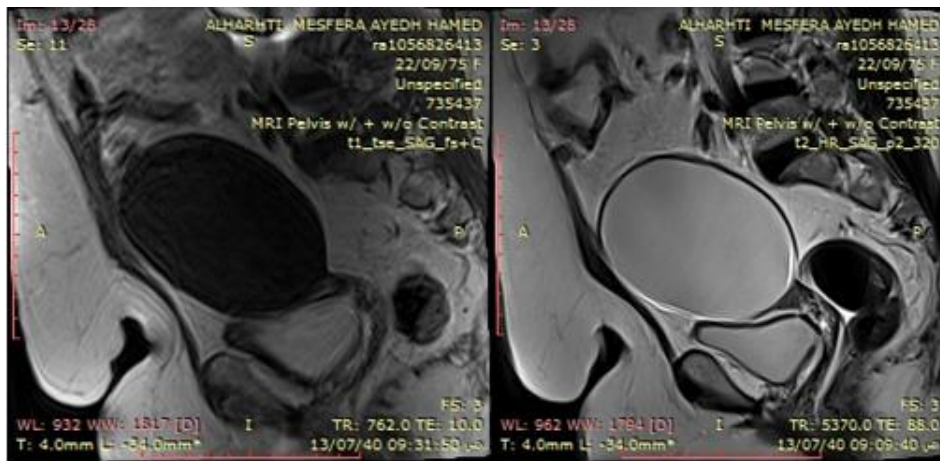


Figure 1: Right ovarian cyst. Sagittal T1W image and Sagittal T2W image lesion was seen in the right ovary as clear fluid, thin regular wall. The cyst measurement is (10.1 * 9.2 * 9.8 cm).

3. Results

First, we assessed the most age groups affected by adnexal masses among women at Taif city. The data collection from 73 female patients show the most common age that affected

percentage at 32% between (41-50) then, 29% between (31-40), 14% (51-60), 12% (21-30), 7% (<20), 5% (61-70), 1% (>70) as shown in figure 2.

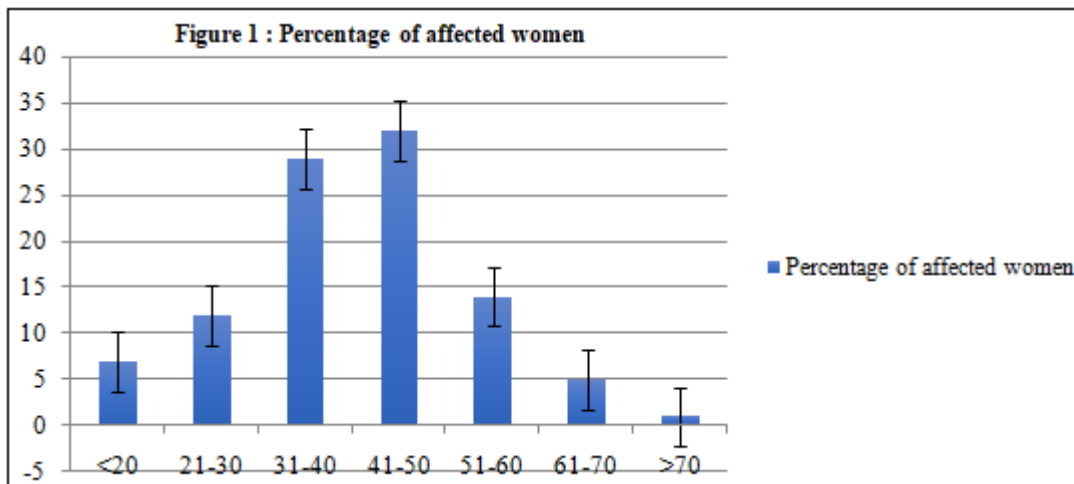


Figure 2: The different age groups of women affected by adnexal masses in Taif city. The most age affected is between 41-50 years.

Then, we have assessed the different pathological findings appeared on MR and US images. Cysts were the most common lesions found in 52% the pelvis of adnexal patients, followed by fibroids, which were detected with in 35.6% of cases and uterine cancer in 16.4% of patients as shown in

figure 2. Less common lesions were detected in 4.1% of cases such as ectopic pregnancy and polyp. The least type adnexal mass was detected in this study was ovarian cancer with a percentage of 2.7% (figure 3).

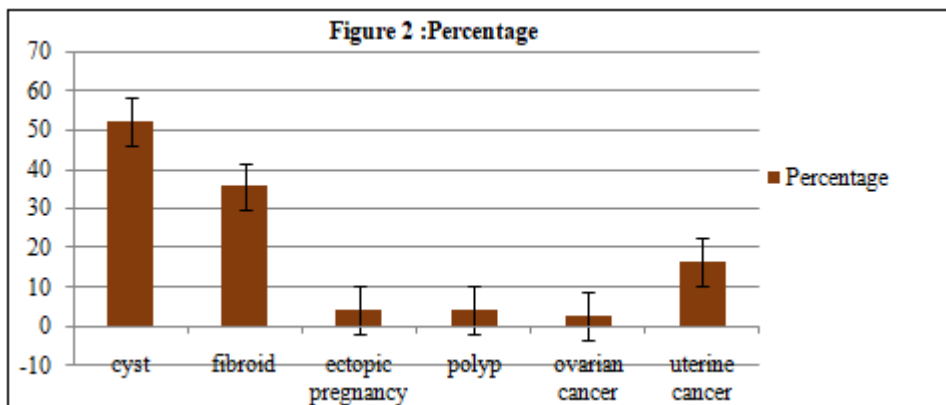


Figure 3: The types of lesion presented in MR Images and US of adnexal patients

This figure shows that the cyst lesion is the most common among the rest of lesions in the MR images and US of adnexal patients.

Furthermore, we have examined the percentage of agreement between MRI and US in differentiating between different pathological lesions. Our results showed that MRI and US have an agreement in 82% of cystic lesions, followed by fibroid 77%, uterine cancer 58%, ectopic pregnancy 50%, polyp 33.33% and ovarian cancer 0% as shown in table 2.

Table 2: Agreement percentage between MRI and US

Cyst	82%
Fibroid	77%
Ectopic Pregnancy	50%
Polyp	33.33%
Ovarian cancer	0 %
Uterine Cancer	58%

Following that, we have assessed the percentage of cases that have shown false negative results for malignancy on US, and then proven to be malignant by MRI and CA-125. Off the 60 benign adnexal masses, which were diagnosed as benign on US, 3 cases (5 %) were found to be malignant on MRI and proven by high serum CA-125. Also, all cases (100%), which were found to be benign on MRI, were also diagnosed as benign on US.

4. Discussion

As introduced earlier, the aim of this study was to evaluate the role of MRI in the characterization of adnexal masses. We also examined the age group mostly affected by adnexal masses in females at Taif city. In addition, we emphasized the role of MRI in the differentiation of adnexal masses by correlating the results to US findings and levels of CA-125.

We found that adnexal masses affected mostly the age group between 41 – 50 years and 31-40 years as the was no significant differences between these two groups. The least affected group is above 70 years. Apparently, the trend of findings is telling that the percentage of having adnexal mass gradually decrease in age groups below 31 years and above 50 years. This finding leads us to conclude that during reproductive period over 31 years and premenopausal period, which as up to 50 years, the number of patients with adnexal masses is relatively high whereas on ages above 50 years and below 31 years, the chance of getting adnexal mass is low. In addition, it is known that hormonal disturbance in women roughly occurs at the age between 41 to 50 years(24). The relationship between the period of hormonal disturbance and the high rate of developing adnexal mass could be drawn. Rate of developing adnexal mass is low during reproductive period and after this period (post-menopausal). At the transition period, which is between 41 to 50 years, where hormonal disturbance occurs, the rate of developing adnexal mass is the most. Confirming this theory, we also observed that the rate of developing adnexal mass increased with age 31 to 40 years, which is age group where women may develop early menopause.

These finding were similar to results from previous study conducted in Turkey, however, a previous study of women with adnexal mass was performed in Istanbul (Turkey) it is the one between 31 to 40 years only. In fact the difference is not significant because the age group 31-40 years is the second affected group. We should always put in mind that transition period between menopausal and post menopausal is not the same in all regions, so we could assume that transition period where hormones face disturbance in Turkey may occur earlier. Therefore, our results are the same if we consider the geographic aspect for the subjects.(1)

When we examined the agreement level between MRI and US in diagnosing and differentiating adnexal masses, it was observed that MRI and US agreed in diagnosing cyst by 82% and it is the highest percentage of agreement while it is was 0% in ovarian cancer differential diagnosis and it is the lowest agreement value. Also, 5% of cases that were diagnosed as benign adnexal lesions on US were proved to be malignant on MRI. That gives impression of superiority of MRI over US in cancer differential diagnosis especially in ovarian malignancies. But when the issue is uterine cancer, the agreement is 58% and this is good value of agreement but still not the confident goal for the clinicians. On the other hand, 50% is the agreement between MRI and US in diagnosing ectopic pregnancy while the percentage of agreement is only 33% for the polyp.

Accuracy of imaging modalities (MRI and US) is a challenge in this study because the sample is relatively small. Also, a major limitation of our study is inability to retrieve some laboratory investigations for the CA-125.

5. Conclusion

Findings from this study proof the role of MRI in diagnosing and differentiating adnexal mass accurately. The most vulnerable age to develop adnexal mass was between 31-50 years old. MRI has superiority in diagnosing adnexal mass but still US remain the first line of investigation. Future studies are required to have larger samples and complete data to assess the sensitivity and specificity of MRI more accurately. It is very optimistic description for encountered pathology, because it tells us that most detected adnexal masses are benign. That gives hope for women toward full recovery in shortest possible period. Treatment of benign lesion is not as complicated as malignant.

Acknowledgments and Dedication

We are grateful to all of our colleagues and radiographers at the Radiology Departments at Taif hospitals (King Faisal medical complex, King Abdul Aziz Specialist hospital and Alhada Armed Forces hospital) who assisted us and provided us with all the information we needed during the study period. Without their cooperation, we would not have been able to conduct the study.

References

- [1] Aydin DS, Turkeyilmaz E, Goksedef BP, Aydin S, Aslan O, Ateser G, et al. 1,138 women with adnexal mass: pathologic findings according to age. Eur J

- Gynaecol Oncol. 2017;38(1):102–5.
- [2] Debra Rose Wilson BY. adnexal mass. healthline. 2018;
- [3] Dalia1 DY, Agrawal2 DM, Dr. Anju Sharma3. A Case Series on Bilateral Adnexal Masses. IOSR Journa. 2017;
- [4] Brown DL, Dudiak KM, Laing FC. Adnexal masses: US characterization and reporting. Radiology. 2010;254(2):342–54.
- [5] Theodoridis TD, Zepiridis L, Mikos T, Grimbizis GF, Dinas K, Athanasiadis A, et al. Comparison of diagnostic accuracy of transvaginal ultrasound with laparoscopy in the management of patients with adnexal masses. Arch Gynecol Obstet. 2009;280(5):767–73.
- [6] Givens V, Mitchell G, Harraway-Smith C, Reddy A, Maness DL. Diagnosis and management of adnexal masses. Am Fam Physician. 2009;80(8):815–20.
- [7] Salem FM, Alarabawy RA, El-Ebiary MT, Edorf AA, Abozeid SM. Imaging modalities in the differentiation of various adnexal lesions. Tanta Med J. 2016;44(2):39.
- [8] Spencer JA, Ghattamaneni S. MR imaging of the sonographically indeterminate adnexal mass. Radiology. 2010;256(3):677–94.
- [9] Thomassin-Naggara I, Balvay D, Rockall A, Carette MF, Ballester M, Darai E, et al. Added Value of Assessing Adnexal Masses with Advanced MRI Techniques. Dong Z, editor. Biomed Res Int [Internet]. 2015;2015:785206. Available from: <https://doi.org/10.1155/2015/785206>
- [10] Kerimova Z, Soysal S. Diagnostic Value of Magnetic Resonance Imaging in Prediction of Malignancy in Adnexal Masses. East J Med. 2019;24(1):102–7.
- [11] Khodaverdi S, Amini-Moghaddam S, Nokiani FA, Hashemi N, Beigi RM. Adnexal mass with extremely high levels of CA-125 and CA19-9 but normal Human Epididymis Protein 4 (HE4) and Risk of Ovarian Malignancy Algorithm (ROMA): Endometriosis or ovarian malignancy? A case report. Int J Reprod Biomed. 2018;16(6):413.
- [12] Drake J. Diagnosis and management of the adnexal mass. Am Fam Physician. 1998;57(10):2471.
- [13] Champawat C, Wani RJ. Management of adnexal masses: save the ovaries. Int J Reprod Contraception, Obstet Gynecol. 6(12):5541.
- [14] Khoiwal K, Bahadur A, Kumari R, Bhattacharya N, Rao S, Chaturvedi J. Assessment of diagnostic value of Serum Ca-125 and risk of malignancy index scoring in the evaluation of adnexal masses. J Midlife Health. 2019;10(4):192.
- [15] Khodaverdi S, Amini-Moghaddam S, Nokiani FA, Hashemi N, Beigi RM. Adnexal mass with extremely high levels of CA-125 and CA19-9 but normal Human Epididymis Protein 4 (HE4) and Risk of Ovarian Malignancy Algorithm (ROMA): Endometriosis or ovarian malignancy? A case report. Int J Reprod Biomed. 2018;16(6):413–6.
- [16] Foti PV, Attinà G, Spadola S, Caltabiano R, Farina R, Palmucci S, et al. MR imaging of ovarian masses: classification and differential diagnosis. Insights Imaging. 2016;7(1):21–41.
- [17] Al. DFD and DMR et. Ovarian cyst. radiopedia.
- [18] Sue W, Sarah S-B. Radiological appearances of uterine fibroids. Indian J Radiol Imaging. 2009;19(3):222.
- [19] Saloum N, Gujrathi A, Badr S, Qureshi S, Ahmed W. Pregnancy at unusual sites, pictorial review. In European Congress of Radiology 2019; 2019.
- [20] Winder S, Reid S, Condous G. Ultrasound diagnosis of ectopic pregnancy. Australas J ultrasound Med. 2011;14(2):29–33.
- [21] Dr Owen Kang and Radswiki et al. Endometrial polyp. Radiopaedia.
- [22] Dr Yuranga Weerakkody DPM et al. Malignant ovarian lesions (sonographic features). radiopedia. 2018;
- [23] Al DME-F and DYW et. Endometrial carcinoma. radiopedia.
- [24] Santoro N. Perimenopause: From Research to Practice. Journal of women's health. 2016;25(4):332-9.